

Radiology

Clinical Referral Guidelines

SECOND EDITION



Hong Kong College of Radiologists

Radiology

Clinical Referral Guidelines

SECOND EDITION

Hong Kong College of Radiologists

Room 909, 9/F

Hong Kong Academy of Medicine Jockey Club Building

99 Wong Chuk Hang Road, Aberdeen, Hong Kong

Tel: (852) 2871 8788 Fax: (852) 2554 0739 E-mail: enquiries@hkcr.org Website: <https://www.hkcr.org>

First Edition © 1999 by Hospital Authority, Hong Kong & Hong Kong College of Radiologists.

Second Edition © 2017 by Hong Kong College of Radiologists.

FOREWORD

Pioneered by Hong Kong College of Radiologists, the first edition of the Clinical Referral Guidelines published in 1999 came into the hands of radiologists and clinicians in Hong Kong at a time when knowledge and technology in Radiology started to grow rapidly. From the outset, the guidelines was developed with a clear objective to provide a useful reference for how to choose the most optimal radiological tools for the effective delivery of comprehensive and quality patient care and for a better understanding of the roles and limitations of Radiology in specific clinical scenarios.

The past two decades since the emergence of the guidelines has witnessed the continuous and exponential development of Radiology. Today, Radiology is involved in almost every aspect of patient care and has assumed global dimensions in modern medical practices. Not only is Radiology indispensable in making decision, solving clinical dilemmas and monitoring of disease progress, it has also developed as an integral facet on the therapeutic side of disease management and preventive approach in healthcare delivery. To keep abreast of the advancement of medical knowledge and rising standard of patient care, Hong Kong College of Radiologists has revised the Clinical Referral Guidelines. This new version of the guidelines with clinical topics and scenarios carefully selected aims at providing updated information pertinent to Radiology in the face of ever-increasing complexity and specialization in various fields of medical science. This daunting task has been accomplished by devoted efforts of the Radiologists of Hong Kong through literature appraisal, peer review and referencing on published guidelines and expert opinions. I am confident that their efforts have been translated into a piece of work which will be proven highly useful for better care of our patients. With this well-structured seminal reference, I believe Hong Kong College of Radiologists has continued to provide the medical community the foundation for the understanding on the current role of Radiology in the diagnosis and treatment of diseases.



Dr. Lilian Leong
Founding President & Immediate Past President
Hong Kong College of Radiologists
December 2017

FOREWORD

Radiology is one of the fastest developing medical specialties. With rapid innovation in technology and expansion in medical knowledge, radiology has taken an important role in the clinical management of diseases and even more so in the screening of healthy subjects. Appropriate utilization of radiological investigation brings along tremendous advantages to the quality, safety and efficiency of clinical practice. On the other hand, over-investigation especially with imaging modalities that incur ionizing radiation is not only wasteful of health care resources but also hazardous to population health. In the midst of increasing complexity and specialization in various fields of medicine, an evidence based guideline would be invaluable for medical practitioners to employ appropriate imaging investigations in different clinical contexts.

Our College first published Clinical Referral Guidelines in 1999 to promote cost-effective, efficient and evidence based medicine, in keeping with our College objectives to develop and maintain the good practice of radiology. Witnessing the swift development of medicine and advancement of radiological investigations in the past two decades, update of the Clinical Referral Guidelines would be obligatory to upkeep these objectives. The revision of the Guidelines was accomplished through intensive effort and collaboration of a group of dedicated Fellows from the three specialties of the College, namely Radiology, Clinical Oncology and Nuclear Medicine, over the past few years. I hope the updated version of Clinical Referral Guidelines would encourage vigilance and conscientiousness in the use of radiological investigations, and eventually improve the quality of health care in Hong Kong.



Dr. CK Law
President

Hong Kong College of Radiologists

December 2017

DISCLAIMER

Hong Kong College of Radiologists has developed this set of systematic evidence-based guidelines with the intention to enhance clinical decision making in the appropriate utilization of radiology diagnostic and interventional procedures, and to improve the outcome and standard of patient care. Hong Kong College of Radiologists has made every attempt to provide the most accurate and up-to-date recommendations in strict accordance with the state of knowledge at the time of publication.

The application of radiology diagnostic and interventional procedures occurs in a wide diversity of practice settings with differing accessible resources and variable clinical context of the individual patient. It should be noted that these guidelines do not replace or obviate the need to take into account the availability of radiology equipment and expertise, and the circumstances presented by the individual patient.

Hong Kong College of Radiologists makes no representations or warranties of any kind, express or implied, as to the accuracy or completeness of the information contained in these guidelines and disclaims all liabilities in respect thereof. Hong Kong College of Radiologists does not assume any responsibility for the acts of any clinicians or any other individuals who receive information acquired in these guidelines. Hong Kong College of Radiologists will assume no legal responsibility for any injury or damage to persons or property or any loss or damages arising from the use of any of the guidelines presented herein. The guidelines are being presented for informational purposes only and are not intended for third-party reimbursement or fiscal consideration.

How to use this book

These evidence-based guidelines are developed to assist clinical decision making in the appropriate utilization of radiology diagnostic and interventional procedures, and to enhance the standard of patient care. Since the first edition there have been further advances in various radiology diagnostic and interventional procedures and this has been reflected in the guidelines.

This latest version of the guidelines has evolved from the first edition and includes a total of 64 chapters arranged in 11 organ systems. These chapters have been judiciously edited and integrated into a unifying structure with most chapters composing of an algorithm followed by remarks and a list of references. The algorithm and remarks are complementary to each other and should not be used separately. With the exception of the paediatric guidelines, the guidelines in all other chapters apply to adult cases only.

The recommendations in the guidelines are best utilized if used while taken into consideration the specified clinical context of each individual patient and the availability of accessible resources. These guidelines should not be deemed inclusive of all proper methods of utilization of radiology diagnostic and interventional procedures or exclusive of other methods of application of radiology procedures that are reasonably directed towards similar standard of patient care. These guidelines are not intended to replace the consultation with the radiologist or nuclear medicine physician. Majority of these guidelines provide recommendations in the stage of diagnosis and readers should refer to other guidelines for further treatment of patients.

These guidelines were prepared with the most current information available to the Hong Kong College of Radiologists at the time of publication. It is the responsibility of the user to evaluate and determine the suitability of the information described herein based on their own assessment of the most current information available at the time of application of these guidelines.

List for Abbreviations

In-111	Indium-111
C-11	Carbon-11
I-123	Iodine-123
F-18	Fluorine 18
3D	Three-dimensional
Ga-67	Gallium-67
AAA	Abdominal aortic aneurysm
AAP	American Academy of Pediatrics
AASLD	American Association for the Study of Liver Disease
AAST	American Association for the Surgery of Trauma
ABI	Ankle brachial index
ACR	American College of Radiology
ACS	Acute coronary syndrome
Anti-TPO	Anti-thyroid peroxidase
AP	Anterior-posterior
APASL	Asian Pacific Association for the Study of the Liver
AUS	atypia of undetermined significance
AVM	Arteriovenous malformation
AXR	abdominal x-ray
BAE	Bronchial artery embolization
BECTS	Benign epilepsy with centrotemporal spikes
bhCG	Beta-human chorionic gonadotropin
BIRADS	Breast Imaging Reporting and Data System
C-spine	cervical spine
CA	Cancer
CABG	Coronary artery bypass graft
CAD	Coronary artery disease
CAE	Childhood absence epilepsy
ceVUS	Contrast-enhanced voiding urosonography
chemoRT	Chemoirradiation
CMR	Cardiac magnetic resonance imaging
COPD	Chronic obstructive pulmonary disease
CT	Computed tomography
CTA	Computed tomography angiogram
CTCA	Computed tomography coronary angiography
CTPA	Computed tomography pulmonary angiogram
CTU	computed tomography urogram
CTV	Computed tomography venography
CXR	chest X-ray
DMSA	Dimercaptosuccinic acid
DRC	Direct radionuclide cystography
DRE	digital rectal examination
DSA	Digital subtraction angiogram
DTPA	Diethylene triamine penta-acetic acid
DVT	Deep vein thrombosis
EASL	European Association for the Study of Liver
ECD	Ethyl cysteinate dimer
ECG	Electrocardiogram
EEG	Electroencephalography or electroencephalogram
ERCP	endoscopic retrograde cholangiopancreatography
EVAR	Endovascular aortic repair
FAST	Focused assessment with sonography for trauma
FDG	Fluorodeoxyglucose
FLAIR	Fluid attenuated inversion recovery
FLUS	Follicular lesion of undetermined significance
FNA	Fine needle aspiration
GCS	Glasgow coma scale
GER	Gastroesophageal reflux
GERD	Gastroesophageal reflux disease
GFR	Glomerular filtration rate
GI	Gastrointestinal
HCC	hepatocellular carcinoma
hCG	Human chorionic gonadotropin
HIV	Human immunodeficiency virus
HMPAO	Hexamethylpropyleneamine oxime
HRCT	High resolution CT

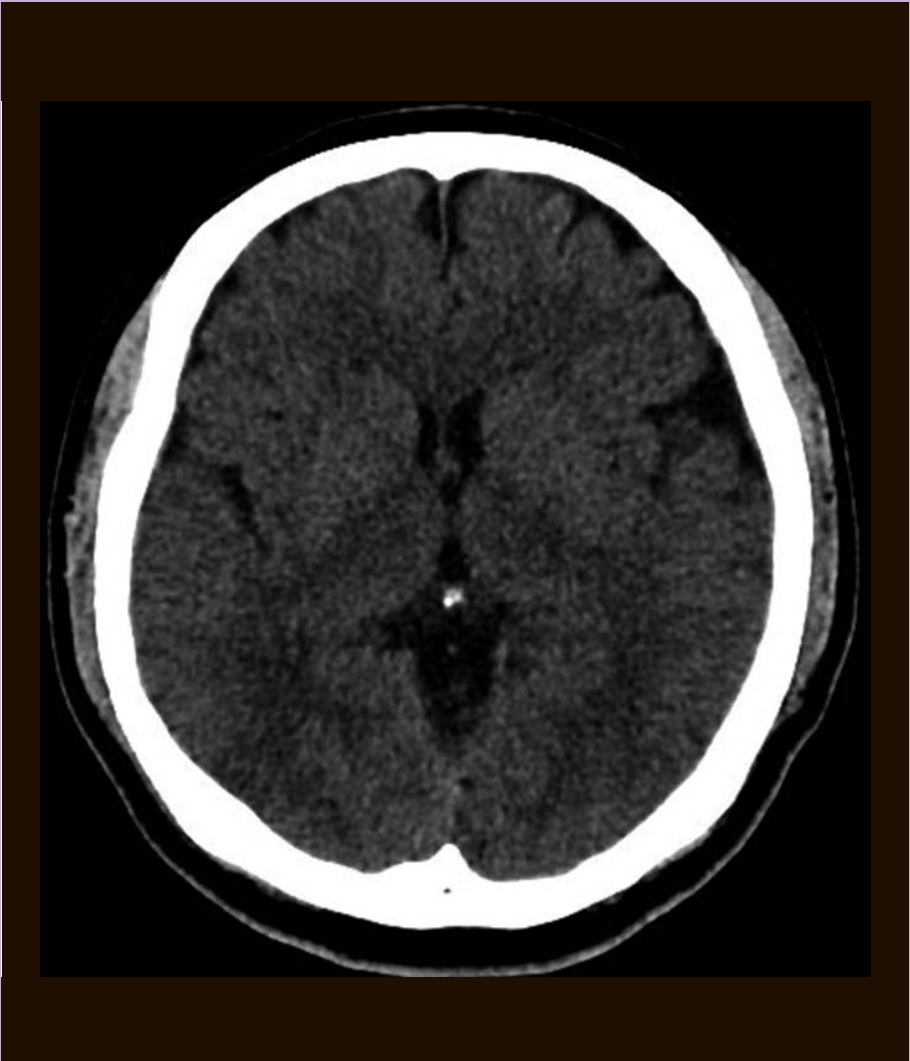
IDA	Iminodiacetic acid
IO	Intestinal Obstruction
IV	Intravenous
IVC	Inferior vena cava
IVU	intravenous urogram
JAE	Juvenile absence epilepsy
JME	Juvenile myoclonic epilepsy
JSH	Japanese Society of Hepatology
KUB	kidney, ureter and bladder radiograph
LGIB	Lower gastrointestinal bleeding
LN	lymph node
LUTS	lower urinary tract symptoms
MAG3	Mercaptoacetyltriglycine
MCU	Micturating cystourethrography
MDCT	Multidetector CT
MDP	methylene diphosphonate
MIBG	Metaiodobenzylguanidine
MIP	maximum intensity projection
MMG	mammography
mpMRI	multiparametric MRI
MRA	Magnetic resonance angiogram or angiography
MRCP	magnetic resonance cholangiopancreatography
MRI	Magnetic Resonance Imaging
MRS	Magnetic resonance spectroscopy
MRU	magnetic resonance urogram
MRV	Magnetic resonance venography
MSCC	metastatic spinal cord compression
NAI	Non-accidental injury
NCCT	non-contrast computed tomography
NEXUS	National emergency X-radiography utilization study
NICE	National Institute for Health and Care Excellence
NSTEMI	Non-ST-segment-elevation myocardial infarction
PA	Posterior-anterior
PCI	Percutaneous coronary intervention
PE	Pulmonary embolism
PERC	Pulmonary Embolism Rule-Out Criteria
PET	Positron emission tomography
PID	Pelvic inflammatory disease
PIOPED	Prospective Investigation of Pulmonary Embolism Diagnosis
PSA	prostate specific antigen
PSMA	prostate specific membrane antigen
PTC	percutaneous transhepatic cholangiogram
RAI	Radioactive iodine
RBC	Red blood cell
RNC	Radionuclide cystography
RNSI	radionuclide scrotal imaging
SBRT	Stereotactic body radiation therapy
SPECT	Single photon emission computed tomography
STEMI	ST-segment-elevation myocardial infarction
STIR	short T1 inversion recovery
SXR	skull x-ray
TB	tuberculosis
TBI	Toe brachial index
Tc-99m	Technetium-99m
TOE	Transoesophageal echocardiogram
TRUS	transrectal US
TSH	thyroid stimulating hormone
TSI	Thyroid stimulating immunoglobulin
TTE	Transthoracic echocardiogram
TVUS	Transvaginal ultrasound
UGIB	Upper gastrointestinal bleeding
US	Ultrasound
UTI	Urinary tract infection
V/Q scan	Ventilation/Perfusion scintigraphy
VFSS	Video-fluoroscopic swallowing study
VUR	Vesicoureteric reflux
WBC	White blood cell

CONTENTS

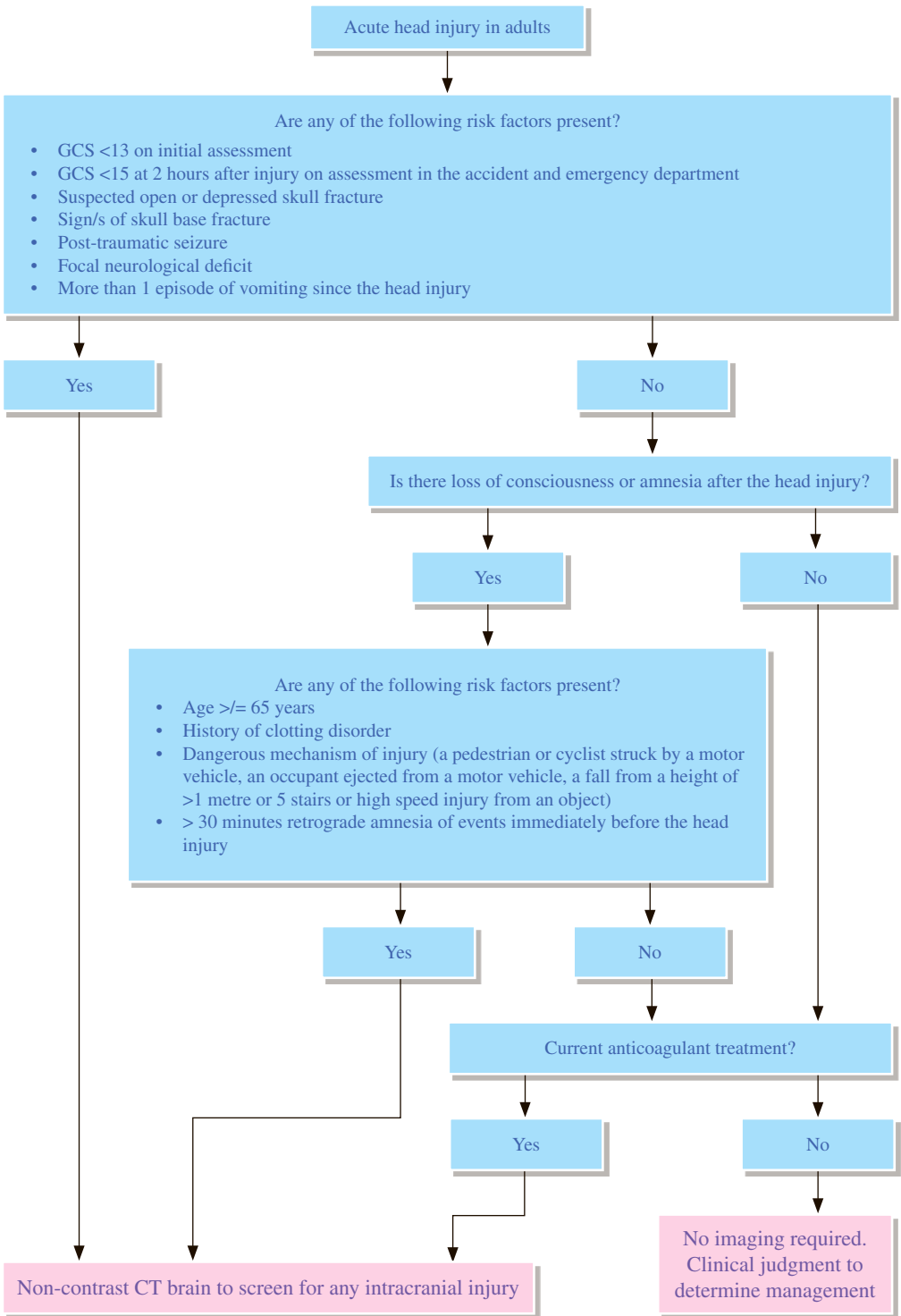
Neuroradiology Guidelines	1
NR 1 Acute head injury	2
NR 2 Blunt cervical spine trauma	6
NR 3 Thoracolumbar spine trauma	10
NR 4 Acute non-traumatic spinal cord compression	12
NR 5 Acute seizure in adult	14
NR 6 Acute headache	16
NR 7 Neck pain	20
NR 8 Low back pain	22
Thyroid Imaging Guidelines	27
TI 1 Thyrotoxicosis	28
TI 2 Euthyroid nodule	32
Chest Radiology Guidelines	37
CH 1 Blunt chest trauma with suspected pulmonary injury	38
CH 2 Dyspnoea	40
CH 3 Acute chest pain with suspected pneumothorax	42
CH 4 Haemoptysis	44
CH 5 Solitary pulmonary nodule	46
CH 6 Mediastinal mass	50
CH 7 Lung cancer	52
Cardiovascular Radiology Guidelines	57
CV 1 Blunt chest trauma with suspected thoracic cardiovascular injury	58
CV 2 Acute aortic dissection	62
CV 3 Abdominal aortic aneurysm	66
CV 4 Intermittent claudication	70
CV 5 Acute pulmonary embolism	74
CV 6 Deep vein thrombosis	78
CV 7 Chest Pain	82
Gastrointestinal Radiology Guidelines	87
GI 1 Blunt abdominal trauma in adult	88
GI 2 Blunt pelvic trauma	90
GI 3 Suspected pneumoperitoneum	92
GI 4 Dysphagia	94
GI 5 Acute gastrointestinal bleeding	96
GI 6 Chronic recurrent gastrointestinal bleeding	98
GI 7 Small bowel obstruction	100
GI 8 Large bowel obstruction	102
GI 9 Palpable abdominal mass	104
GI 10 Suspected liver mass in cirrhotic patients	106
GI 11 Jaundice in adult	110
GI 12 Suspected biliary disease in adult	112

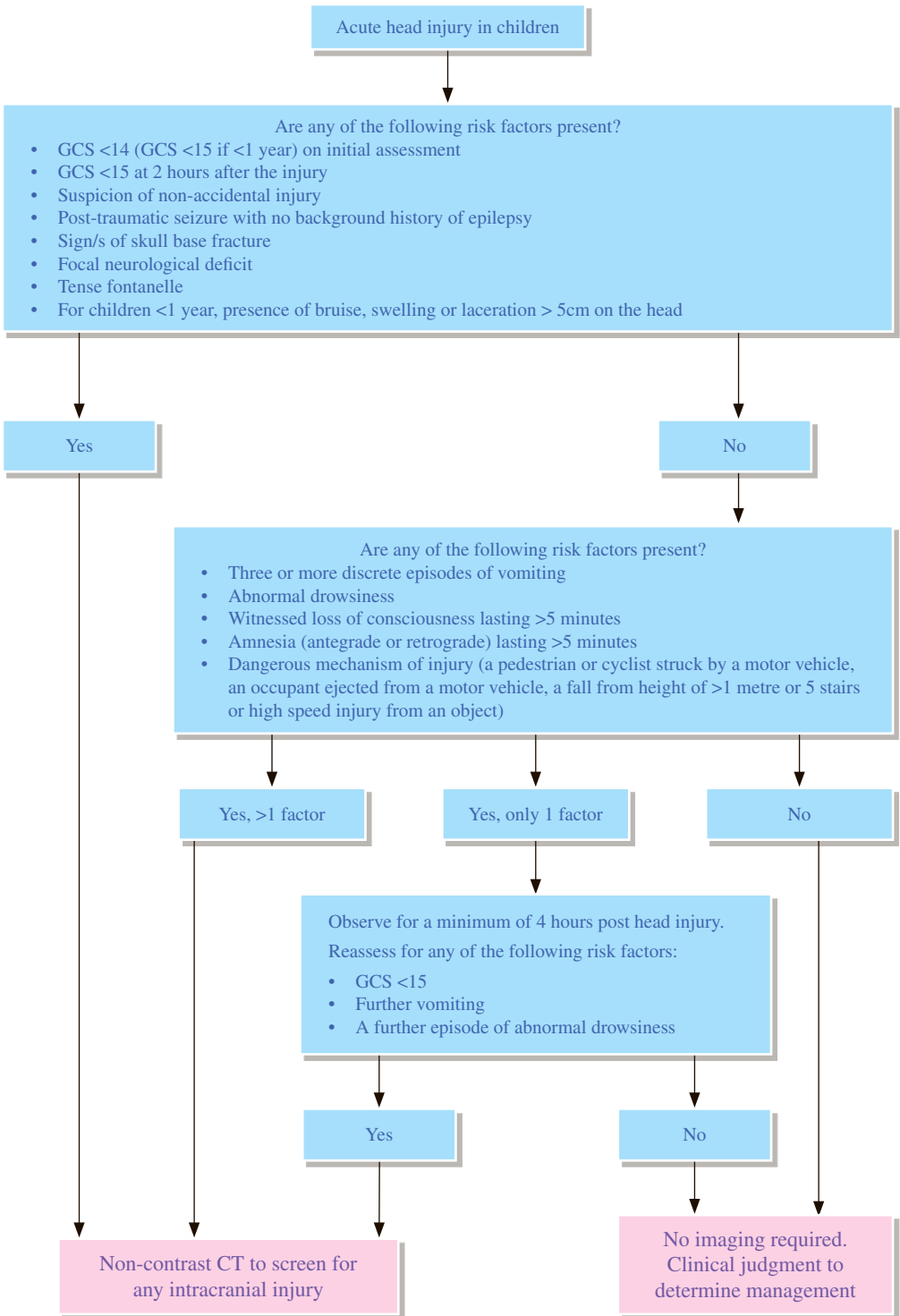
Uroradiology Guidelines	117
UR 1 Renal trauma	118
UR 2 Lower urinary tract injury	122
UR 3 Acute renal failure	124
UR 4 Acute flank pain	126
UR 5 Haematuria	128
UR 6 Renal mass	132
UR 7 Prostatism	134
UR 8 Acute scrotal pain	136
UR 9 Imaging in prostate cancer	138
Musculoskeletal Radiology Guidelines	143
MS 1 Acute osteomyelitis	144
MS 2 Non-traumatic shoulder pain	146
MS 3 Avascular necrosis of hip	148
MS 4 Primary bone tumour	150
MS 5 Soft tissue tumour	152
MS 6 Screening for bone metastasis with known primary malignancy	154
Breast Radiology Guidelines	157
BR 1 Palpable breast lump	158
BR 2 Mammography for self-referral asymptomatic woman	162
Obstetric & Gynaecological Radiology Guidelines	167
OG 1 Pelvic pain	168
OG 2 Pelvic mass	170
OG 3 Suspected ectopic pregnancy	172
Paediatric Radiology Guidelines	175
PD 1 Suspected non-accidental injury	176
PD 2 Paediatric seizures	180
PD 3 Vomiting in infants	184
PD 4 Non-traumatic abdominal pain	186
PD 5 Abdominal mass	190
PD 6 Urinary tract infection	192
Miscellaneous Guidelines	197
MC 1 Pyrexia of unknown origin	198
MC 2 Metastases from unknown primary	202
Contributors	208
Acknowledgement	209

Neuroradiology



Hong Kong College of Radiologists





REMARKS

1 General

- 1.1 It is the clinical condition of the patient that determines whether imaging is required or not.
- 1.2 Patients discharged from accident and emergency department after head injury should be given advice in verbal and written formats, which is also to be shared with their families and carers.

2 Plain radiograph

- 2.1 Normal skull x-ray (SXR) does not exclude intracranial pathology.
- 2.2 SXR is only useful for imaging for calvarial fractures, penetrating injuries and suspected radiopaque foreign bodies.

3 CT

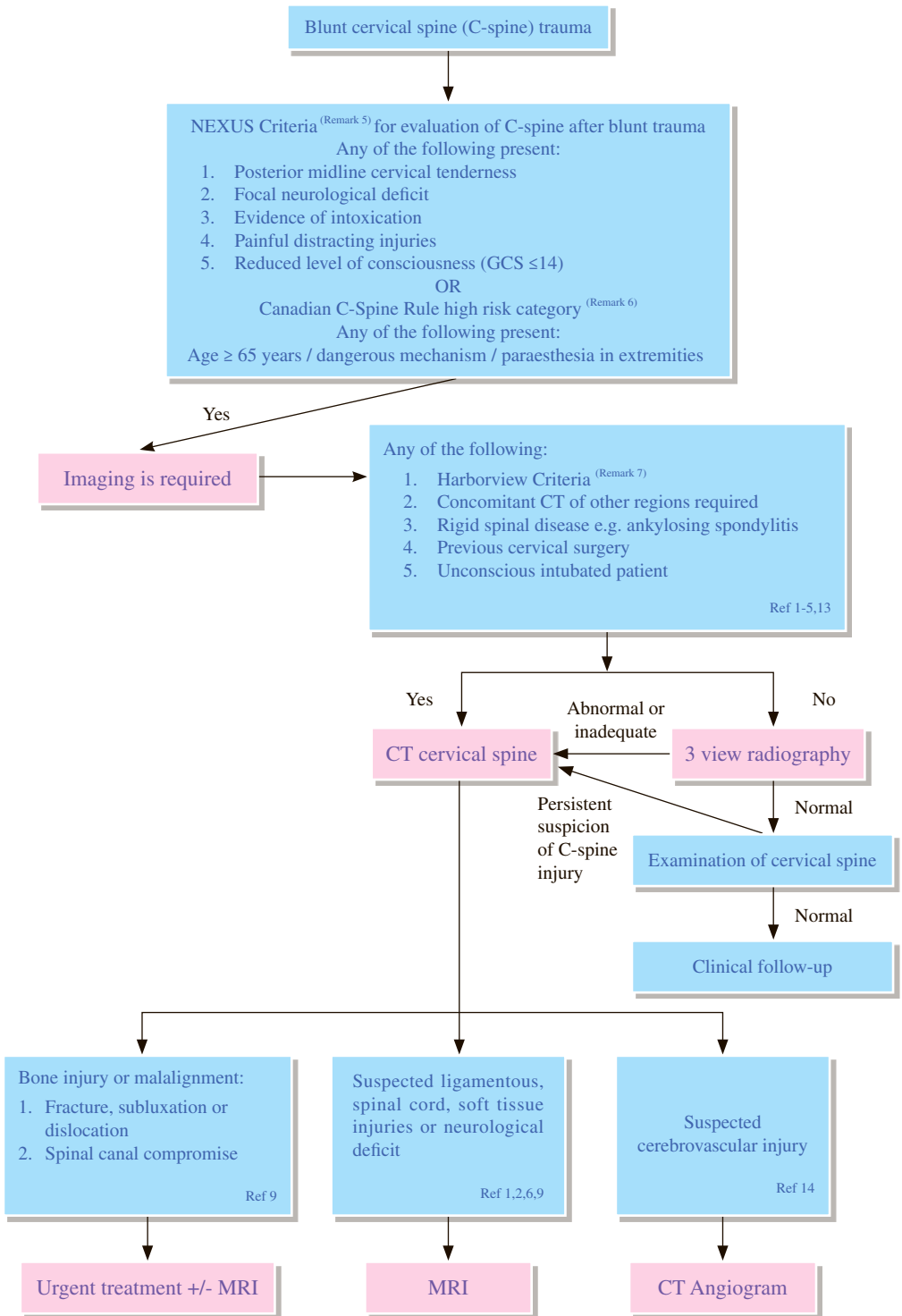
- 3.1 Non-contrast CT scan is the imaging modality of choice in evaluating head trauma.
- 3.2 In most cases, CT alone is sufficient to end the diagnostic imaging work up.
- 3.3 Early and repeated CT scanning may be required for further evaluation when there is deterioration (especially in the first 72 hours after head injury), to detect delayed haematoma, hypoxic-ischaemic lesions or cerebral oedema.

4 MRI

- 4.1 MRI is inappropriate as first line study in acute head trauma.
- 4.2 MRI is valuable as a problem solving tool in selected cases, such as in the following settings:
 - 4.2.1 Hypoxic-ischaemic encephalopathy
 - 4.2.2 Brain stem contusion (haemorrhagic / non-haemorrhagic)
 - 4.2.3 Diffuse axonal injury
 - 4.2.4 Small subdural haematoma

REFERENCES

1. National Institute for Health and Care Excellence (2014) Head Injury: assessment and early management. NICE guideline (CG176).
2. Shetty VS, Reis MN, Aulino JM, et al. ACR Appropriateness Criteria® Head Trauma. Available at <https://acsearch.acr.org/docs/69481/Narrative/>. American College of Radiology. Accessed 2017 April 4.



REMARKS

1 General

- 1.1 The imaging pathways in the algorithm are not mutually exclusive with each other and the use of the pathway should be guided by clinical suspicion.

2 Plain radiograph

- 2.1 Anteroposterior, lateral and open mouth views of the cervical spine are the basic views. It is essential that all seven cervical vertebrae are visualized including the cervicothoracic junction and the craniocervical junction.
- 2.2 Flexion-extension radiography is not useful in the acute injury period because of muscle spasm.⁶
- 2.3 It has advantages of lower radiation dose than CT which is important in younger patients.⁷ It is cheaper than CT, but cost-effectiveness must take into account the massive costs associated with even one missed fracture that results in spinal cord injury.^{7,8}
- 2.4 These limitations and the potential morbidity associated with missed fractures have led to a change in recommendations in preference to CT.^{1,8}

3 CT

- 3.1 CT with multiplanar reformats is highly sensitive and specific and superior to radiography in the detection of cervical spine injury in both alert and obtunded patients, or in patients who cannot be evaluated with plain radiography.^{9,10}
- 3.2 Useful in evaluation of bony displacement and in pre-operative planning.¹¹

4 MRI

- 4.1 Imaging modality of choice for evaluating ligamentous, spinal cord and soft tissue injuries, or for patients with neurological deficits not explained by plain film or CT findings, and for patients with injuries requiring posterior stabilization so as to exclude concomitant disc herniations that might alter the surgical approach.¹²
- 4.2 In trauma patients with ankylosing spondylitis, routine CT and MR imaging is recommended, even after minor trauma.¹³

5 National Emergency X-Radiography Utilization Study (NEXUS) Criteria

- 5.1 Any of the following
 - 5.1.1 Posterior midline cervical tenderness
 - 5.1.2 Focal neurological deficits
 - 5.1.3 Evidence of intoxication
 - 5.1.4 Painful distracting injuries
 - 5.1.5 Reduced level of consciousness (GCS \leq 14)

6 Canadian C-Spine Rule

- 6.1 High-risk factors that mandate radiography: age \geq 65 years, dangerous mechanism (i.e. fall from \geq 1 metre / 5 stairs; axial load to head e.g. diving; high speed ($>$ 100 km/h) motor vehicle collision; motorized recreational vehicles; bicycle collision), or paraesthesia in extremities.

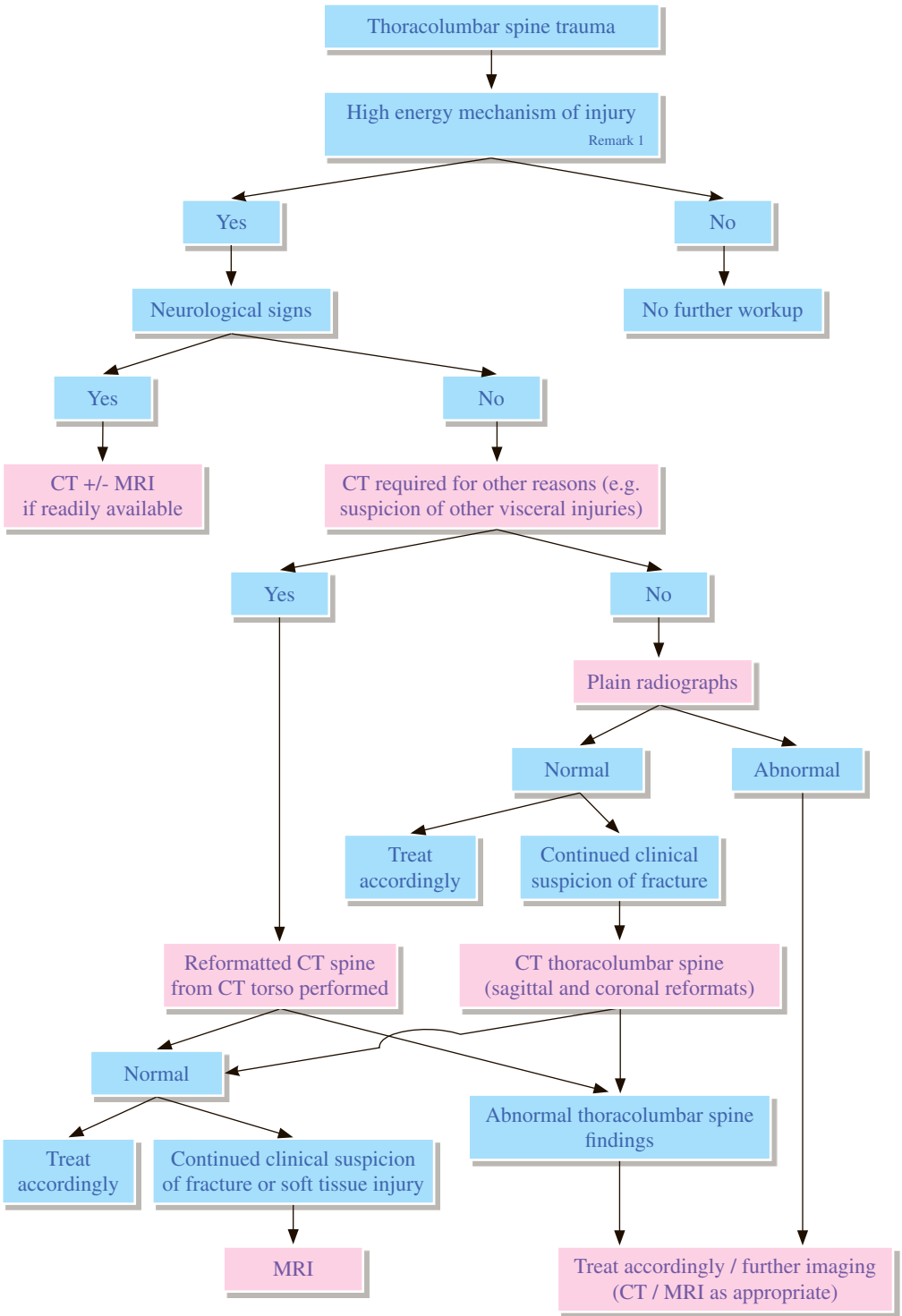
7 Harborview Criteria

7.1 Any of the following:

- 7.1.1 Presence of significant head injury
- 7.1.2 Presence of focal neurological deficit
- 7.1.3 Presence of pelvic or multiple extremity fractures
- 7.1.4 Combined impact of accident >50km/h
- 7.1.5 Death at the scene of the motor vehicle accident
- 7.1.6 Accident involved a fall from a height of 3m or more

REFERENCES

1. Mower WR, Wolfson AB, Hoffman JR, Todd KH. The Canadian C-spine rule. *N Engl J Med.* 2004; 350: 1467-1469; author reply 1467-1469.
2. Hoffman JR, Mower WR, Wolfson AB, Todd KH, Zucker MI. Validity of a set of clinical criteria to rule out injury to the cervical spine in patients with blunt trauma. National Emergency X-Radiography Utilization Study Group. *N Engl J Med.* 2000; 343: 94-99.
3. Hanson JA, Blackmore CC, Mann FA, Wilson AJ. Cervical spine injury: a clinical decision rule to identify high-risk patients for helical CT screening. *AJR Am J Roentgenol.* 2000 Mar; 174: 713-717.
4. Vandemark RM. Radiology of the cervical spine in trauma patients: practice pitfalls and recommendations for improving efficiency and communication. *AJR Am J Roentgenol.* 1990; 155: 465-472.
5. Stiell IG, Clement CM, McKnight RD, Brison R, Schull MJ, Rowe BH, et al. The Canadian C-spine rule versus the NEXUS low-risk criteria in patients with trauma. *N Engl J Med.* 2003; 349: 2510-2518.
6. Duane TM, Cross J, Scarcella N, Wolfe LG, Mayglothling J, Aboutanos MB, et al. Flexion-extension cervical spine plain films compared with MRI in the diagnosis of ligamentous injury. *Am Surg.* 2010; 76: 595-598.
7. Theocharopoulos N, Chatzakis G, Damilakis J. Is radiography justified for the evaluation of patients presenting with cervical spine trauma? *Med Phys.* 2009; 36: 4461-4470.
8. Grogan EL, Morris JA Jr, Dittus RS, Moore DE, Poulouse BK, Díaz JJ, Speroff T. Cervical spine evaluation in urban trauma centers: lowering institutional costs and complications through helical CT scan. *J Am Coll Surg.* 2005 Feb; 200: 160-165.
9. Hadley MN, Walters BC, Aarabi B, Dhall SS, Gelb DE, Harrigan MR, et al. Guidelines for the management of acute cervical spine and spinal cord injuries. *Neurosurgery.* 2013; 72(Suppl 2): 1-259.
10. Bailitz J, Starr F, Beecroft M, Bankoff J, Roberts R, Bokhari F, et al. CT should replace three-view radiographs as the initial screening test in patients at high, moderate, and low risk for blunt cervical spine injury: a prospective comparison. *J Trauma.* 2009; 66: 1605-1609.
11. Cornelius RS. Imaging of acute cervical spine trauma. *Semin Ultrasound CT MR.* 2001; 22: 108-124.
12. Holmes JF, Mirvis SE, Panacek EA, Hoffman JR, Mower WR, Velmahos GC. Variability in computed tomography and magnetic resonance imaging in patients with cervical spine injuries. *J Trauma.* 2002; 53: 524-529; discussion 530.
13. Anwar F, Al-Khayer A, Joseph G, Fraser MH, Jigajinni MV, Allan DB. Delayed presentation and diagnosis of cervical spine injuries in long-standing ankylosing spondylitis. *Eur Spine J.* 2011; 20: 403-407.
14. Biffi WL, Egglin T, Benedetto B, Gibbs F, Cioffi WG. Sixteen-slice computed tomographic angiography is a reliable noninvasive screening test for clinically significant blunt cerebrovascular injuries. *J Trauma.* 2006; 60: 745-751.
15. Department of Health, Government of Western Australia. Diagnostic Imaging Pathways – Cervical Spine Injury. Perth: Department of Health, Government of Western Australia; 2013 August.
16. Australasian College for Emergency Medicine. Guidelines on Diagnostic Imaging. Melbourne: Australasian College for Emergency Medicine; 2012 July.



REMARKS

1 General

- 1.1 Radiological workup is indicated for cases with high energy mechanism of injury including:

History of significant mechanism of injury such as high impact motor vehicle accident or fall from a height >1 metre, concomitant cervical spine fracture, back pain or tenderness on palpation, local signs of thoracolumbar injury, neurological deficits, altered mental status, major distracting injuries, evidence of intoxication with ethanol or drugs.^{1,3-6}

- 1.2 Approximately 20% of patients with a spinal column fracture will have a non-contiguous fracture. Non-contiguous fractures are associated with other severe injuries and should be suspected and investigated in injuries involving high-velocity mechanisms.^{2,8}

2 Plain radiograph

- 2.1 Plain films are considered adequate for the evaluation of thoracolumbar spine if the patient does not require CT scan for any other reason.^{1, 3- 4, 6}

3 CT

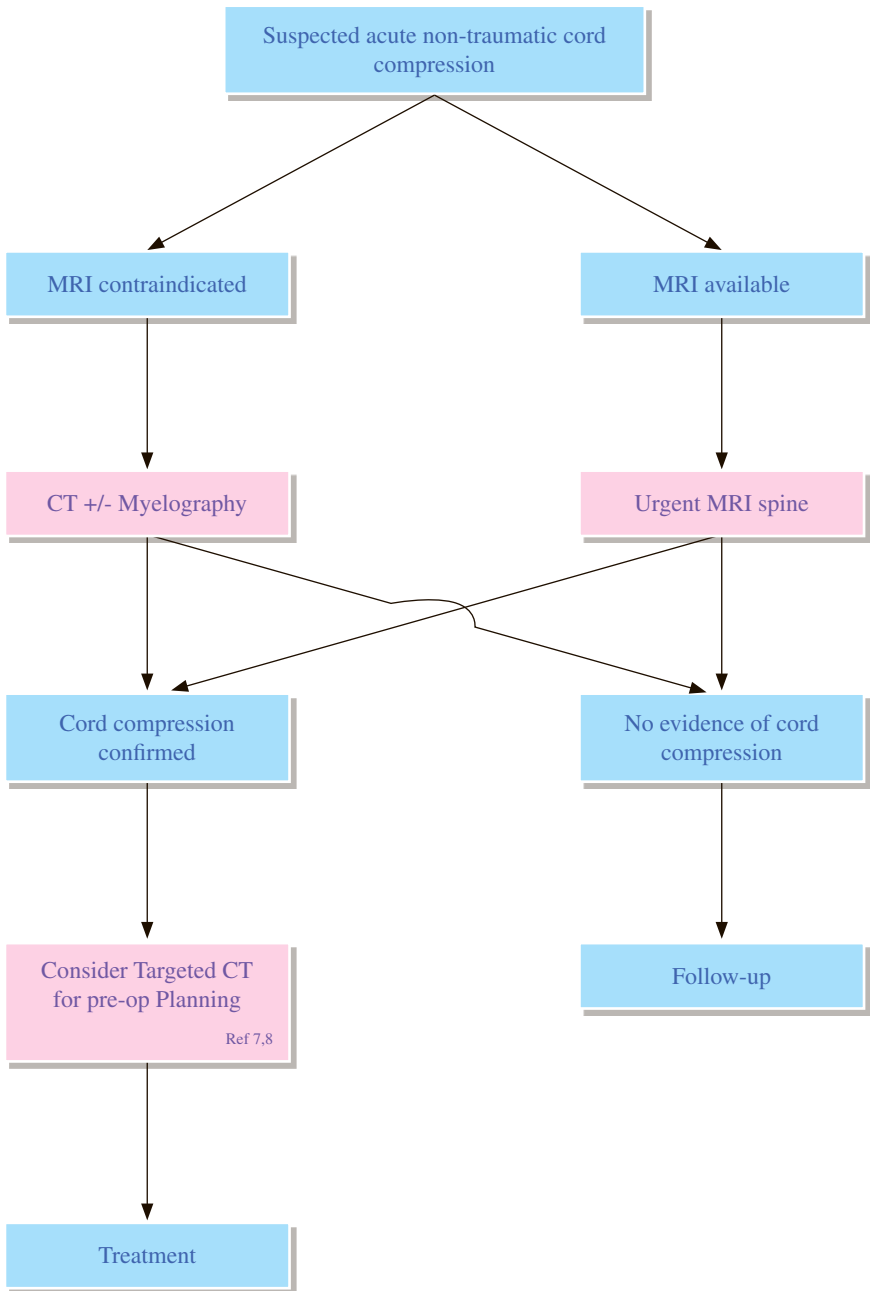
- 3.1 CT is excellent in imaging bony fractures. In patients who undergo torso CT (thorax, abdomen and pelvis), the images will be adequate to evaluate the spine with sagittal and coronal reformats.^{2-3, 7}

4 MRI

- 4.1 MRI should be performed if there is clinical concern for cord compression or ligamentous instability, as well as when clinical suspicion is high for an unstable injury despite normal radiographic evaluation.

REFERENCES

1. Department of Health, Government of Western Australia. Diagnostic Imaging Pathways – Thoraco-Lumbar Spine Trauma. Perth: Department of Health, Government of Western Australia; 2013 August.
2. Daffner RH, Weissman BN, Wippold II FJ, et al. ACR Appropriateness Criteria® Suspected Spine Trauma. Available at <https://acsearch.acr.org/docs/69359/Narrative/>. American College of Radiology. Accessed 2017 April 6.
3. Diaz JJ Jr, Cullinane DC, Altman DT, Bokhari F, Cheng JS, Como J, et al. Practice management guidelines for the screening of thoracolumbar spine fracture. *J Trauma*. 2007; 63: 709-718.
4. Frankel HL, Rozycki GS, Ochsner GM, et al. Indications for obtaining surveillance thoracic and lumbar spine radiographs. *J Trauma*. 1994; 37: 673-676.
5. Hsu JM, Joseph T, Ellis AM. Thoracolumbar fracture in blunt trauma patients: guidelines for diagnosis and imaging. *Injury*. 2003; 34: 426-433.
6. Holmes JF, Panacek EA, Miller PQ, Lapidis AD, Mower WR. Prospective evaluation of criteria for obtaining thoracolumbar radiographs in trauma patients. *J Emerg Med*. 2003; 24: 1-7.
7. Inaba K, Munera F, McKenney M, et al. Visceral torso computed tomography for clearance of the thoracolumbar spine in trauma: a review of the literature. *J Trauma*. 2006; 60: 915-920.
8. Nelson DW, Martin MJ, Martin ND, Beekley A. Evaluation of the risk of noncontiguous fractures of the spine in blunt trauma. *J Trauma Acute Care Surg*. 2013; 75: 135-139.



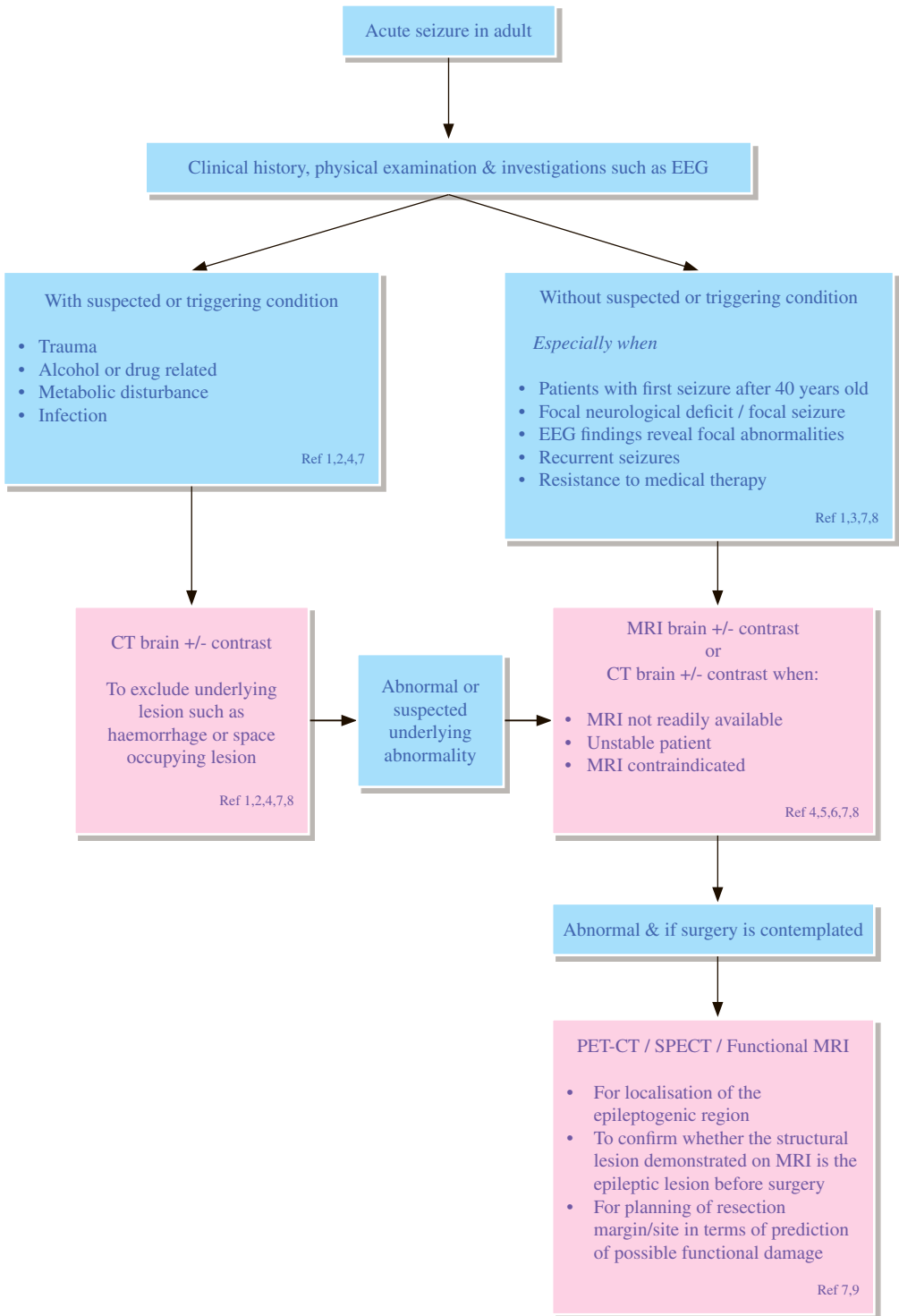
REMARKS

1 General

- 1.1 Cord compression is to be suspected when there is presence of motor deficit or sensory disturbance. Though pain is a common symptom, it is not an essential feature of cord compression.^{5,6}
- 1.2 Do not perform plain radiographs of the spine either to make or to exclude the diagnosis of spinal metastases or metastatic spinal cord compression (MSCC).^{7,8}
- 1.3 MRI of the spine should be performed in all patients with suspected MSCC, unless contraindicated.^{7,8}
- 1.4 MRI of the whole spine in patients with suspected MSCC should include sagittal T1, and / or short T1 inversion recovery (STIR) and sagittal T2 weighted sequences. Perform supplementary axial imaging through any significant abnormality noted on the sagittal scan.^{7,9}
- 1.5 Consider targeted CT scan with 3-plane reformats to assess spinal stability and plan vertebroplasty, kyphoplasty or spinal surgery in patients with MSCC.^{8,9}

REFERENCES

1. The Royal College of Radiologists. Making the best use of a department of clinical radiology. 4th ed. London: Royal College of Radiologists; 1998. p. 34.
2. Royal Australasian College of Radiologists. Imaging guidelines. 3rd ed. Melbourne: Royal Australasian College of Radiologists; 1997. p. 28-29.
3. Carmody RF, Yang PJ, Seelly GW, Seeger JF, Unger EC, Johnson JE. Spinal cord compression due to metastatic disease: diagnosis with MR imaging vs myelography. *Radiology* 1989; 173: 225-229.
4. Jordon JE, Donaldson SS, Enzmann DR. Cost effectiveness and outcome assessment of magnetic resonance imaging in diagnosing cord compression. *Cancer* 1995; 75: 2579-2586.
5. Johnstone RA. The management of acute spinal cord compression. *J Neurol Neurosurg Psychiatry* 1993; 56: 1046-1054.
6. Patten J. Neurological differential diagnosis. 2nd ed. New York: Springer-Verlag, 1995. p. 213-225.
7. National Institute for Health and Clinical Excellence (2008) Metastatic spinal cord compression in adults: risk assessment, diagnosis and management. NICE guideline (CG75).
8. Boleti E, Grant I, Collins E, How S. Metastatic spinal cord compression in London cancer. Management and service guidelines. V1.1 Final. 2013 December.
9. Department of Health, Government of Western Australia. Diagnostic Imaging Pathways – Spinal Cord Compression (Suspected). Perth: Department of Health, Government of Western Australia; 2014 June.



REMARKS

Imaging is not indicated in idiopathic generalized epilepsy.

1 Plain radiograph

- 1.1 Skull x-ray (SXR) is generally not indicated in the investigation of seizure.

2 Nuclear medicine

- 2.1 Combined data from interictal and ictal single photon emission computed tomography (SPECT) scans give a lot more information than interictal scans alone.
- 2.2 Fluorodeoxyglucose (FDG) PET has high sensitivity and specificity in localizing the epileptogenic zone, especially in temporal lobe epilepsy.
- 2.3 Both SPECT and FDG PET-CT may be helpful in pre-operative planning.

3 CT

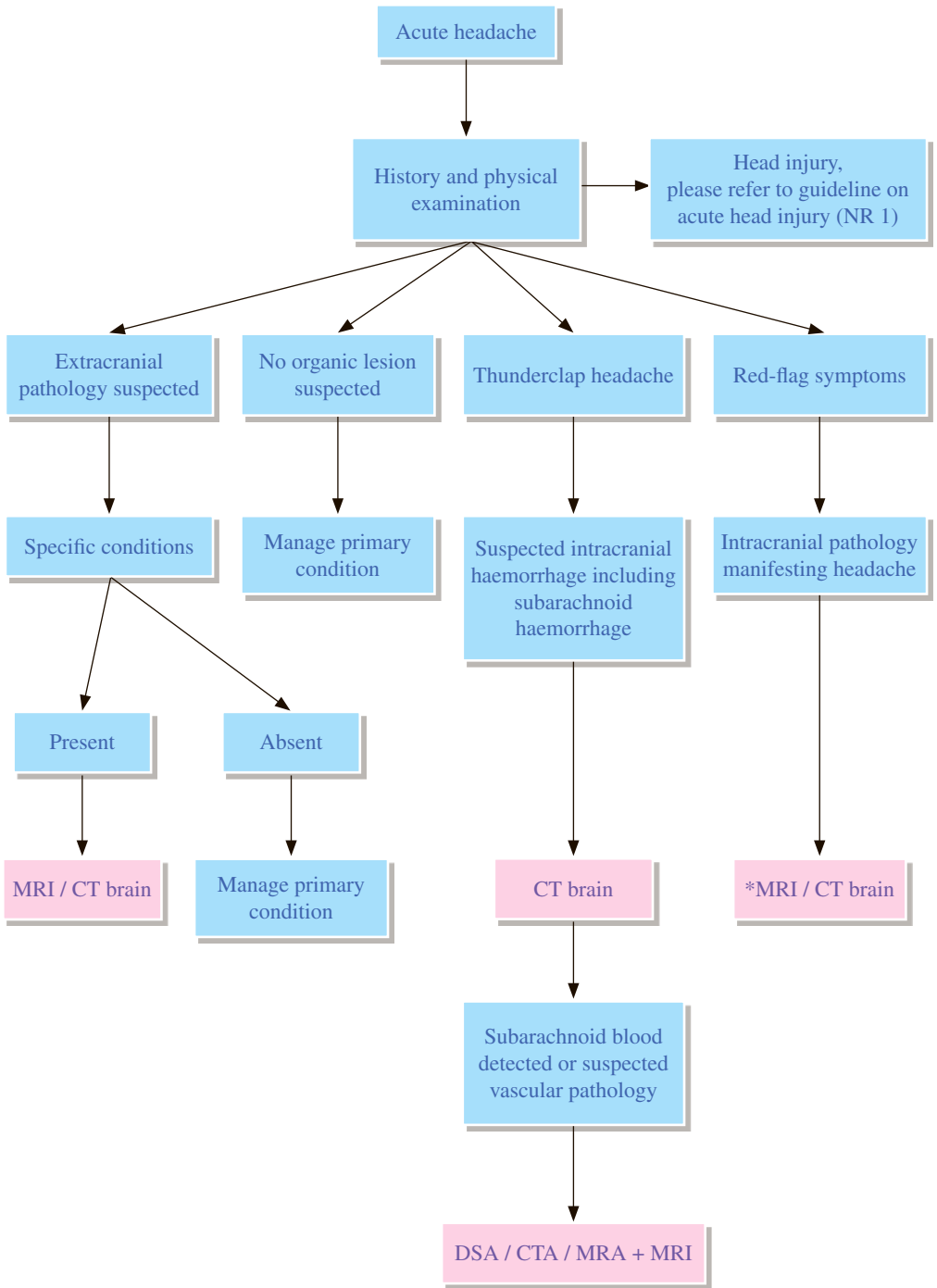
- 3.1 In acute or emergency setting, non-contrast CT brain can be the imaging study of choice.
- 3.2 CT is useful to detect intracranial haemorrhage or calcific lesion.
- 3.3 CT is an appropriate investigation if MRI is not readily available, in patients with unstable conditions or when MRI is contraindicated.
- 3.4 Contrast-enhanced examination should be performed if intracranial infection, tumour, inflammatory lesion or vascular pathology is suspected.

4 MRI

- 4.1 MRI is preferable to CT as the first imaging investigation in clinically stable and/or symptomatic patients due to its high sensitivity to small change in tissue, e.g. migrational anomalies, gyral malformations, etc.
- 4.2 In unstable patients, MRI is relatively contraindicated and needs close monitoring.
- 4.3 Coronal MRI is helpful to lateralize the temporal lobe seizure focus.
- 4.4 High resolution MRI sequences are preferred.
- 4.5 Contrast-enhanced examination should be performed if intracranial infection, tumour, inflammatory lesion or vascular pathology is suspected.
- 4.6 Functional MRI maybe helpful in pre-operative planning.

REFERENCES

1. Greenberg MK, Barsan WG, Starkmans S. Neuroimaging in the emergency patient presenting with seizure. *Neurology*. 1996; 47: 26-32.
2. Zwimpfer TJ, Brown J, Sullivan I, Moulton RJ. Head injuries due to falls caused by seizures: a group at high risk for traumatic intracranial haematomas. *J Neurosurg*. 1997; 86: 433-437.
3. Duncan JS. Imaging and epilepsy. *Brain*. 1997; 120: 339-377.
4. Harden CL, Huff JS, Schwartz TH, Dubinsky RM, Zimmerman RD, Weinstein S, et al. Therapeutics and Technology Assessment Subcommittee of the American Academy of Neurology. Reassessment: neuroimaging in the emergency patient presenting with seizure (an evidence-based review): report of the Therapeutics and Technology Assessment Subcommittee of the American Academy of Neurology. *Neurology*. 2007; 69: 1772-1780.
5. Toh KH. Clinical applications of magnetic resonance imaging in the central nervous system. *Ann Acad Med Singapore*. 1993; 22: 785-793.
6. Heinz ER, Heinz TR, Radtke R, Darwin R, Drayer BP, Fram E, et al. Efficacy of MR vs CT in epilepsy. *AJR Am J Roentgenol*. 1989; 152: 347-352.
7. Luttrull MD, Cornelius RS, Angtuaco EJ, et al. ACR Appropriateness Criteria® Seizures and Epilepsy. Available at <https://acsearch.acr.org/docs/69479/Narrative/>. American College of Radiology. Accessed 2017 April 15.
8. National Institute for Health and Clinical Excellence (2012) Epilepsies: diagnosis and management. NICE guideline (CG137).
9. Goffin K, Dedeuwaerdere S, Van Laere K, Van Paesschen W. Neuronuclear assessment of patients with epilepsy. *Semin Nucl Med*. 2008; 38: 227-239.



REMARKS

1 General

- 1.1 Thunderclap headache refers to acute onset of the worst headache in the individual's life.
- 1.2 Primary headache disorders include migraine, tension and cluster headache. However, a change in the pattern of the headache should raise the concern of a superimposed organic lesion.
- 1.3 Red flag symptoms raise the suspicion of organic lesions, including:
 - 1.3.1 New headache in an older population
 - 1.3.2 New onset of headache with history of cancer or immunodeficiency
 - 1.3.3 New onset of headache in a patient on anti-coagulation therapy
 - 1.3.4 Headache with alterations in mental state
 - 1.3.5 Headache with fever, neck stiffness and meningeal signs
 - 1.3.6 Headache with focal neurological deficit if not previously documented as a migraine with aura
 - 1.3.7 Substance abuse with amphetamine or cocaine
 - 1.3.8 Patient is pregnant* or post-partum
 - 1.3.9 Headache causing awakening from sleep or worsened by Valsalva manoeuvre;
 - 1.3.10 Progressively worsening headache.

*Radiation risk and benefit for examination in pregnant women should be weighted based on individual case. During pregnancy, imaging modalities not associated with ionizing radiation (e.g. MRI) should be considered when appropriate.
- 1.4 Some specific conditions which are extracranial causes of headache render further investigation with imaging:
 - 1.4.1 Middle or inner ear symptoms, including vertigo. If imaging is needed following specialist assessment, MRI is more sensitive, especially for acoustic neuromas.
 - 1.4.2 For sinus disease if there has been failure of maximum medical treatment, and / or suspected complications, e.g. orbital cellulitis or suspicion of malignancy.
 - 1.4.3 Congenital anomalies, benign and malignant neoplasms, trauma, vascular malformations, evaluation of palpable masses, planning and follow-up of radiotherapy.
 - 1.4.4 Orbital lesions, including eye trauma in which there may be an associated facial fracture. US may be appropriate for intraocular lesions. CT scan may also be indicated for strong suspicion of an intraocular foreign body that has not been shown on X-ray.
 - 1.4.5 Fractures of the temporal bone, skull, and face.
 - 1.4.6 Evaluation of the skull base including primary and secondary bone lesions.

2 Plain radiograph

- 2.1 Plain skull radiography rarely contributes to the management of acute non-traumatic headache. Its main role is probably limited to headache of paranasal sinus origin, in which CT is still the preferred modality of examination.

3 CT

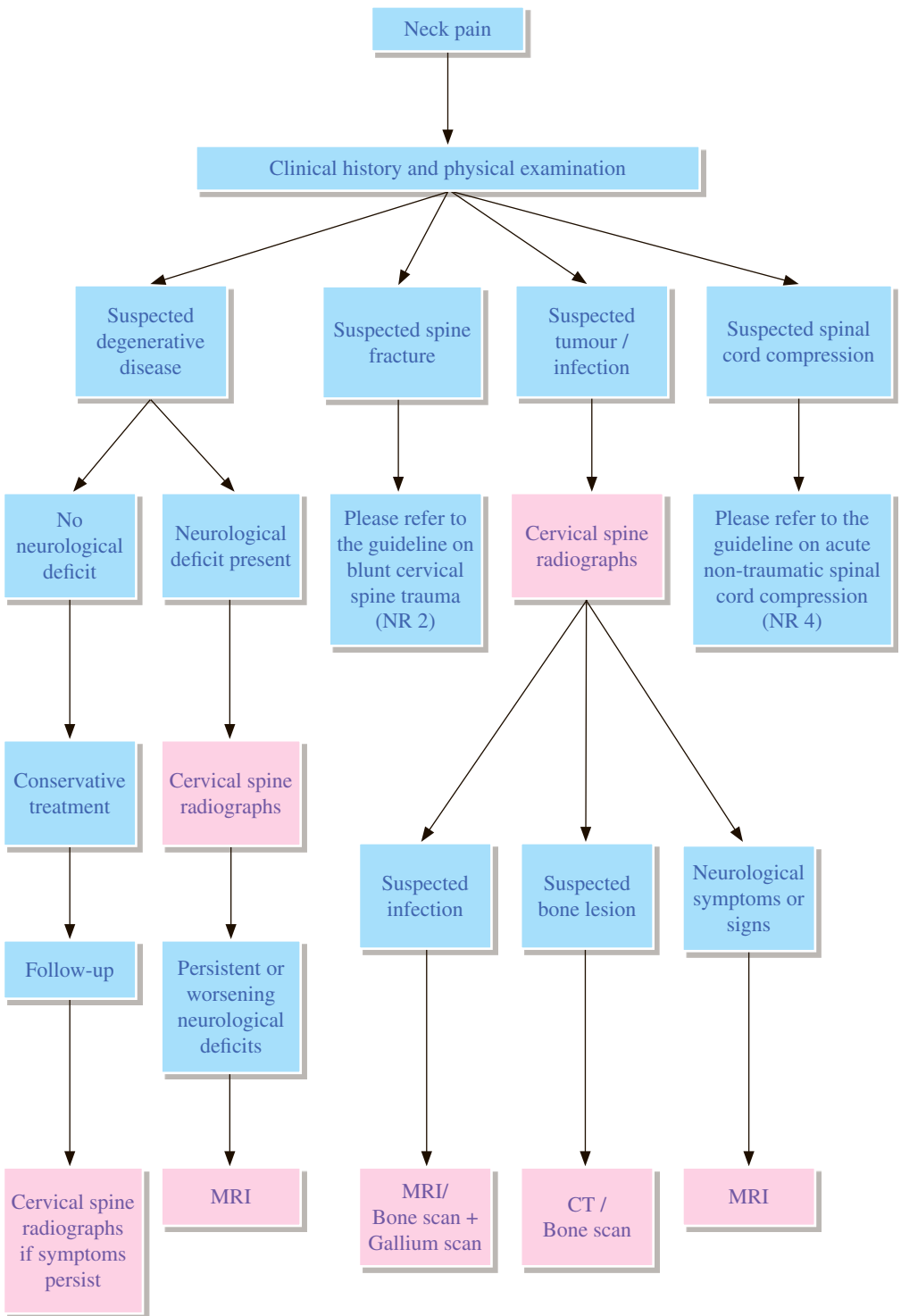
3.1 CT brain is sensitive to detect extravasated blood. Bony pathology is also best depicted by CT.

4 MRI

4.1 MRI is superior to CT in the assessment of most intracranial pathologies with the exception of acute haemorrhage and bony / calcific lesions.

REFERENCES

1. American College of Emergency Physicians. Clinical policy for the initial approach to adolescents and adults presenting to the emergency department with chief complaint of headache. *Ann Emerg Med.* 1996; 27: 821-844.
2. Day JW, Raskin NH. Thunderclap headache: symptom of unruptured cerebral aneurysm. *Lancet.* 1986; 2: 1247.
3. Hyman RA, Gorey MT. Imaging strategies for MR of the brain. *Radiol Clin North Am.* 1988; 26: 471-503.
4. Edlow JA, Panagos PD, Godwin SA, Thomas TL, Decker WW. Clinical policy: Critical issues in the evaluation and management of adult patients presenting to the emergency department with acute headache. *J Emerg Nurs.* 2009; 35: e43-71.
5. Souglas AC, Wippold II FJ, Broderic DF, et al. ACR Appropriateness Criteria® Headache. Available at <https://acsearch.acr.org/docs/69482/Narrative/>. American College of Radiology. Accessed 2017 September 11.



REMARKS

1 Plain radiograph

- 1.1 Plain film abnormalities may not necessarily correlate with significant neurological lesion.
- 1.2 If CT is not available, open-mouth view may be needed to assess the C1/C2 region. Swimmer's view may be needed if the lower cervical levels are not well demonstrated on the lateral view.
- 1.3 Flexion and extension views are needed in patients with suspected ligamentous injury with normal initial radiographs.
- 1.4 Oblique radiographs are no longer recommended as part of the initial radiographic evaluation of the cervical spine in the setting of chronic neck pain.

2 Nuclear medicine

- 2.1 Combined gallium and bone scan studies have high sensitivity and specificity in diagnosing vertebral osteomyelitis and should be considered the imaging modality of choice when MRI is contraindicated.¹
- 2.2 Use of single photon emission computed tomography (SPECT) imaging may be helpful in identifying the pain source e.g. facet disease.²

3 CT

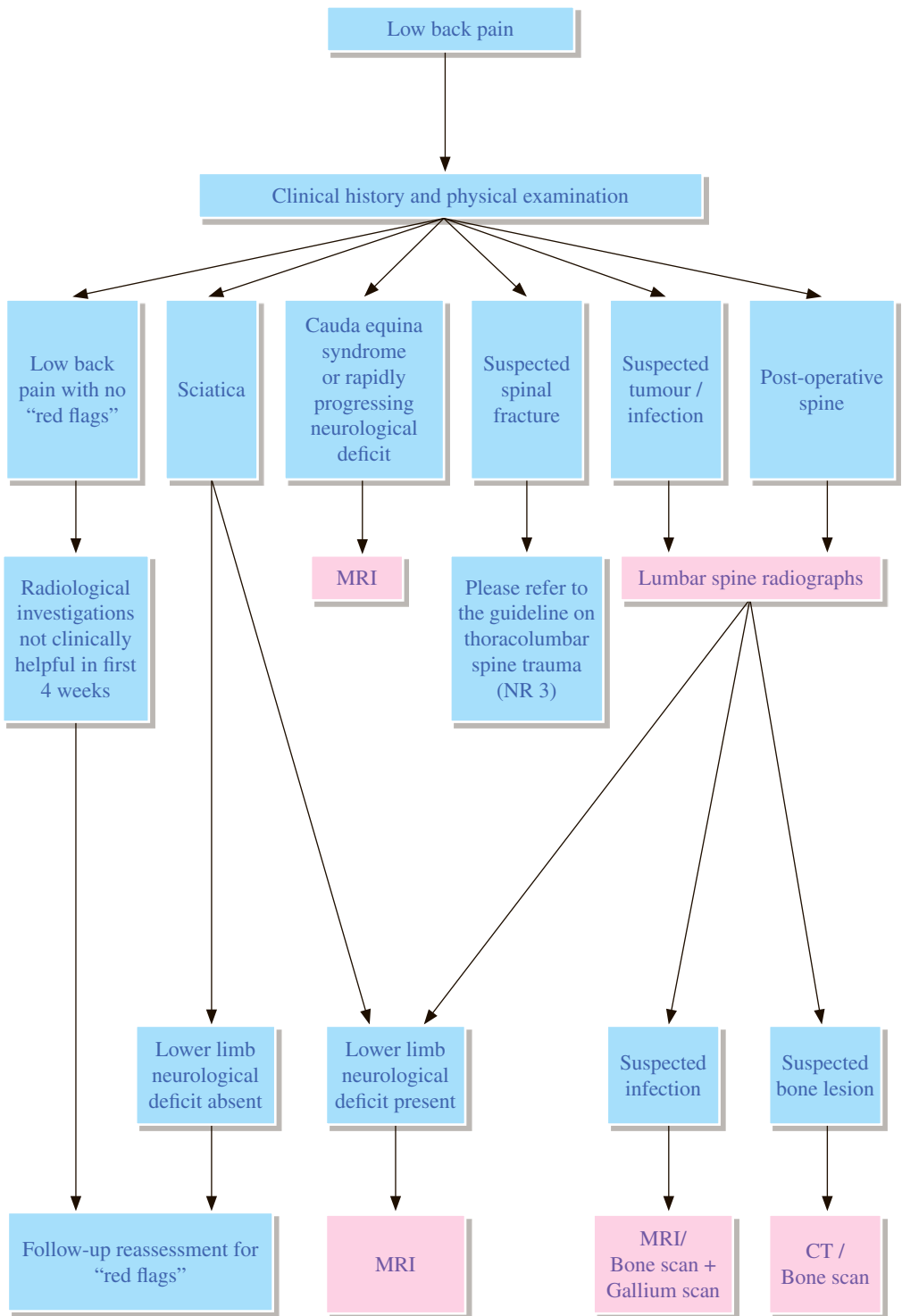
- 3.1 CT myelography may be particularly advantageous in evaluating osseous lesion which contribute to canal or foraminal narrowing, and is a viable alternative to MRI for patients with suspected cord involvement, when MRI cannot be performed.³
- 3.2 Both CT and MRI can accurately diagnose tumors and inflammation, and they should be considered complementary studies.⁴

4 MRI

- 4.1 MRI gives excellent depiction of bone marrow signal, intervertebral discs, facet arthropathy and spinal stenosis, and may be considered the first line advanced imaging study in patients with chronic neck pain.⁵
- 4.2 Specific indications for MRI also include suspected malignancy or infection, whether neurological symptoms are present or not.⁶

REFERENCES

1. Modic MT, Feiglin DH, Piraino DW, Boumpfrey F, Weinstein MA, Duchesneau PM, et al. Vertebral osteomyelitis: assessment using MR. *Radiology* 1985; 157: 157-166.
2. Makki D, Khazim R, Zaidan AA, Ravi K, Toma T. Single photon emission computerized tomography (SPECT) scan-positive facet joints and other spinal structures in a hospital-wide population with spinal pain. *Spine J*. 2010; 10: 58-62.
3. Song KJ, Choi BW, Kim GH, Kim JR. Clinical usefulness of CT-myelogram comparing with the MRI in degenerative cervical spinal disorders: is CTM still useful for primary diagnostic tool? *J Spinal Disord Tech*. 2009; 22: 353-357.
4. Newman JS, Weissman BN, Angevine PD, et al. ACR Appropriateness Criteria® Chronic Neck Pain. Available at <https://acsearch.acr.org/docs/69426/Narrative/>. American College of Radiology. Accessed 2017 September 12.
5. Ozawa H, Sato T, Hyodo H, Ishii Y, Morozumi N, Koizumi Y, et al. Clinical significance of intramedullary Gd-DTPA enhancement in cervical myelopathy. *Spinal Cord*. 2010; 48: 415-422.
6. Laker SR, Concannon LG. Radiologic evaluation of the neck: a review of radiography, ultrasonography, computed tomography, magnetic resonance imaging, and other imaging modalities for neck pain. *Phys Med Rehabil Clin N Am*. 2011; 22: 411-428.
7. The Royal College of Radiologists. *iRefer: Making the best use of clinical radiology*. 7th edition. London: The Royal College of Radiologists; 2012.



REMARKS

1 General

- 1.1 Uncomplicated acute low back pain and/or radiculopathy is a benign, self-limited condition that does not warrant any imaging studies.²⁻⁶
- 1.2 “Red flags” are indications of a more complicated status of back pain/radiculopathy in the following settings:^{7,8}
 - 1.2.1 Trauma, cumulative trauma
 - 1.2.2 Insidious onset of unexplained weight loss
 - 1.2.3 Age > 50 years, especially women, and males with osteoporosis or compression fracture
 - 1.2.4 Unexplained fever, history of urinary or other infection
 - 1.2.5 Immunosuppression, diabetes mellitus
 - 1.2.6 History of cancer
 - 1.2.7 Intravenous drug abuse
 - 1.2.8 Prolonged use of corticosteroids or osteoporosis
 - 1.2.9 Age >70 years
 - 1.2.10 Focal neurologic deficits with progressive or disabling symptoms, cauda equina syndrome
 - 1.2.11 Duration > 6 weeks
 - 1.2.12 Prior surgery

2 Plain radiographs

- 2.1 They are recommended if any of the “red-flags” are present.⁹⁻¹⁰
- 2.2 Lumbar spine radiographs may be sufficient for the initial evaluation of:
 - 2.2.1 Recent significant trauma (any age)
 - 2.2.2 Prolonged use of steroid
 - 2.2.3 Osteoporosis
 - 2.2.4 Age > 70 years
- 2.3 Oblique views may be useful for specific conditions like spondylolysis and facet joint disease.¹¹
- 2.4 Radiographs have a role in evaluation of alignment, instability, and scoliosis and in postoperative evaluation of instrumentation and fusion.

3 Nuclear Medicine

- 3.1 Bone scan is moderately sensitive but nonspecific in diagnosing tumor, infection or occult vertebral fracture.^{9,10} Specificity of diagnosis of skeletal infection is improved when correlating with gallium scintigraphy.
- 3.2 Bone scan is also useful in surveying the entire skeleton.
- 3.3 Single Photon Emission Computed Tomography (SPECT)/CT improves localization of active sites in bone scan.

4 MRI

- 4.1 Low back pain complicated with the red flags may justify early use of CT or MRI even if radiographs are negative.⁹
- 4.2 MRI is the imaging modality of choice in diagnosing disc herniation.¹⁴⁻¹⁵ If MRI is not available or contraindicated, CT myelogram can be performed.
- 4.3 MRI with contrast is useful for suspected infection and neoplasia.
- 4.4 MRI with contrast allows distinction between disc and scar in post-operative patients.

5 CT

- 5.1 Provides superior bone detail but not as useful in depicting extradural soft tissue when compared with MRI.
- 5.2 Useful for depicting bone/structural lesions and alignment such as spondylolysis, pseudoarthrosis, fracture, scoliosis and stenosis and for post-surgical evaluation of bone graft integrity, surgical fusion and instrumentation.¹⁶

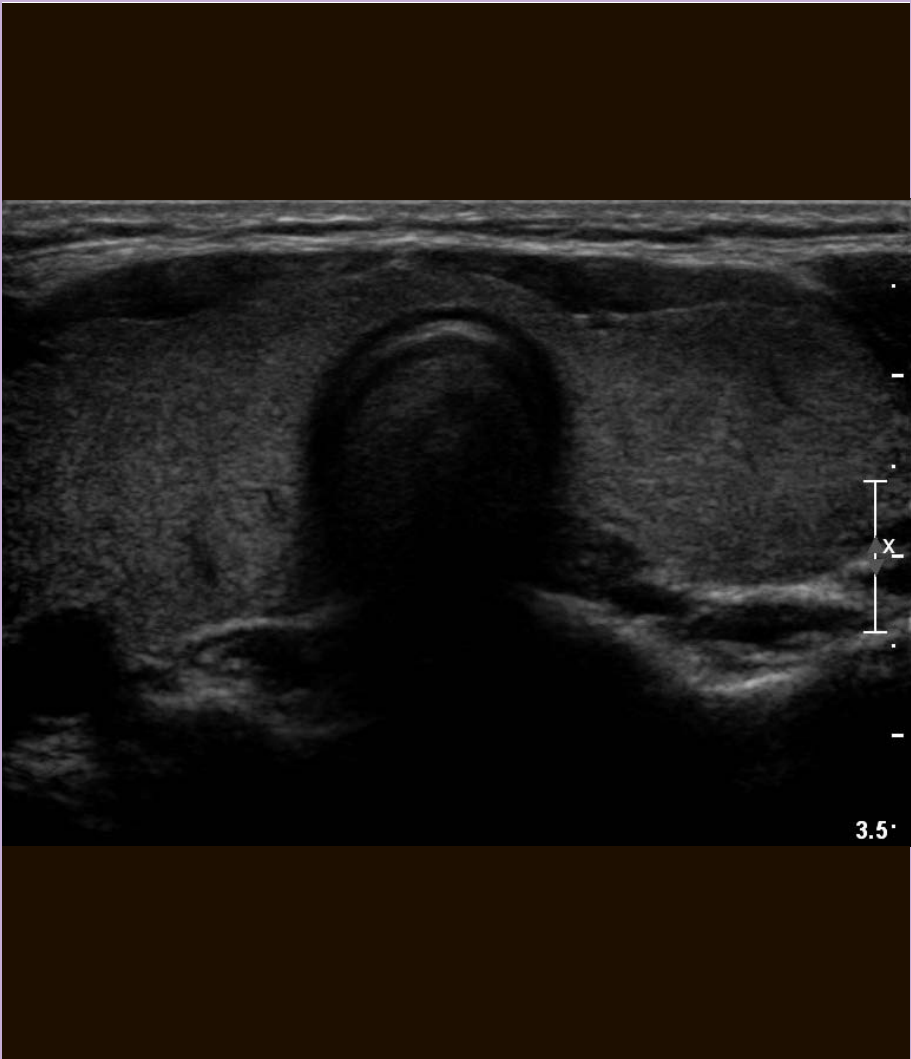6 Myelography and CT myelography

- 6.1 Complementary to plain CT or MRI and occasionally more accurate in diagnosing disc herniation, but requires lumbar puncture and intrathecal contrast injection.¹⁷⁻²⁰

REFERENCES

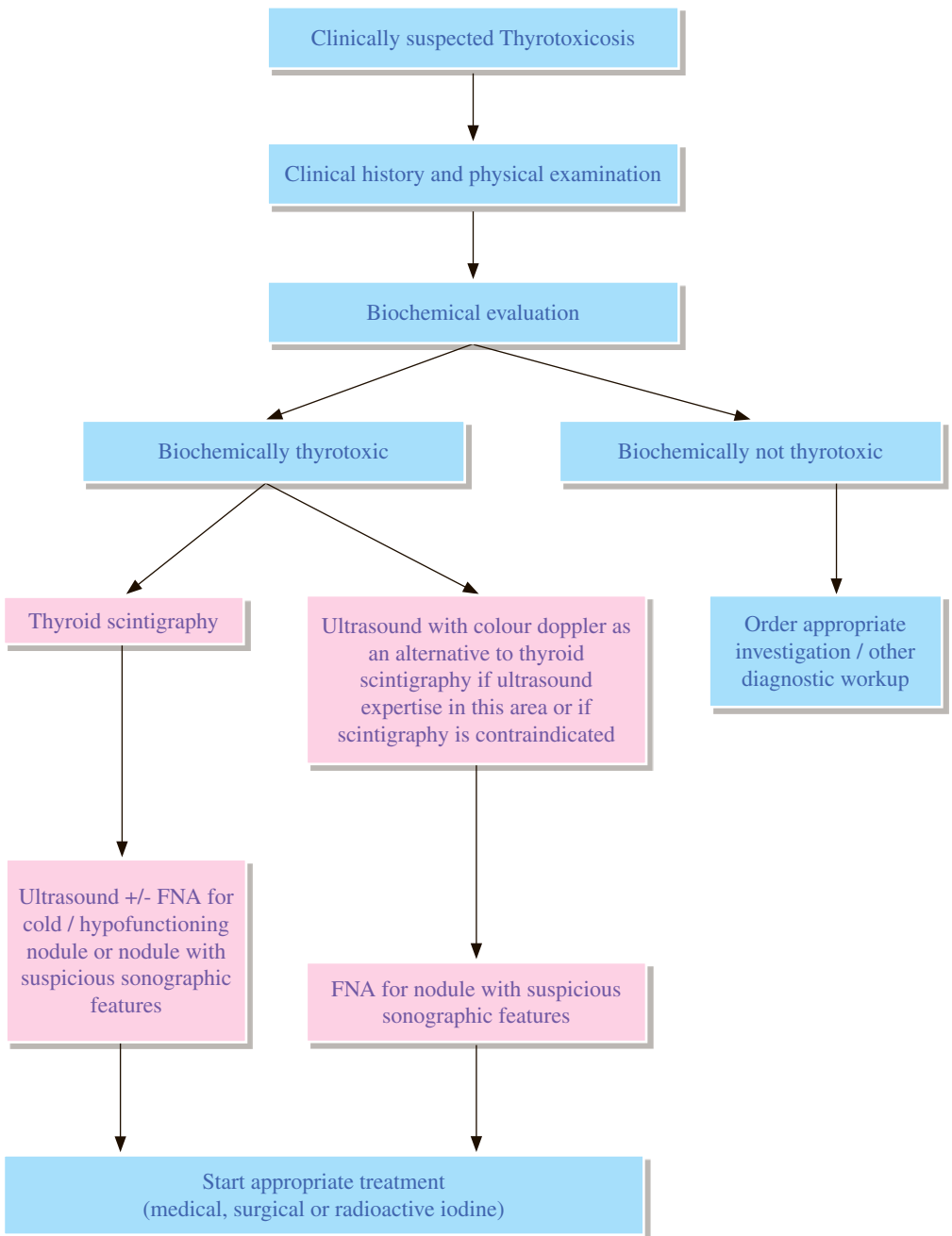
1. Patel ND, Broderick DF, Burns J, et al. ACR Appropriateness Criteria® Low Back Pain. Available at <https://acsearch.acr.org/docs/69483/Narrative/>. American College of Radiology. Accessed 2017 September 12.
2. Ren XS, Selim AJ, Fincke G, Deyo RA, Linzer M, Lee A, et al. Assessment of functional status, low back disability, and use of diagnostic imaging in patients with low back pain and radiating leg pain. *J Clin Epidemiol*. 1999; 52: 1063-1071.
3. Jarvik JG, Deyo RA. Diagnostic evaluation of low back pain with emphasis on imaging. *Ann Intern Med*. 2002; 137: 586-597.
4. Jarvik JG, Hollingworth W, Martin B, Emerson SS, Gray DT, Overman S, et al. Rapid magnetic resonance imaging vs radiographs for patients with low back pain: a randomized controlled trial. *JAMA*. 2003; 289: 2810-2818.
5. Modic MT, Obuchowski NA, Ross JS, Brant-Zawadzki MN, Grooff PM, Mazanec DJ, et al. Acute low back pain and radiculopathy: MR imaging findings and their prognostic role and effect on outcome. *Radiology*. 2005; 237: 597-604.
6. Chou R, Qaseem A, Owens DK, Shekelle P. Diagnostic Imaging for Low Back Pain: Advice for High-Value Health Care From the American College of Physicians. *Ann Intern Med*. 2011; 154: 181-189.
7. Spitzer WO, LeBlanc FE, Dupuis M, Abenhaim L, Belanger AY, Bloch R, et al. Scientific approach to the assessment and management of activity-related spinal disorders. A monograph for clinicians. Report of the Quebec Task Force on Spinal Disorders. *Spine*. 1987; 12(7 Suppl): S1-S59.
8. Staiger TO, Paauw DS, Deyo RA, Jarvik JG. Imaging studies for acute low back pain. When and when not to order them. *Postgrad Med*. 1999; 105: 161-162, 165-166, 171-172.
9. Agency for Health Care Policy and Research. Acute low back problems in adults: assessment and treatment. *Clin Pract Guidel Quick Ref Guide Clin*. 1994; (14): iii-iv, 1-25.
10. State of Florida Agency for Health Care Administration. Florida medical practice guidelines for low back pain or injury. Tallahassee, FL: State of Florida Agency for Health Care Administration; 1996.
11. Royal Australasian College of Radiologists. Imaging guidelines. 3rd ed. Melbourne: Royal Australasian College of Radiologists; 1997. p. 164-165.
12. Even-Sapir E, Martin RH, Mitchell MJ, Iles SE, Barnes DC, Clark AJ. Assessment of painful late effects of lumbar spinal fusion with SPECT. *J Nucl Med*. 1994; 35: 416-422.
13. Holder LE, Machin JL, Asdourian PL, Links JM, Sexton CC. Planar and high-resolution SPECT bone imaging in the diagnosis of facet syndrome. *J Nucl Med*. 1995; 36: 37-44.
14. Modic MT, Masaryk T, Boumpfrey F, Goormastic M, Bell G. Lumbar herniated disk disease and canal stenosis: prospective evaluation by surface coil MR, CT, and myelography. *AJR Am J Roentgenol*. 1986; 147: 757-765.
15. Jackson RP, Cain JE, Jacobs RR, Cooper BR, McManus GE. The neuroradiographic diagnosis of lumbar herniated nucleus pulposus: II. A comparison of CT, myelography, CT-myelography and magnetic resonance imaging. *Spine*. 1989; 14: 1362-1367.
16. Williams AL, Gornet MF, Burkus JK. CT evaluation of lumbar interbody fusion: current concepts. *AJNR Am J Neuroradiol*. 2005; 26: 2057-2066.
17. Jackson RP, Cain JE, Jacobs RR, Cooper BR, McManus GE. The neuroradiographic diagnosis of lumbar herniated nucleus pulposus: II. A comparison of computed tomography (CT), myelography, CT-myelography, and magnetic resonance imaging. *Spine*. 1989; 14:1362-1367.
18. Kent DL, Haynor DR, Larson EB, Deyo RA. Diagnosis of lumbar spinal stenosis in adults: a metaanalysis of the accuracy of CT, MR, and myelography. *AJR Am J Roentgenol*. 1992; 158: 1135-1144.
19. Modic MT, Masaryk T, Boumpfrey F, Goormastic M, Bell G. Lumbar herniated disk disease and canal stenosis: prospective evaluation by surface coil MR, CT, and myelography. *AJR Am J Roentgenol*. 1986; 147: 757-765.
20. Shafaei FF, Wippold FJ, 2nd, Gado M, Pilgram TK, Riew KD. Comparison of computed tomography myelography and magnetic resonance imaging in the evaluation of cervical spondylotic myelopathy and radiculopathy. *Spine*. 1999; 24: 1781-1785.
21. Grossman ZD, Katz DS, Santelli ED, Math KR, Wasenko JJ. Cost-effective diagnostic imaging—the clinician's guide. 3rd ed. St. Louis: Mosby Year Book; 1995. p. 311-319.

Thyroid Imaging



Hong Kong College of Radiologists

TI 1 Thyrotoxicosis



REMARKS

1 Biochemical evaluation

- 1.1 Serum thyroid stimulating hormone (TSH) measurement has the highest sensitivity and specificity in the biochemical evaluation of suspected hyperthyroidism and should be used as an initial screening test. Diagnostic accuracy improves when both a serum TSH and free T4 / total T3 are assessed at the time of the initial evaluation.
- 1.2 Biochemically thyrotoxic:
 - 1.2.1 Suppressed / undetectable serum TSH
 - 1.2.2 Excess serum free T4 / total T3
- 1.3 Subclinical hyperthyroidism:
 - 1.3.1 Low serum TSH
 - 1.3.2 Normal serum free T4 / total T3
- 1.4 Autoantibody tests may be useful to differentiate the causes of hyperthyroidism:
 - 1.4.1 Anti-thyroid peroxidase (anti-TPO) antibody:
 - 1.4.1.1 Elevated in Graves' disease
 - 1.4.1.2 Low/absent in toxic multinodular goiter and toxic adenoma
 - 1.4.2 Thyroid stimulating immunoglobulin (TSI):
 - 1.4.2.1 Elevated in Graves' disease

2 Nuclear medicine (thyroid scintigraphy)

- 2.1 Thyroid scintigraphy facilitates the detection of focal and/or global abnormalities of thyroid gland, correlation of anatomy with function, and detection of aberrant or metastatic functioning thyroid tissue or residual normal tissue after therapy.
- 2.2 Contraindications of thyroid scintigraphy include pregnancy, lactation / breast feeding, recent iodine exposure.
- 2.3 Diagnostic accuracy of thyroid scan using Tc-99m pertechnetate is comparable to that using I-123 in patients with hyperthyroidism and is much cheaper and more widely available.
- 2.4 Thyroid cancer occurs in Graves' disease with an incidence of about 2%. Thyroid nodules larger than 1-1.5 cm should be evaluated before radioactive iodine (RAI) therapy. If a RAI scan is performed, any non-functioning or hypofunctioning nodules should be evaluated with fine needle aspiration (FNA) because they may be malignant.

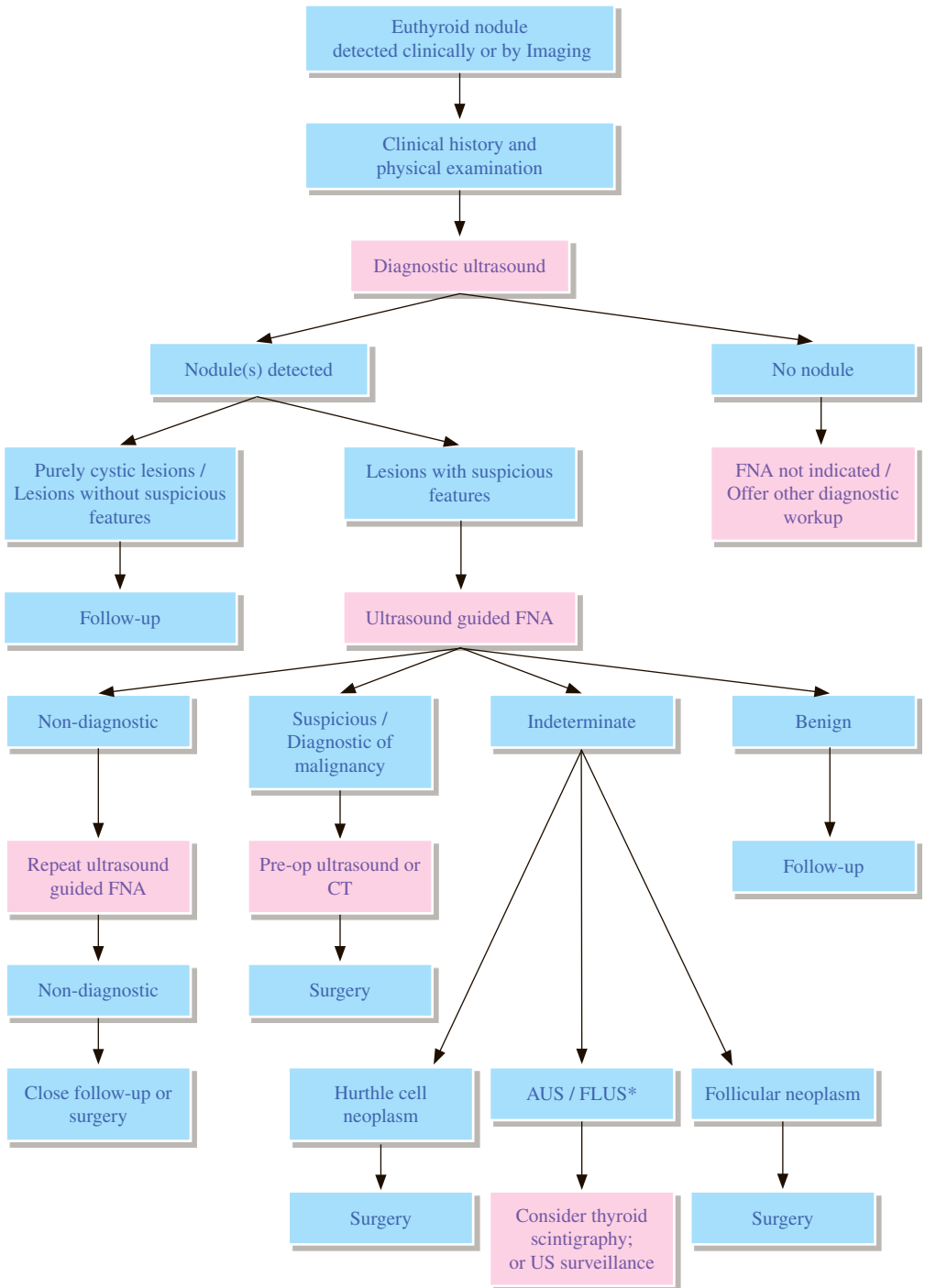
3 US

- 3.1 US can assess the size, texture and vascularity of the thyroid gland and evaluate the sonographic features of non-palpable nodules.
- 3.2 US guided FNA or biopsy can be performed for nodules with suspicious features.

REFERENCES

1. Bahn RS, Burch HB, Cooper DS, Garber JR, Greenlee MC, Klein I, et al. American Thyroid Association, American Association of Clinical Endocrinologists. Hyperthyroidism and other causes of thyrotoxicosis: management guidelines of the American Thyroid Association and American Association of Clinical Endocrinologists. *Thyroid*. 2011; 21: 593-646.
2. Cooper DS, Doherty GM, Haugen BR, Kloos RT, Lee SL, Mandel SJ, et al. Revised American Thyroid Association management guidelines for patients with thyroid nodules and differentiated thyroid cancer. *Thyroid*. 2009; 19: 1167-1214.
3. Gharib H, Papini E, Paschke R, Duick DS, Valcavi R, Hegedüs L, et al; AACE/AME/ETA Task Force on Thyroid Nodules. American Association of Clinical Endocrinologists, Associazione Medici Endocrinologi, and European Thyroid Association Medical Guidelines for clinical practice for the diagnosis and management of thyroid nodules. *Endocr Pract*. 2010; 16: 468-475.
4. The Royal College of Radiologists. *iRefer: Making the best use of clinical radiology*. 7th ed. London: The Royal College of Radiologists, 2012. Section E05.
5. Stocker DJ, Burch HB. Thyroid cancer yield in patients with Graves' disease. *Minerva Endocrinol*. 2003; 28: 205-212.
6. Abraham-Nordling M, Topping O, Hamberger B, Lundell G, Tallstedt L, Calissendorff J, et al. Graves' disease: a long-term quality-of-life follow up of patients randomized to treatment with antithyroid drugs, radiiodine, or surgery. *Thyroid*. 2005; 15: 1279-1286.
7. American College of Radiology. *ACR-SPR Practice Parameter For The Performance Of Scintigraphy And Uptake Measurements For Benign And Malignant Thyroid Disease*. Revised 2014 (Resolution 33). Reston: American College of Radiology; 2014.
8. Ross DS, Burch HB, Cooper DS, Greenlee MC, Laurburg P, Maia AL, et al. 2016 American thyroid association guidelines for diagnosis and management of hyperthyroidism and other causes of thyrotoxicosis. *Thyroid*. 2016; 26: 1343-1421.
9. Verburg FA, Aktolun C, Chiti A, Frangos S, Giovanella L, Hoffmann M, et al. Why the European Association of Nuclear Medicine has declined to endorse the 2015 American Thyroid Association management guidelines for adult patients with thyroid nodules and differentiated thyroid cancer. *Eur J Nucl Med Mol Imaging*. 2016; 43: 1001-1005.

TI 2 Euthyroid nodule



*AUS: atypia of undetermined significance; FLUS: follicular lesion of undetermined significance

REMARKS

1 Clinical history

- 1.1 Underlying high-risk factors for thyroid cancer should be sought from clinical history:
 - 1.1.1 Family history of thyroid cancer
 - 1.1.2 Personal history of thyroid cancer with surgery done
 - 1.1.3 Previous external beam irradiation to the neck
 - 1.1.4 Exposure to ionizing radiation in childhood
 - 1.1.5 Thyroid nodule is F-18 FDG PET positive

2 US

- 2.1 US can confirm the presence of a thyroid nodule and assess the size, location and sonographic features of the lesion. It can also provide information on the number of nodules, and characterize nodules based on their solid and / or cystic constituents.
- 2.2 US can detect non-palpable nodules, extra-thyroidal lesions and associated cervical lymphadenopathy if present.
- 2.3 Fine needle aspiration (FNA) or biopsy of nodules with suspicious features can be performed using US guidance with good accuracy.
- 2.4 Suspicious sonographic features of thyroid nodules include:
 - 2.4.1 Presence of microcalcifications
 - 2.4.2 Marked hypoechogenicity compared to the normal thyroid parenchyma
 - 2.4.3 Increased intra-nodular vascularity
 - 2.4.4 Irregular infiltrative margins
 - 2.4.5 Taller than wide configuration on transverse scan
 - 2.4.6 Disrupted rim calcifications with extruding soft tissue component
 - 2.4.7 Associated cervical lymphadenopathy

3 Nuclear medicine

- 3.1 Thyroid scintigraphy provides functional information about the thyroid nodules. Non-functioning or hypofunctioning nodules are associated with increased likelihood of malignancy and should be considered for US correlation. FNA is suggested for those with suspicious sonographic features. Tc-99m pertechnetate is the most commonly used tracer.
- 3.2 In follicular lesions at FNA cytologic evaluation, thyroid scintigraphy is able to identify a functioning nodule that may be benign; however, most such nodules are cold on scintigraphy.

4 CT

4.1 CT can provide better as well as additional anatomical information about the thyroid nodules prior to operation, including:

4.1.1 Retrosternal extension

4.1.2 Invasion of adjacent structures

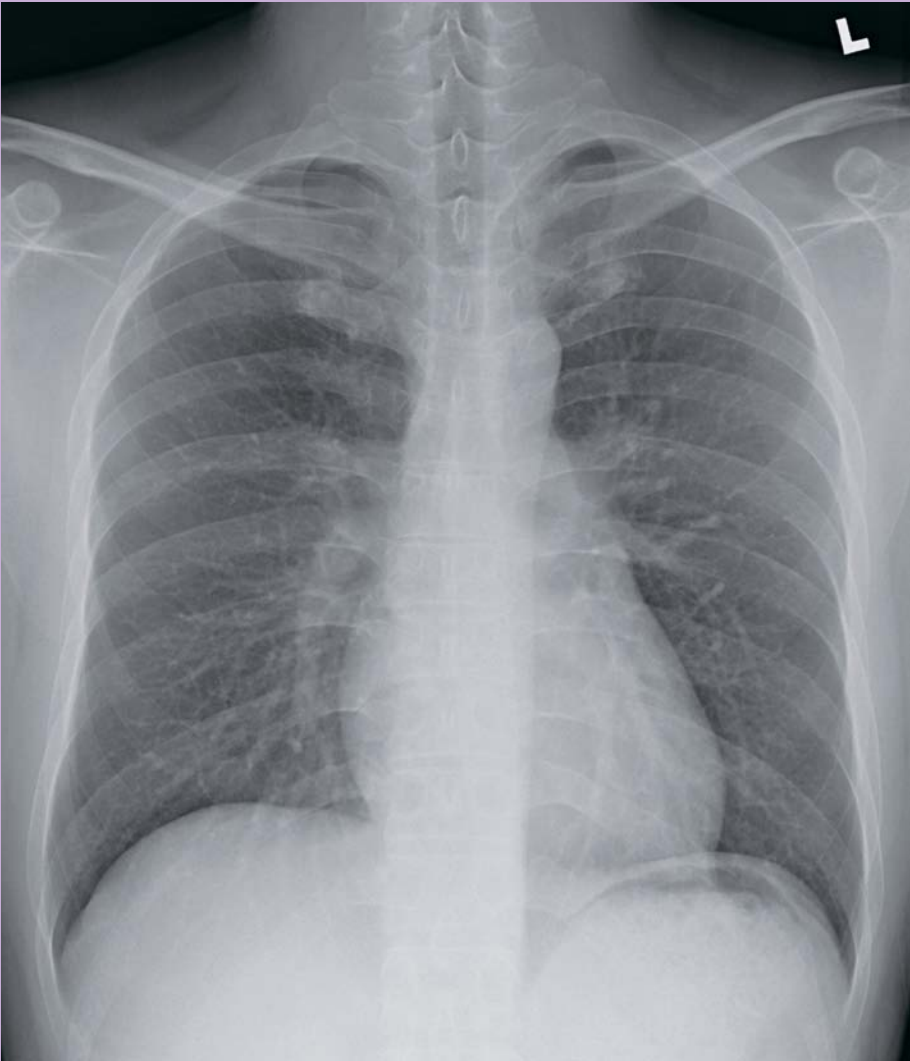4.1.3 Tracheal compression

4.1.4 Lymph node metastasis

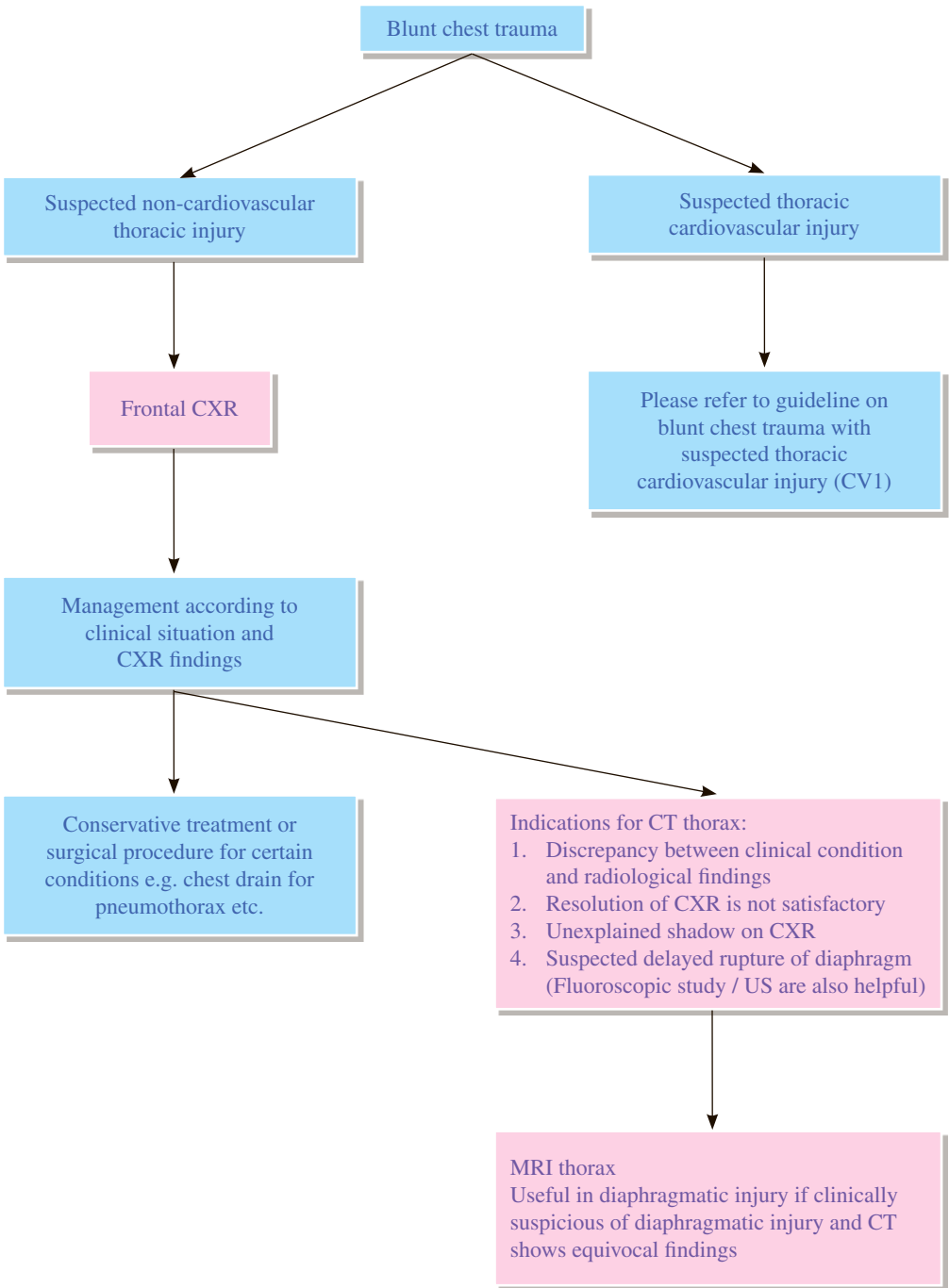
REFERENCES

- 1 Haugen BR, Alexander EK, Bible KC, Doherty GM, Mandel SJ, Nikiforov YE et al. 2015 American Thyroid Association Management Guidelines for Adult Patients with Thyroid Nodules and Differentiated Thyroid Cancer. *Thyroid*. 2016; 26: 1-133.
- 2 Gharib H, Papini E, Garber JR, Duick DS, Harrell RM, Hegedus L, et al. American Association of Clinical Endocrinologists, American College of Endocrinology, and Associazione Medici Endocrinologi medical guidelines for clinical practice for the diagnosis and management of thyroid nodules—2016 update: appendix. *Endocr Pract*. 2016; 22(suppl 1): 1-60.
- 3 British Thyroid Association, Royal College of Physicians. Guidelines for the management of thyroid cancer. Report of the Thyroid Cancer Guidelines Update Group. London: Royal College of Physicians; 2007.
- 4 The Royal College of Radiologists. *iRefer: Making the best use of clinical radiology*. 7th ed. London: The Royal College of Radiologists; 2012. Section E04.
- 5 Marqusee E, Benson CB, Frates MC, Doubilet PM, Larsen PR, Cibas ES, Mandel SJ. Usefulness of ultrasonography in the management of nodular thyroid disease. *Ann Intern Med*. 2000; 133: 696-700.
- 6 Alexander EK, Heering JP, Benson CB, Frates MC, Doubilet PM, Cibas ES, Marqusee E. Assessment of nondiagnostic ultrasound-guided fine needle aspiration of thyroid nodules. *J Clin Endocrinol Metab*. 2002; 87: 4924-4927.
- 7 Cappelli C, Castellano M, Pirola I, Cumetti D, Agosti B, Gandossi E, Agabiti Rosei E. The predictive value of ultrasound findings in the management of thyroid nodules. *QJM*. 2007; 100: 29-35.
- 8 Moon WJ, Jung SL, Lee JH, Na DG, Baek JH, Lee YH, Kim J, Kim HS, Byun JS, Lee DH; Thyroid Study Group, Korean Society of Neuro- and Head and Neck Radiology. Benign and malignant thyroid nodules: US differentiation—multicenter retrospective study. *Radiology*. 2008; 247: 762-770.
- 9 Gharib H, Papini E, Paschke R, Duick DS, Valcavi R, Hegedus L, Vitti P; AACE/AME/ETA Task Force on Thyroid Nodules. American Association of Clinical Endocrinologists, Associazione Medici Endocrinologi, and European Thyroid Association Medical Guidelines for clinical practice for the diagnosis and management of thyroid nodules. *Endocr Pract*. 2010; 16: 468-475.

Chest Radiology



Hong Kong College of Radiologists



REMARKS

1 General

- 1.1 Clinical and radiological signs of significant lung injury are often absent on the initial evaluation. This is especially true for lung contusion for which the signs evolves over a period of 2 to 3 days.
- 1.2 There is no consistent relationship between evidence of external chest wall injury (either clinical or radiological signs) and the likelihood of serious underlying lung injury. This principle is especially important to remember when dealing with children, who because of their highly elastic chest walls can have serious lung injury even when there is no external sign of injury.
- 1.3 Radiographic studies greatly underestimate the true extent of lung and chest wall injury.

2 Plain radiograph

- 2.1 Chest X-ray (CXR) is the primary bedside imaging modality to evaluate the chest in post-traumatic patients.
- 2.2 CXR should preferably be taken in the erect posterior-anterior (PA) view. In case of major trauma, only supine anterior-posterior (AP) view may be possible.
- 2.3 Strict adherence to high standards of radiographic technique with respect to exposure factors, patient positioning and ventilation cycle is needed in order to obtain useful images.

3 CT

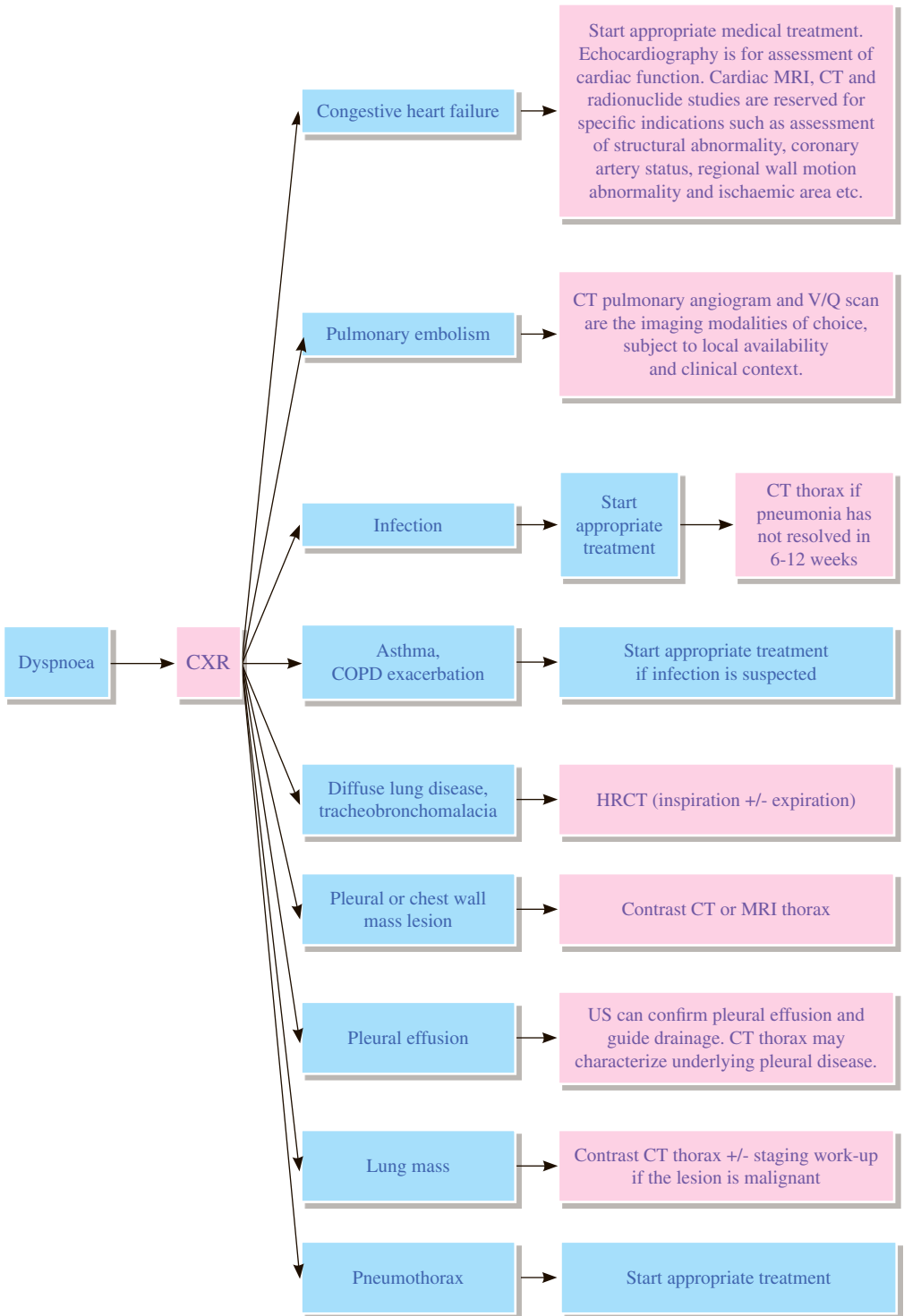
- 3.1 CT is the most sensitive and accurate imaging modality to evaluate the post-traumatic abdomen and chest.
- 3.2 CT is superior to CXR in imaging the chest wall, pulmonary parenchyma and mediastinum.
- 3.3 CT should be performed only if the patient's clinical condition is stable.

4 MRI

- 4.1 It is useful in assessing diaphragmatic integrity if there is clinical suspicion of diaphragmatic injury and CT shows equivocal findings.
- 4.2 MRI is most useful as a problem-solving tool and not as part of a standard trauma protocol, except in rare instances of significant thoracic spinal injury.

REFERENCES

1. Chung JH, Cox CW, Mohammed TH, et al. ACR Appropriateness Criteria® Blunt Chest Trauma. Available at <https://acsearch.acr.org/docs/3082590/Narrative/>. American College of Radiology. Accessed 2017 April 19.
2. Kaewlai R, Avery LL, Asrani AV, Novelline RA. Multidetector CT of Blunt Thoracic Trauma. *Radiographics*. 2008; 28: 1555-1570.
3. Zinck SE, Primack SL. Radiographic and CT Findings in Blunt Chest Trauma. *J Thorac Imaging*. 2000; 15: 87-96.



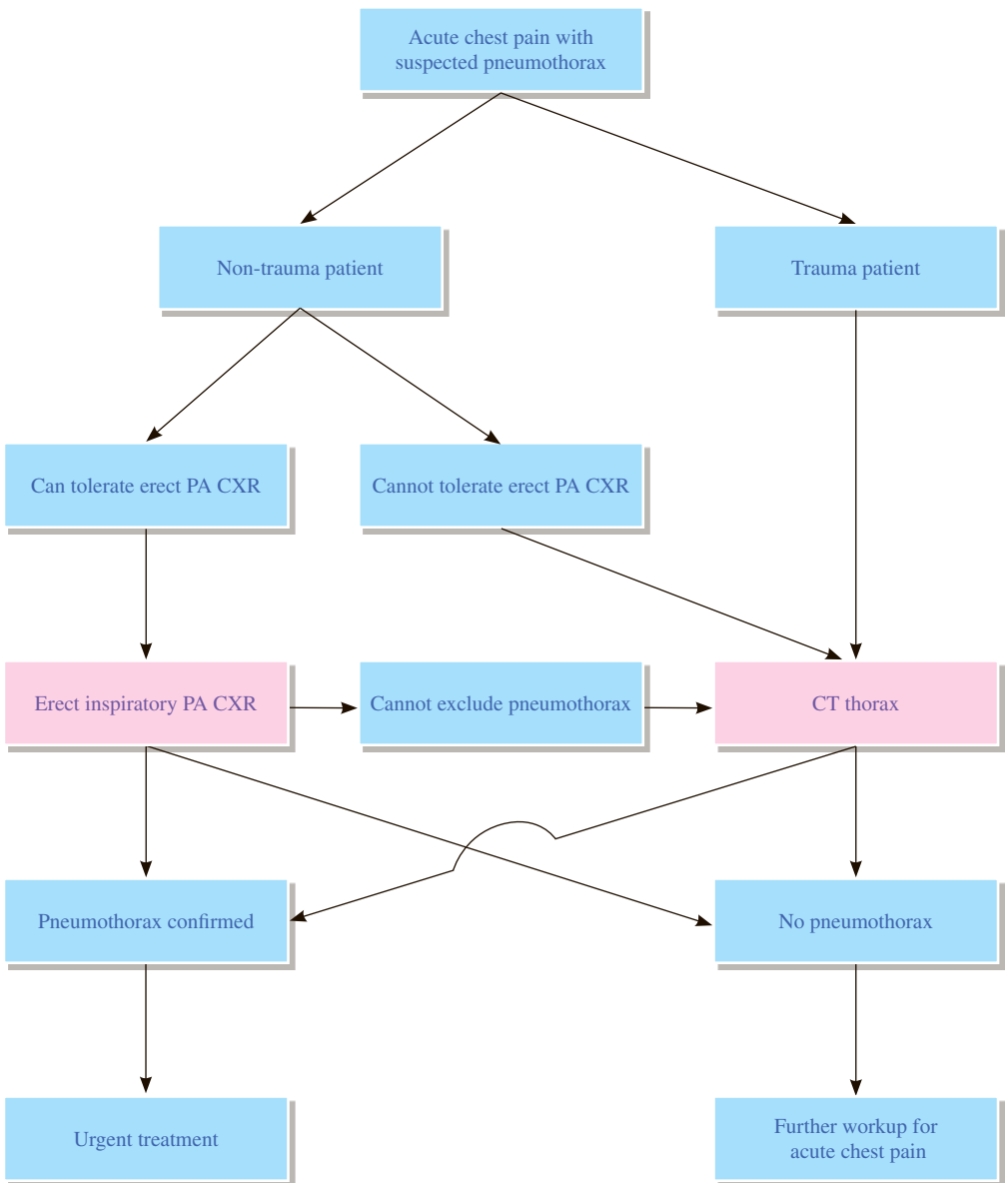
REMARKS

- 1 Dyspnoea can be broadly classified into cardiac or pulmonary origins.
- 2 Chest X-ray (CXR) usually forms part of the initial workup for patients presenting with dyspnoea.
- 3 In two-thirds of the cases, CXR can help to make a diagnosis.
- 4 For patients with asthma or chronic obstructive pulmonary disease (COPD) exacerbation, a CXR is only needed under specific circumstances, e.g. when infection is suspected or if the condition does not respond to treatment.
- 5 High resolution CT (HRCT) is useful for diffuse lung disease, for example, interstitial lung disease, bronchiectasis, pneumoconiosis, sarcoidosis and emphysema. Expiratory HRCT can detect air trapping and tracheobronchomalacia.
- 6 Contrast CT thorax is needed when there is persistent consolidation, suspicion of pulmonary embolism, pulmonary or extrapulmonary mass.
- 7 MRI is usually reserved for evaluation of pleural disease or patients with chest wall mass.

REFERENCES

1. Vogel-Claussen J, Elshafee ASM, Kirsch J, et al. ACR Appropriateness Criteria® Dyspnea – Suspected Cardiac Origin. Available at <https://acsearch.acr.org/docs/69407/Narrative/>. American College of Radiology. Accessed 2017 Jun 25.
2. Dyer DS, Mohammed TH, Kirsch J, et al. ACR Appropriateness Criteria® Chronic Dyspnea – Suspected Pulmonary Origin. Available at <https://acsearch.acr.org/docs/69448/Narrative/>. American College of Radiology. Accessed 2017 Jun 25.
3. Mukhopadhyay A, Lim TK. A prospective audit of referrals for breathlessness in patients hospitalized for other reasons. *Singapore Med J*. 2005; 46: 21-24.
4. The Royal College of Radiologists. *iRefer: Making the best use of clinical radiology*. 8th ed. London: The Royal College of Radiologists; 2017. Sections CC04, CC20, CC21, CC23, CC24, CC26.

CH 3 Acute chest pain with suspected pneumothorax



REMARKS

1 Plain radiograph

- 1.1 Posterior-anterior (PA) erect chest X-ray (CXR) in inspiration is recommended for the initial evaluation of suspected pneumothorax. In uncertain cases, such as in the presence of bullous lung disease, CT is preferred.
- 1.2 Lateral chest radiograph may provide additional information when a suspected pneumothorax is not confirmed on PA CXR but this is not routinely performed in everyday clinical practice.
- 1.3 Expiratory CXR is not thought to confer additional benefit in the routine assessment of pneumothorax.
- 1.4 Supine and lateral decubitus chest radiographs are mostly performed for trauma patients who cannot be safely positioned for erect PA view but these have been superseded by CT.

2 US

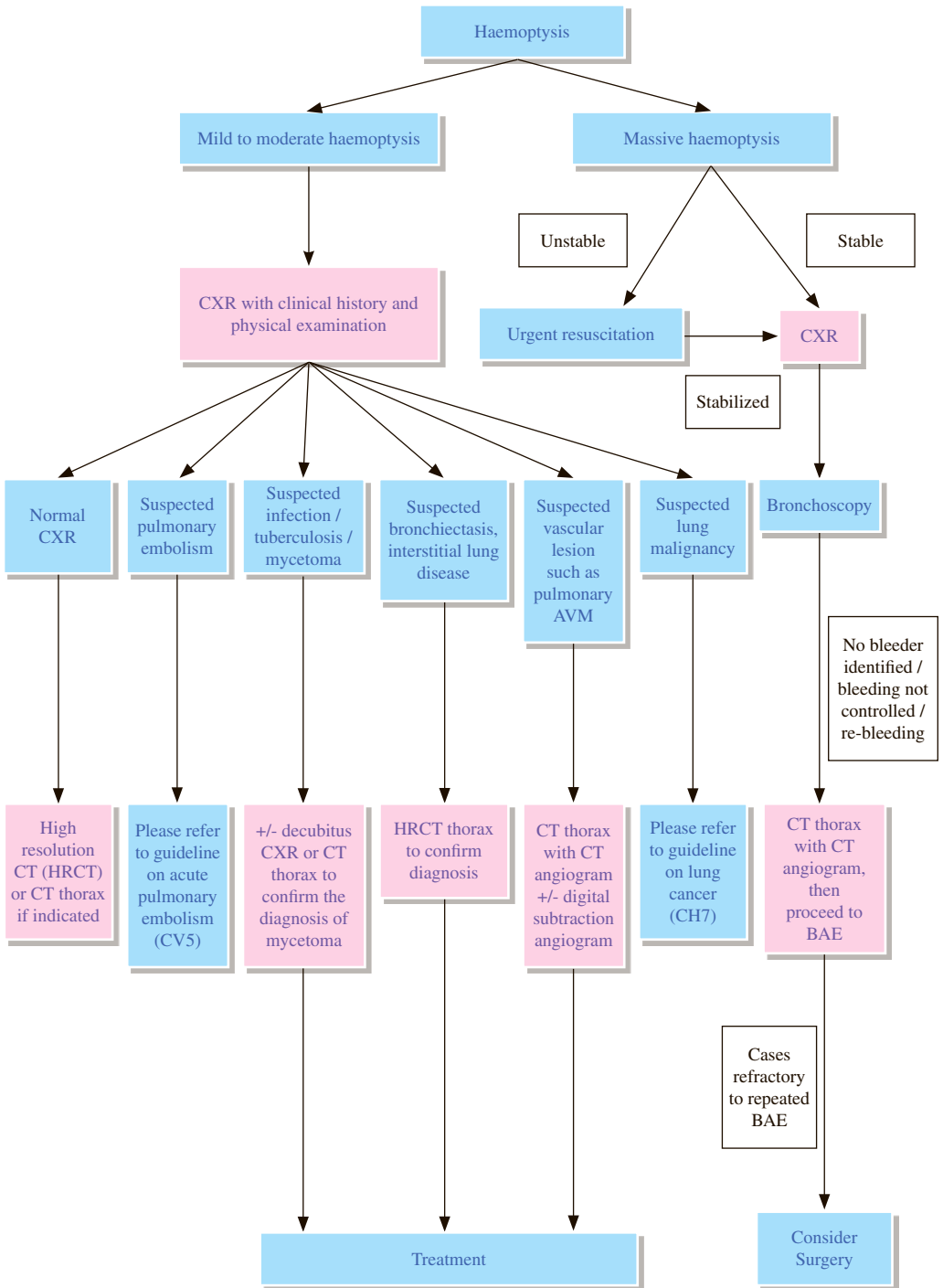
- 2.1 US only plays a subsidiary role in diagnosing pneumothorax and its efficacy highly depends on operator experience. US thus should not be a routine investigation.

3 CT

- 3.1 CT is the gold standard for detection of small pneumothoraces and for size estimation, and is recommended for uncertain or complex cases. It is also useful in detecting pneumothorax in the presence of bullous lung disease or surgical emphysema, and can also identify aberrant chest drain placement and other concomitant lung pathology.

REFERENCES

1. MacDuff A, Arnold A, Harvey J; BTS Pleural Disease Guideline Group. Management of spontaneous pneumothorax: British Thoracic Society Pleural Disease Guideline 2010. *Thorax*. 2010; 65 Suppl 2: ii18-31.
2. Glazer HS, Anderson DJ, Wilson BS, Molina PL, Sagel SS. Pneumothorax: appearances on lateral chest radiographs. *Radiology*. 1989; 173: 707-711.
3. Zhang H, Liu ZH, Yang JX, Gan JX, Xu SW, You XD, et al. Rapid detection of pneumothorax by ultrasonography in patients with multiple trauma. *Crit Care*. 2006; 10: R112.
4. Beres RA, Goodman LR. Pneumothorax: detection with upright versus decubitus radiography. *Radiology*. 1993; 186: 19-26.
5. Kelly AM, Weldon D, Tsang AY, Graham CA. Comparison between two methods for estimating pneumothorax size from chest x-rays. *Respir Med*. 2006; 100: 1356-1359.



REMARKS

1 General

- 1.1 Haemoptysis is defined as the expectoration of blood that originates from the tracheobronchial tree or pulmonary parenchyma. The majority of cases are benign and are self-limiting episodes. However, its underlying aetiology must be evaluated. Common aetiologies include bronchitis, bronchiectasis, pneumonia, tuberculosis and malignancy.
- 1.2 The definition of massive haemoptysis varies in literature from 100 – 1000ml over 24 hours but the more widely used figure is expectoration of 300 – 600ml of blood over 24 hours. The source of bleeding is usually from erosion of systemic rather than pulmonary arteries. Notable exceptions are arteriovenous malformations (AVM) and pulmonary artery aneurysms. Bronchial artery embolization (BAE) has been shown to be an effective treatment to control massive haemoptysis. Most authors reserve surgery for cases refractory to repeated BAE.
- 1.3 The imaging modalities pertinent to the evaluation of non-massive haemoptysis include chest X-ray (CXR) and CT thorax.

2 Plain radiograph

- 2.1 CXR is efficacious in the initial evaluation.

3 CT and CT angiography

- 3.1 Contrast-enhanced CT is useful for localizing the bleeding site and diagnosing the underlying cause.
- 3.2 CT angiogram performed with MDCT allows non-invasive, rapid and detailed assessment of lung and thoracic vasculature. It is possible to delineate abnormal bronchial and non-bronchial arteries using a variety of reformatted images, which can serve as a roadmap to guide therapeutic embolization procedures. Hence, it should be performed prior to BAE if embolization is anticipated.

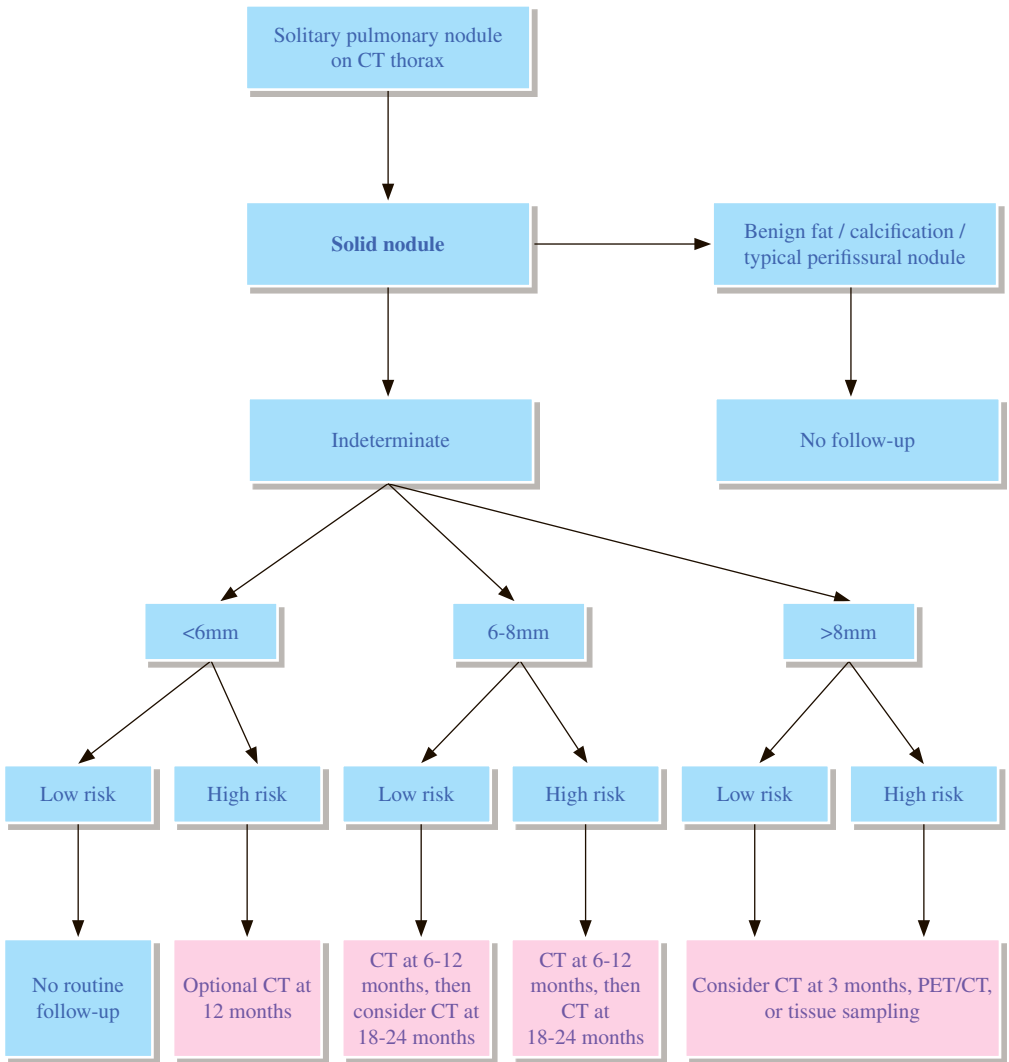
4 Angiography

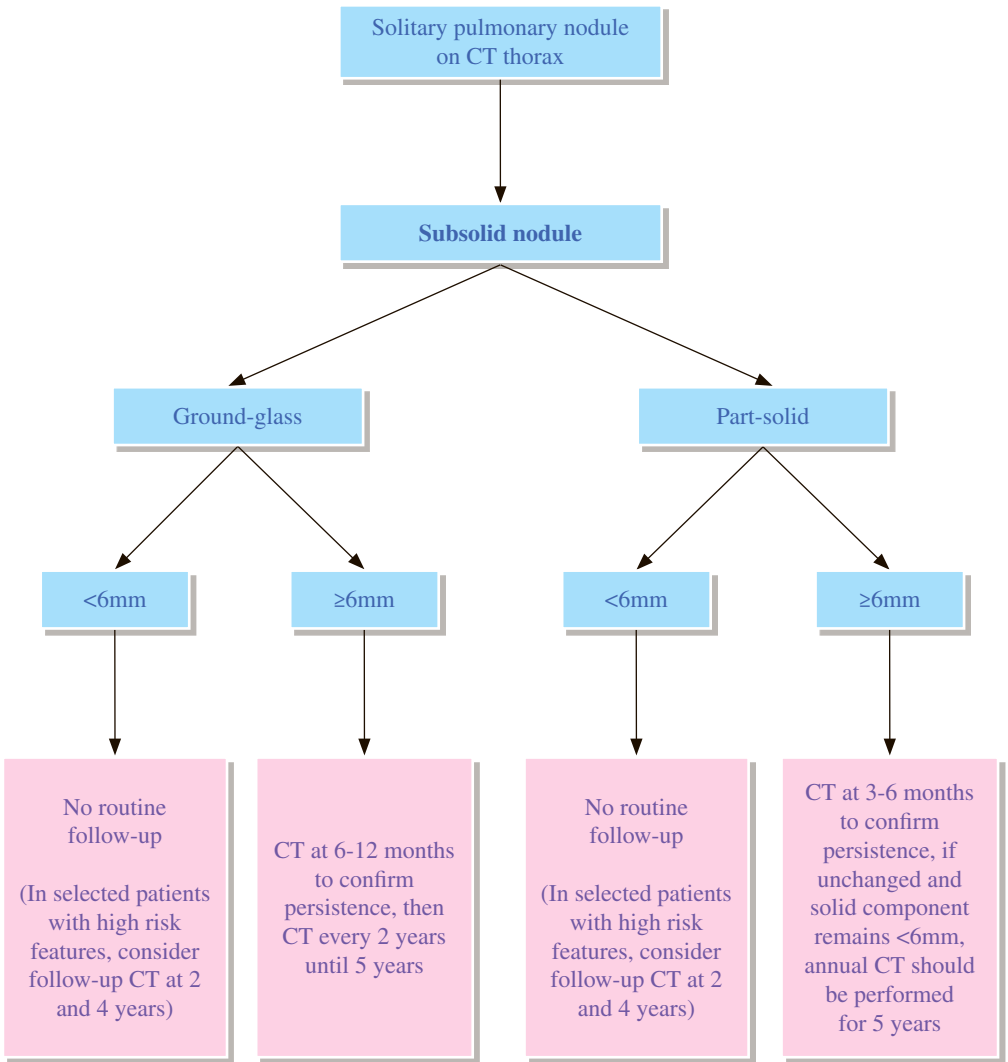
- 4.1 Angiography is performed prior to treatment such as BAE, or for confirming the diagnosis and for the treatment of AVM.
- 4.2 BAE has been proven to be an effective treatment for massive and recurrent hemoptysis, either as first-line treatment or as an adjunct to elective surgery.

REFERENCES

1. NoëGD, JafféSM, MolanMP. CT and CT angiography in massive haemoptysis with emphasis on pre-embolization assessment. *Clin Radiol.* 2011; 66: 869-875.
2. Chun JY, Morgan R, Belli AM. Radiological management of haemoptysis: A comprehensive review of diagnostic imaging and bronchial arterial embolization. *Cardiovas Intervent Radiol.* 2010; 33: 240-250.
3. Haponil EF, Fein A, Chin R. Managing life-threatening haemoptysis: has anything really changed? *Chest.* 2000; 118: 1431-1435.
4. Khalil A, Fartoukh M, Tassart M, Parrot A, Marsault C, Carette MF. Role of MDCT in identification of the bleeding site and the vessels causing haemoptysis. *AJR Am J Roentgenol.* 2007; 188: W117-W125.
5. Bruzzi JF, Remy-Jardin M, Delhaye D, Teisseire A, Khalil C, Remy J. Multi-detector row CT of haemoptysis. *Radiographics.* 2006; 26: 3-22.

CH 5 Solitary pulmonary nodule





REMARKS

1 General

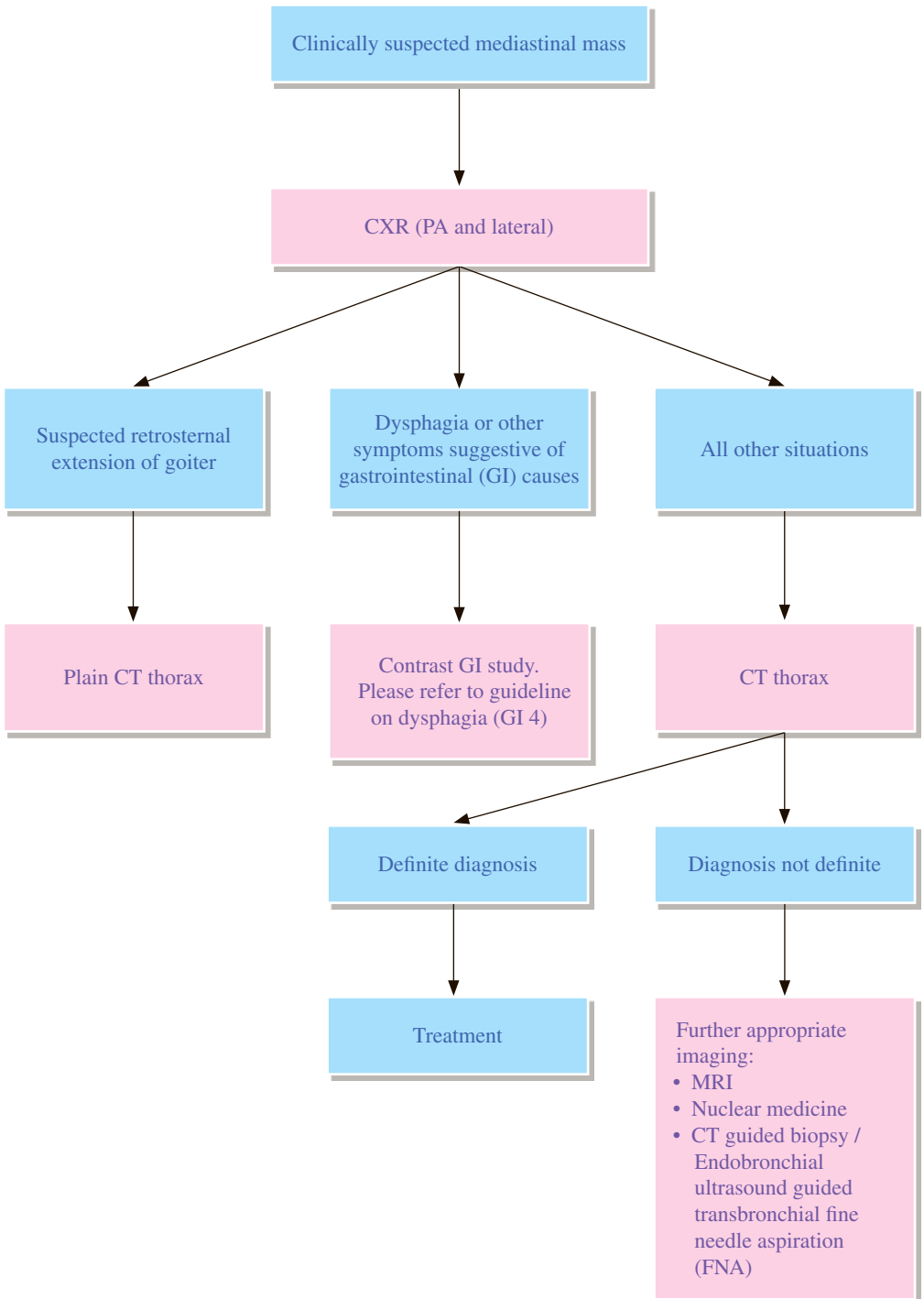
- 1.1 Solitary pulmonary nodule is defined as a relatively spherical opacity of which the diameter is 3cm or smaller. It is completely surrounded by lung with no associated atelectasis or hilar adenopathy detected.
- 1.2 These guidelines apply to incidental solitary lung nodule in patients aged 35 or above. They do not apply to patients with known primary cancer, immunosuppression or lung cancer screening.
- 1.3 The minimum threshold size for recommending follow-up is based on an estimated cancer risk in a nodule on the order of 1% or greater.
- 1.4 Estimation of an individual patient's risk of developing lung cancer is multi-factorial, including the size and morphology of lung nodule, history of smoking, exposure to other carcinogens, location of lung nodule, presence of emphysema and fibrosis, family history of lung cancer, ethnic background, age and gender etc. Different risk prediction models are available. In general, high risk factors include older age, heavy smoking, larger nodule size, irregular/spiculated margins, and upper lobe location.

2 CT

- 2.1 Thin section scans are needed to enable accurate characterization and measurement of small lung nodules.
- 2.2 Low-dose thin-slice unenhanced scans are recommended for follow-up of lung nodules.
- 2.3 Measurement of a lung nodule should be based on the average of its long- and short-axis diameters, both of which should be obtained on the same transverse, coronal or sagittal reformatted images. The image which reveals the greatest diameter should be used. The measurement should be rounded to the nearest millimetre.
- 2.4 In practice, it is difficult to reliably define discrete solid components of part-solid nodules <6mm, therefore they are managed in a similar way that pure ground-glass lesions of equivalent size are treated.
- 2.5 Persistent part-solid nodules with solid component ≥ 6 mm should be considered highly suspicious.
- 2.6 Contrary to growth in solid nodules which is based solely on size, in subsolid nodules, growth may manifest as an increase in size, an increase in attenuation, development of a solid component, or an increase in size of a solid component. In subsolid nodules, these imaging features of growth indicate an increased risk for malignancy.
- 2.7 Benign patterns of calcification in solitary lung nodules include dense central calcification, laminated calcification and diffuse calcification.
- 2.8 A typical perifissural nodule is attached to pulmonary fissure, homogenous, solid with smooth margin, and oval/lentiform/triangular in shape. Typical perifissural nodules are likely intrapulmonary lymph nodes.

REFERENCES

1. MacMahon H, Naidich DP, Goo JM, Lee KS, Leung ANC, Mayo JR, et al. Guidelines for Management of Incidental Pulmonary Nodules Detected on CT Images: From the Fleischner Society 2017. *Radiology*. 2017; 284: 228-243.
2. Gould MK, Donington J, Lynch WR, Mazzone PJ, Midthun DE, Naidich DP, et al. Evaluation of Individuals With Pulmonary Nodules: When Is It Lung Cancer? Diagnosis and Management of Lung Cancer, 3rd ed: American College of Chest Physicians Evidence-Based Clinical Practice Guidelines. *Chest*. 2013; 143 (5 Suppl): e93S-e120S.
3. Truong MT, Ko JP, Rossi SE, Rossi I, Viswanathan C, Bruzzi JF, et al. Update in the Evaluation of Solitary Pulmonary Nodule. *Radiographics*. 2014; 34: 1658-1679.
4. de Hoop B, van Ginneken B, Gietema H, Prokop M. Pulmonary perifissural nodules on CT scans: Rapid growth is not a predictor of malignancy. *Radiology*. 2012; 265: 611-616.
5. Webb WR. Radiologic evaluation of the solitary pulmonary nodule. *AJR Am J Roentgenol*. 1990; 154: 701-708.



REMARKS

1 Plain radiograph

- 1.1 Posterior-anterior (PA) and lateral chest radiographs are appropriate initial investigations although the chest films are almost never specific.

2 Nuclear medicine

- 2.1 Choice of nuclear medicine imaging modality depends on clinical suspicion.
- 2.2 Fluorodeoxyglucose (FDG) PET/CT is useful in assessing the metabolic activity of the mediastinal mass, and helpful in characterizing the lesion. It guides subsequent invasive investigations and is helpful in staging malignancy. It is also useful in monitoring treatment response in various malignancies.
- 2.3 Technetium-99m (Tc-99m) pertechnetate thyroid scintigraphy is useful for confirming presence of thyroid tissue if retrosternal goiter is suspected.
- 2.4 FDG PET/CT, Gallium-67 scintigraphy and white blood cell scintigraphy are useful in characterizing an infective mass or abscess in mediastinum.

3 CT

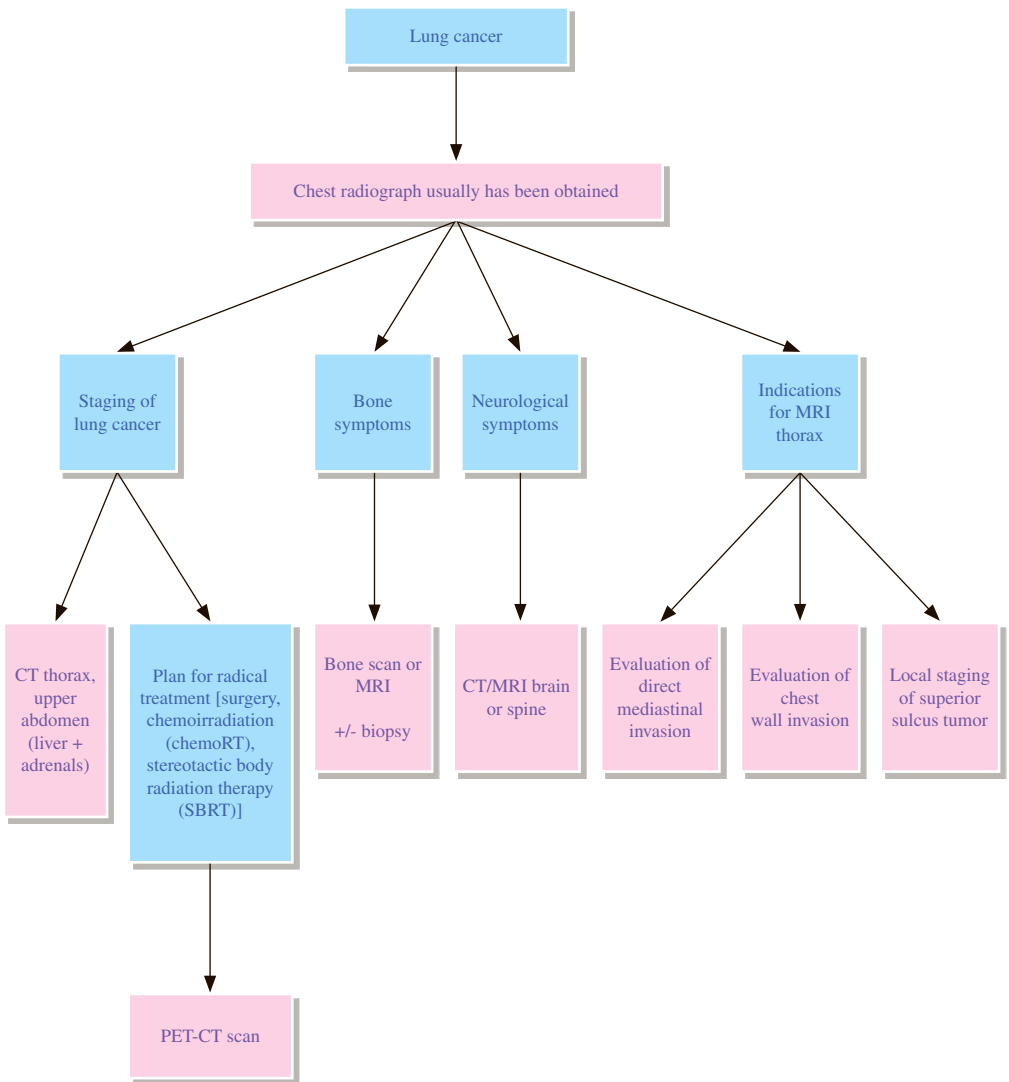
- 3.1 CT is the most versatile and valuable imaging modality for confirming or excluding, localizing and characterizing a mediastinal mass.
- 3.2 CT is usually adequate for diagnosis and further studies are not necessary.
- 3.3 CT also examines the lungs, which is critically important in patients who may have a thoracic neoplasm.
- 3.4 CT is the gold-standard imaging modality for the pre-operative evaluation of patients with retrosternal goiter. CT is essential to define the extent and position of a retrosternal goiter. Iodinated contrast medium should be avoided because it would interfere with subsequent radionuclide imaging.
- 3.5 Often the mass has non-specific characteristics and requires biopsy for definitive diagnosis.

4 MRI

- 4.1 If CT defines a mass but subtle relationships of the mass to the spine and neural foramina need to be evaluated, or if chest wall invasion needs to be evaluated in more detail, MRI would be useful.
- 4.2 MRI is also an appropriate alternative for patients who cannot tolerate the iodinated contrast medium needed for CT, and for children and pregnant women who should avoid exposure to ionizing radiation.

REFERENCES

1. Grossmann Z, Katz D, Alberico R, Loud P. Cost-effective diagnostic imaging - the clinician's guide. 4th ed. Mosby 2006. p. 156-163.
2. Qureishi A, Garas G, Tolley N, Palazzo F, Athanasiou T, Zacharakiz E. Can pre-operative computed tomography predict the need for a thoracic approach for removal of retrosternal goitre? *Int J Surg.* 2013; 11: 203-208.
3. Jr. Ray CE, English B, Funaki BS, Burke CT, Fidelman N, Ginsburg ME, et al. ACR appropriateness criteria® radiologic management of thoracic nodules and masses. *J Am Coll Radiol.* 2012; 9: 13-19.
4. Department of Health, Government of Western Australia. Diagnostic Imaging Pathways – Mediastinal Mass (Suspected). Perth: Department of Health, Government of Western Australia; 2012 January.
5. Yasufuku K, Nakajima T, Fujiwara T, Yoshino I, Keshavjee S. Utility of endobronchial ultrasound-guided transbronchial needle aspiration in the diagnosis of mediastinal masses of unknown etiology. *Ann Thorac Surg.* 2011; 91: 831-836.



REMARKS

1 Plain radiograph

- 1.1 Many primary lung cancers are initially detected on chest radiograph.
- 1.2 In certain instances, the chest radiograph alone is sufficient for staging, e.g. when an obvious metastatic bone lesion is detected or when large bulky contralateral mediastinal lymph nodes are present.
- 1.3 Chest X-ray (CXR) can be used to monitor treatment response if CT is not available.

2 CT

- 2.1 CT is the main imaging modality of choice for evaluating patients with bronchogenic carcinoma.
- 2.2 CT has limitations in staging since there are no morphologic criteria to distinguish between benign and malignant lymph nodes, with low sensitivity and specificity in detecting nodal metastasis.
- 2.3 CT should include the adrenal glands.
- 2.4 CT has limited value in detecting chest wall and mediastinal invasion.

3 Fluorodeoxyglucose (FDG) PET-CT

- 3.1 Whole body FDG PET-CT is the preferred imaging modality for staging of non-small cell lung cancer in patients who are planned to be treated with curative intent.
- 3.2 FDG PET-CT has better sensitivity and specificity than CT alone in identification of nodal metastases with an overall sensitivity of 80–90% and specificity of 85–95%.
- 3.3 FDG PET-CT detects ~24% occult extrathoracic metastases in patients who are initially planned to undergo curative resection.
- 3.4 It decreases the number of futile thoracotomy by an additional 21%.
- 3.5 FDG PET-CT is an excellent tool for monitoring of treatment response.

4 Bone scan

- 4.1 Bone scintigraphy has high sensitivity (93.3%) for detecting osseous metastases.
- 4.2 Routine bone scintigraphy is not warranted, and is only reserved for symptomatic patients or those with biochemical abnormalities.
- 4.3 If whole body FDG PET has already been performed, additional bone scintigraphy is not necessary in most circumstances.

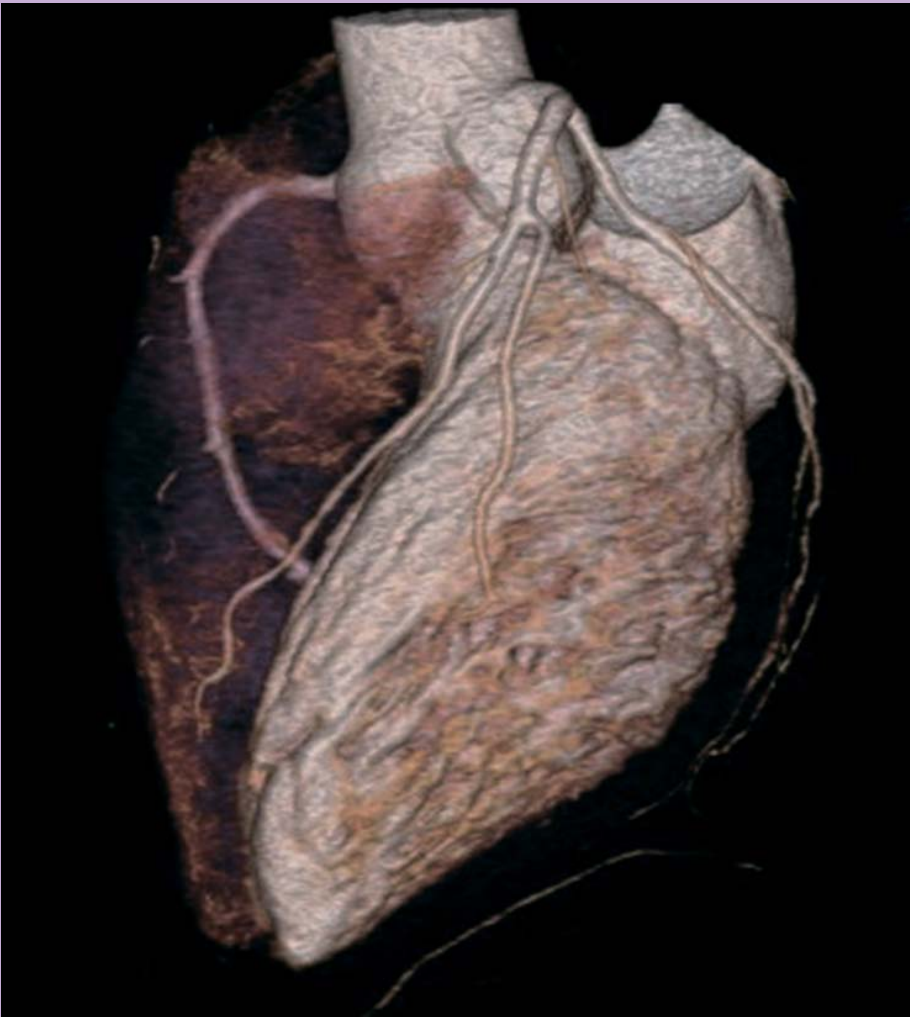5 MRI

- 5.1 MRI is particularly useful in determining certain parameters of unresectability for superior sulcus cancer such as invasion into vertebral body, spinal canal, neural foramina, subclavian artery or brachial plexus.
- 5.2 MRI is useful in assessing chest wall and mediastinal invasion.
- 5.3 Using Cine MRI during free breathing, presence of sliding between the tumor and mediastinum or chest wall has been shown to be diagnostic of lack of invasion; the converse however may not necessarily indicate invasion since adhesion from local inflammatory changes may also restrict tumour motion.

REFERENCES

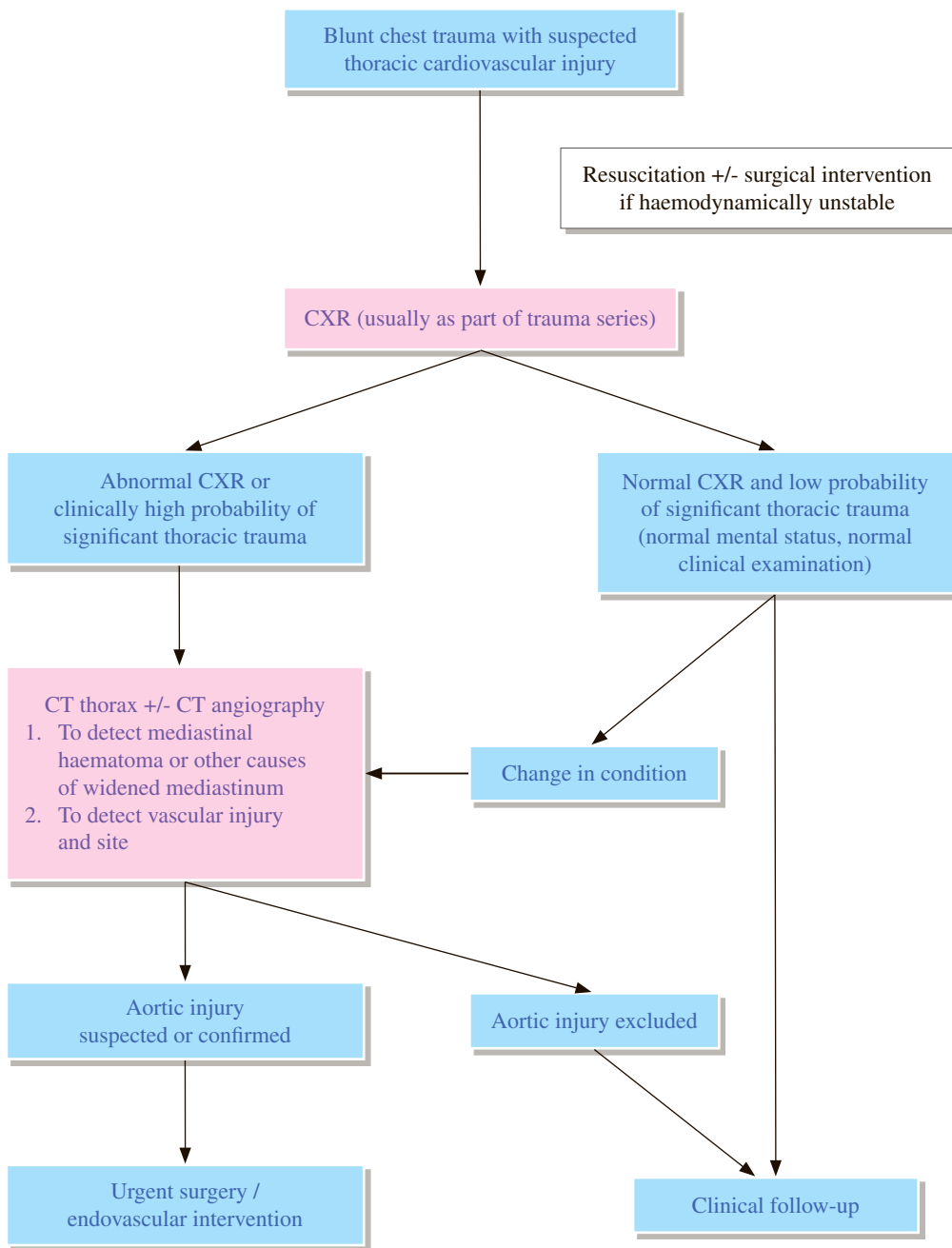
1. Ravenel JG, Mohammed TH, Rosenzweig KE, et al. ACR Appropriateness Criteria® Non-invasive Clinical Staging of Bronchogenic Carcinoma. Available at <https://acsearch.acr.org/docs/69456/Narrative/>. American College of Radiology. Accessed 2017 June 6.
2. Patz EF. Imaging bronchogenic carcinoma. *Chest*. 2000; 117: 90S-95S.
3. Higashino T, Ohno Y, Takenaka D, Watanabe H, Nogami M, Ohnayashi C. Thin-section multiplanar reformats from multidetector-row CT data: utility for assessment of regional tumor extent in non-small cell lung cancer. *Eur J Radiol*. 2005; 56: 48-55.
4. Bruzzi JF, Komaki R, Walsh GL, Truong MT, Gladish GW, Monden RF, et al. Imaging of non-small cell lung cancer of the superior sulcus: part 2: Initial staging and assessment of resectability and therapeutic response. *Radiographics*. 2008; 28: 561-572.
5. National Institute for Health and Clinical Excellence (2011) Lung cancer: diagnosis and management. NICE guideline (CG121).
6. De Leyn P, Dooms C, Kuzdzal J, Lardinois D, Passlick B, Rami-Porta R, et al. Revised ESTS guidelines for preoperative mediastinal lymph node staging for non-small-cell lung cancer. *Eur J Cardiothorac Surg*. 2014; 45: 787-798.
7. Darling GE, Maziak DE, Inculet RI, Gulenchyn KY, Driedger AA, Ung YC, et al. Positron emission tomography-computed tomography compared with invasive mediastinal staging in non-small cell lung cancer: results of mediastinal staging in the early lung positron emission tomography trial. *J Thorac Oncol*. 2011; 6: 1367-1372.
8. Macmanus MP, Hicks RJ, Matthews JP, Hogg A, McKenzie AF, Wirth A, et al. High rate of detection of unsuspected distant metastases by pet in apparent stage III non-small-cell lung cancer: implications for radical radiation therapy. *Int J Radiat Oncol Biol Phys*. 2001; 50: 287-293.
9. Spira A, Ettinger DS. Multidisciplinary Management of Lung Cancer. *N Engl J Med*. 2004; 350: 379-392.
10. vanTinteren H, Hoekstra OS, Smit EF, van den Bergh JH, Schreurs AJ, Stallaert RA, et al. Effectiveness of positron emission tomography in the preoperative assessment of patients with suspected non-small-cell lung cancer: the PLUS multicenter randomised trial. *Lancet*. 2002; 359: 1388-1393.
11. Pottgen C, Levegrun S, Theegarten D, Marnitz S, Grehl S, Pink R, et al. Value of 18F-fluoro-2-deoxy-D-glucose-positron emission tomography/computed tomography in non-small-cell lung cancer for prediction of pathologic response and times to relapse after neoadjuvant chemoradiotherapy. *Clin Cancer Res*. 2006; 12: 97-106.
12. Min JW, Um SW, Yim JJ, Yoo CG, Han SK, Shim YS, et al. The Role of Whole-Body FDG PET/CT, Tc 99m MDP Bone Scintigraphy, and Serum Alkaline Phosphatase in Detecting Bone Metastasis in Patients with Newly Diagnosed Lung Cancer. *J Korean Med Sci*. 2009; 24: 275-280.

Cardiovascular Radiology



Hong Kong College of Radiologists

CV 1 Blunt chest trauma with suspected thoracic cardiovascular injury



REMARKS

1 Plain radiograph

- 1.1 Remains the primary screening modality despite the advent of newer imaging modalities.
- 1.2 7 – 11% of patients with aortic rupture have an initial normal chest X-ray (CXR).
- 1.3 Most common finding on CXR is widening of mediastinum (90% sensitivity but only 10% specificity for aortic injury).
- 1.4 Radiographic signs of blunt thoracic aortic injury:
 - 1.4.1 Widened mediastinum (defined as transverse dimension \geq 8cm from the left side of the aortic arch to the right margin of the mediastinum or mediastinum to chest-width ratio \geq 25%)
 - 1.4.2 Loss of the aortopulmonary window or loss of definition of the descending thoracic aorta
 - 1.4.3 Widened right paratracheal stripe or paraspinal stripe
 - 1.4.4 Tracheal shift to the right of the T4 spinous process
 - 1.4.5 Left main stem bronchus depression
 - 1.4.6 Nasogastric tube displaced to the right
 - 1.4.7 Left apical pleural cap sign

2 CT and CT angiography

- 2.1 CT has become the reference-standard imaging study for the diagnosis of blunt traumatic aortic injury and has almost completely replaced catheter aortography and transoesophageal echocardiogram (TOE).
- 2.2 CT angiogram (CTA) has high sensitivity and specificity in detection of blunt thoracic aortic injury.
- 2.3 When initial trauma survey and mechanism of injury suggest a low probability of significant thoracic trauma (normal mental status, normal clinical examination and normal CXR), further assessment with chest CT thorax or CTA may not be necessary.
- 2.4 Routine use of CT thorax should be strongly considered in patients with high energy mechanism of injuries, abnormal CXR, altered mental status, distracting injuries, or clinically suspected thoracic aortic injuries.

3 Echocardiogram

- 3.1 Transthoracic echocardiogram (TTE) is helpful in suspected cardiac injury and excluding cardiac rupture and acute valvular injury.
- 3.2 TOE is more sensitive than TTE but more invasive and usually requires sedation, therefore it is rarely used as an initial evaluation.
- 3.3 Limitations include lack availability of cardiologists skilled in performing TEE in the emergency setting; blind spots in distal ascending aorta/arch vessels.

4 MRI

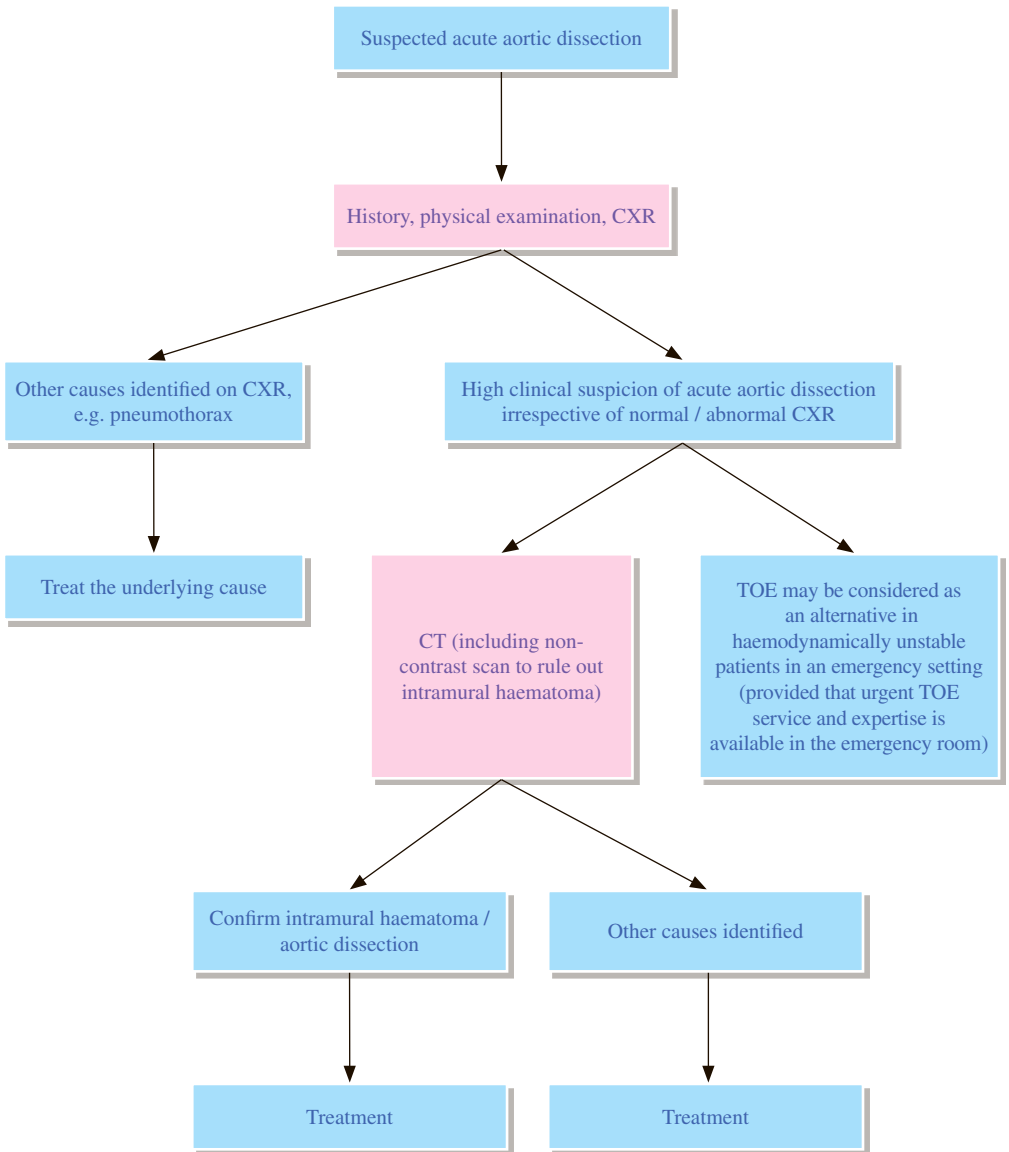
- 4.1 MRI does not have a role in initial evaluation of critically ill, haemodynamically unstable patients.

5 Catheter angiography

- 5.1 Gold standard in evaluating injury to the aorta and its main branches.
- 5.2 Now largely replaced by CTA for initial assessment and reserved mainly for endovascular intervention in confirmed cases.
- 5.3 Angiographically confirmed aortic injury is found in only 10 – 20% of patients with mediastinal widening.

REFERENCES

1. Gunn ML. Imaging of aortic and branch vessel trauma. *Radiol Clin North Am.* 2012; 50: 85-103.
2. Chung JH, Cox CW, Mohammed TH, et al. ACR Appropriateness Criteria® Blunt Chest Trauma. Available at <https://acsearch.acr.org/docs/3082590/Narrative/>. American College of Radiology. Accessed 2017 September 18.
3. Kim H, Rybicki FJ, Majdalany BS, et al. ACR Appropriateness Criteria® Blunt Chest Trauma – Suspected Aortic Injury. Available at <https://acsearch.acr.org/docs/69410/Narrative/>. American College of Radiology. Accessed 2017 September 18.
4. The Royal College of Radiologists. iRefer: Making the best use of clinical radiology. 8th ed. London: The Royal College of Radiologists; 2017. Sections T28-T29.



REMARKS

1 Plain radiograph

- 1.1 Chest x-ray (CXR) is performed primarily to exclude other causes of acute chest pain in patients with suspected aortic dissection, e.g. pneumothorax.
- 1.2 CXR may identify signs suggestive of aortic dissection, such as widening of mediastinum, altered aortic contour, displaced intimal calcification (but these are not always present).
- 1.3 Normal CXR cannot exclude aortic dissection.

2 CT

- 2.1 CT is the recommended definitive investigation for suspected aortic dissection.
- 2.2 CT is minimally invasive, fast, readily available in most hospitals, and instigates less patient discomfort.
- 2.3 CT can provide evaluation of the type and extent of aortic dissection, thereby aiding the clinical management decision.
- 2.4 CT can also detect other causes of chest pain other than dissection, e.g. thoracic pathology.
- 2.5 Non-contrast CT is important to detect acute intramural haematoma.
- 2.6 In case of suspected aortic root involvement, electrocardiogram (ECG) gated CT improves diagnostic accuracy.

3. MRI

- 3.1 MRI is considered as an accurate technique for diagnosis of aortic dissection.
- 3.2 MRI is not advocated as the initial diagnostic test for acute aortic dissection under the following conditions:
 - 3.2.1 Limited scanner and skilled technologist availability on emergency basis
 - 3.2.2 Long examination time which is not favourable for critically ill patients
 - 3.2.3 Patient factors such as inability to hold breath or cardiac arrhythmia which may produce significant artefacts and a non-diagnostic scan
 - 3.2.4 Presence of MRI-incompatible implants and devices including pacemaker
 - 3.2.5 Difficulties in monitoring ill patients in the MRI suite
- 3.3 MRI may be considered in stable patients for the purpose of follow-up of chronic dissection or as an alternative in patients contraindicated for iodinated intravenous (IV) contrast.

4. Echocardiography

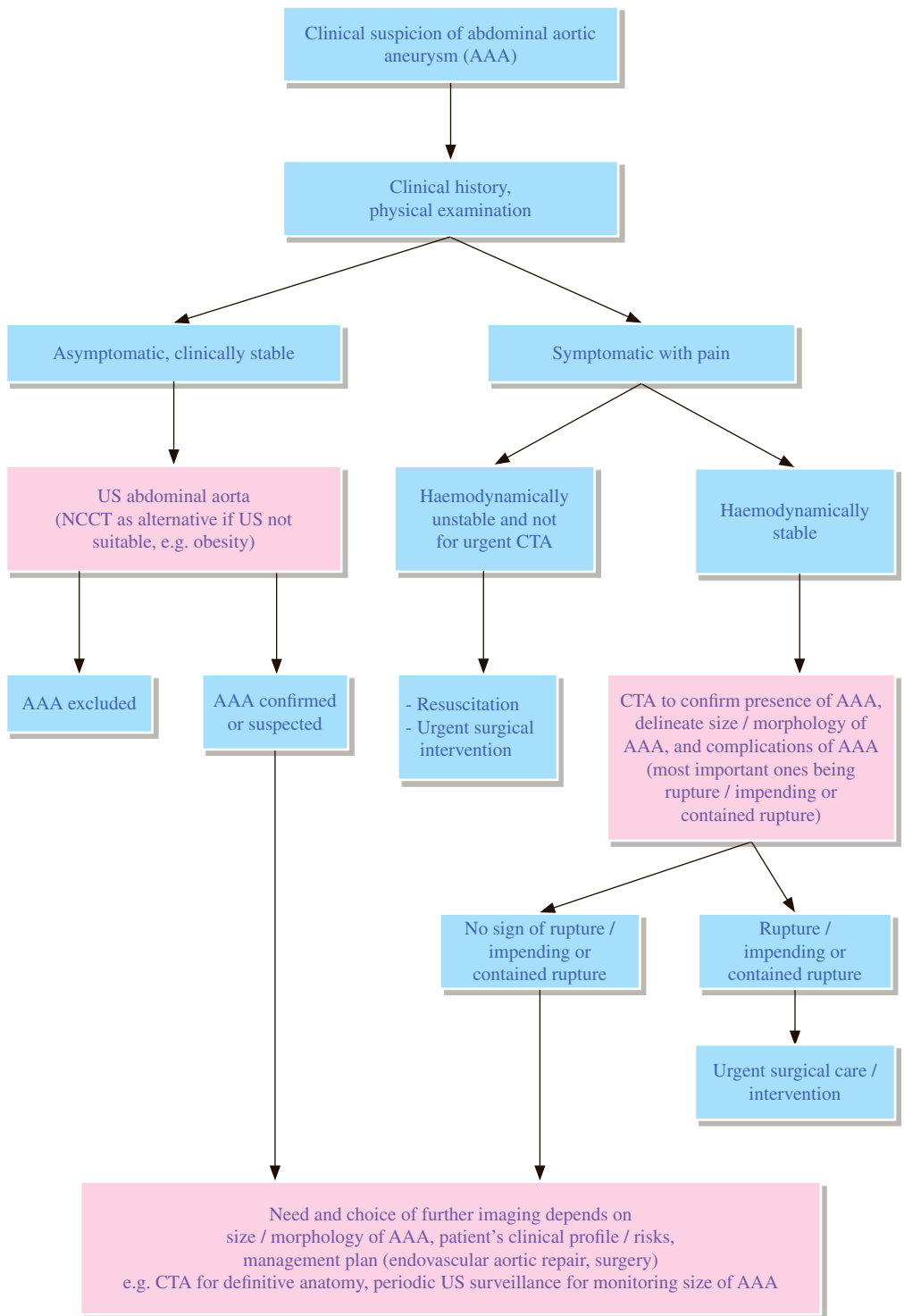
- 4.1 Transoesophageal echocardiography (TOE) has the advantage of bedside use in haemodynamically unstable patients.
- 4.2 It is useful in detecting dissection involving the descending thoracic aorta.
- 4.3 Limitations of TOE include the dependence on operator skill; limited availability of clinicians who are skilled and experienced in performing TOE in emergency setting; the blind area of distal ascending aorta and arch vessels assessment; and the inability to assess distal extent of dissection in the abdomen.

5. Catheter angiography

- 5.1 It was historically the gold standard for diagnosing aortic dissection.
- 5.2 It is now rarely used for the diagnosis of aortic dissection.
- 5.3 It is invasive, requiring direct puncture of the arterial system.
- 5.4 It is used for part of therapeutic endovascular procedures, or for pre-operative angiographic assessment of coronary arteries.

REFERENCES

1. Hiratzka LF, Bakris GL, Beckman JA, Bersin RM, Carr VF, Casey DE, et al. 2010 ACCF/AHA/AATS/ACR/ASA/SCA/SCAI/SIR/STS/SVM Guidelines for the Diagnosis and Management of Patients With Thoracic Aortic Disease: Executive Summary. *J Am Coll Cardiol* 2010; 55: 1509-1544.
2. Jacobs JE, Latson Jr LA, Abbara S, et al. ACR Appropriateness Criteria® Acute Chest Pain – Suspected Aortic Dissection. Available at <https://acsearch.acr.org/docs/69402/Narrative/>. American College of Radiology. Accessed 2017 June 1.
3. The Royal College of Radiologists. iRefer: Making the best use of clinical radiology. 8th ed. London: The Royal College of Radiologists; 2017. Section CC03.



REMARKS

1 US

- 1.1 Initial examination of choice for asymptomatic, clinically stable patients.
- 1.2 Should be a dedicated study (including complete longitudinal extent of abdominal aortic aneurysm (AAA), any involvement of common iliac arteries, relationship with renal arteries).
- 1.3 Difficult to delineate upper margin of AAA from juxtarenal level or above, and involvement of visceral vessels.
- 1.4 Limitations from patient's body, habitus and acoustic window.

2 CT

- 2.1 Non-contrast computed tomography (NCCT) may be considered when US is not suitable (e.g. obese patients).
- 2.2 NCCT may be considered in patients with or without clinical suspicion of impending or contained rupture.
- 2.3 Computed tomography angiogram (CTA) is best for definitive diagnosis and as a pre-interventional reference.
- 2.4 Useful information obtained from CTA includes morphology and full extent of the AAA, extent of mural thrombus, involvement of branch vessels, three-dimensional (3D) analysis (such as volume rendering, maximum intensity projection (MIP), multiplanar reformats).
- 2.5 First line imaging modality in the emergency setting for the assessment of suspected AAA rupture / impending or contained rupture.

3. MRI

- 3.1 Magnetic resonance angiogram (MRA) may be an alternative to CTA.
- 3.2 Non-contrast and contrast-enhanced sequences can be used.
- 3.3 Non-contrast sequences for patients with severe impaired renal function [glomerular filtration rate (GFR) <30]. Disadvantages of non-contrast MRA include suboptimal assessment of small vessel lesions / small side branches, susceptibility to flowing blood and blooming artefacts.
- 3.4 Other concerns include scanner accessibility, skilled operator / expertise availability, longer scanning time, decreased spatial resolution and general contraindications to MRI (such as pacemaker).
- 3.5 Significant artefacts can be encountered with certain types of stents other than nickel.

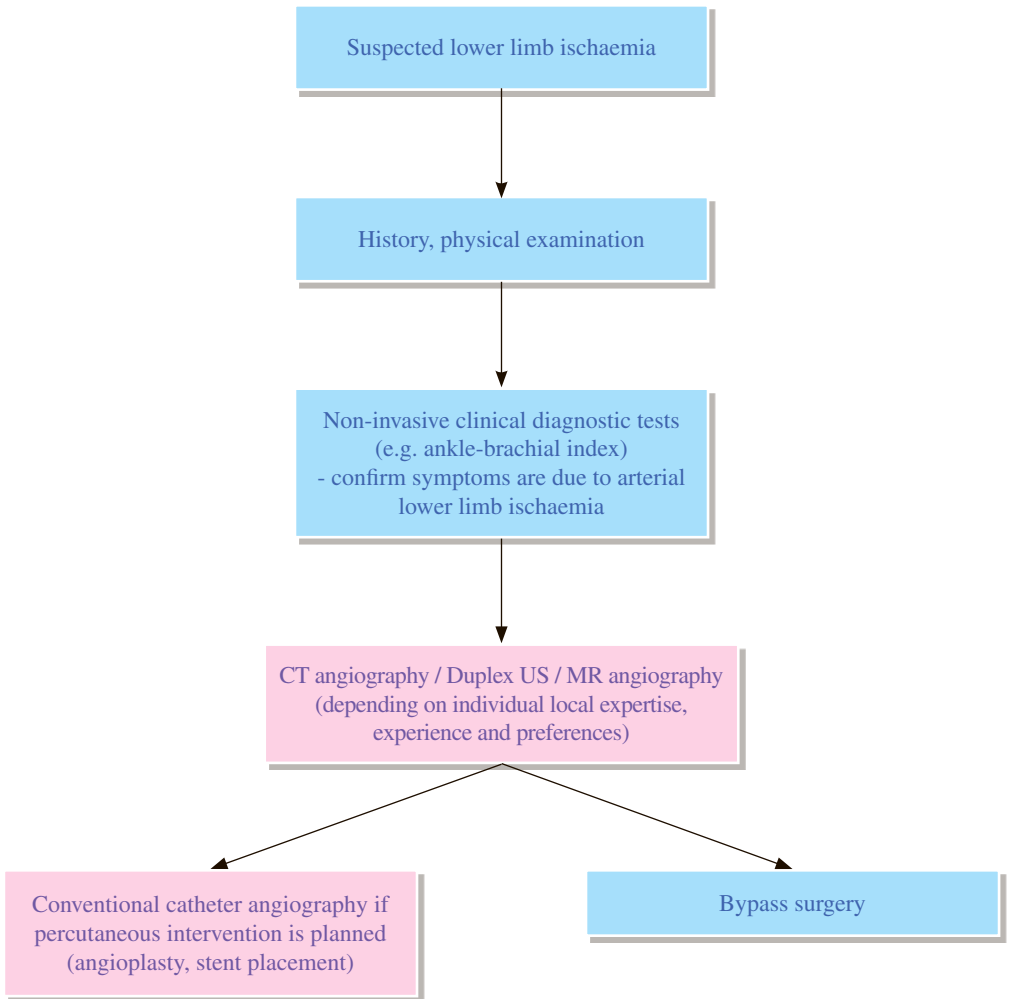
4 Catheter angiography

- 4.1 Usually not for establishing the diagnosis.
- 4.2 Essentially replaced by non-invasive imaging techniques in diagnosis (US, CTA).
- 4.3 May be used for pre-interventional planning.
- 4.4 Essential component of endovascular aortic repair (EVAR) procedure.

- 5 Management of AAA includes conservative approach, open surgery and EVAR; depending on clinical presentation, patient's profile and size / morphology of aneurysm:
 - 5.1 EVAR has emerged as an important treatment option in the management of AAA.
 - 5.2 With the advent of EVAR, pre-interventional imaging has become indispensable for surgical planning (suitability for stent graft deployment, delivery sheath size allowance).
 - 5.3 CTA is accepted as the gold standard for pre-EVAR planning, post-EVAR and post-open repair imaging surveillance.

REFERENCES

1. Reis SP, Majdalany BS, AbuRahma AF, et al. ACR Appropriateness Criteria® Pulsatile Abdominal Mass, Suspected Abdominal Aortic Aneurysm. Available at <https://acsearch.acr.org/docs/69414/Narrative/>. American College of Radiology. Accessed 2017 May 19.
2. Francois CJ, Kramer JH, Rybicki FJ, et al. ACR Appropriateness Criteria® Abdominal Aortic Aneurysm: Interventional Planning and Follow-up. Available at <https://acsearch.acr.org/docs/70548/Narrative/>. American College of Radiology. Accessed 2017 May 19.
3. The Royal College of Radiologists. iRefer: Making the best use of clinical radiology. 8th ed. London: The Royal College of Radiologists; 2017. Section CC12.



REMARKS

1. Non-invasive haemodynamic tests

- 1.1 Include ankle-brachial index (ABI), toe-brachial index (TBI), segmental pressures or pulse volume recordings.
- 1.2 These are important tools for evaluating peripheral vascular disease.
- 1.3 With the presence of normal ABI both at rest and exercise with compressible vessels, atherosclerotic occlusive disease is effectively excluded as a cause of claudication / rest pain and obviates need of further arterial imaging.

2 US

- 2.1 Duplex US imaging can diagnose the location, degree and extent of stenosis down to the level of the knee.
- 2.2 It can also estimate the velocity of blood flow.
- 2.3 Needs skilled and experienced operators, and is a time consuming procedure.
- 2.4 Has limitations which include vessel visualization obscured by bowel gas (abdominal aorta and iliac arteries), dense calcifications and in the setting of multiple sequential lesions.

3. Computed Tomography Angiogram (CTA)

- 3.1 With improvements in multidetector CT (MDCT) technology, CTA has several advantages over digital subtraction angiogram (DSA), including shorter examination time, non-invasive nature, lower complication rates, direct visualization of mural plaque and calcium, visualization of collaterals and three-dimensional (3D) volumetric display and analysis.
- 3.2 CTA has limitations which include difficulties in grading severity of vessel stenosis in presence of dense calcium; suboptimal assessment of calf vessels due to timing issues. Streak artefacts from metallic implants also limit the role of CTA in stent surveillance.
- 3.3 Use of iodinated intravenous (IV) contrast and ionizing radiation are concerns.

4. Magnetic Resonance Angiogram (MRA)

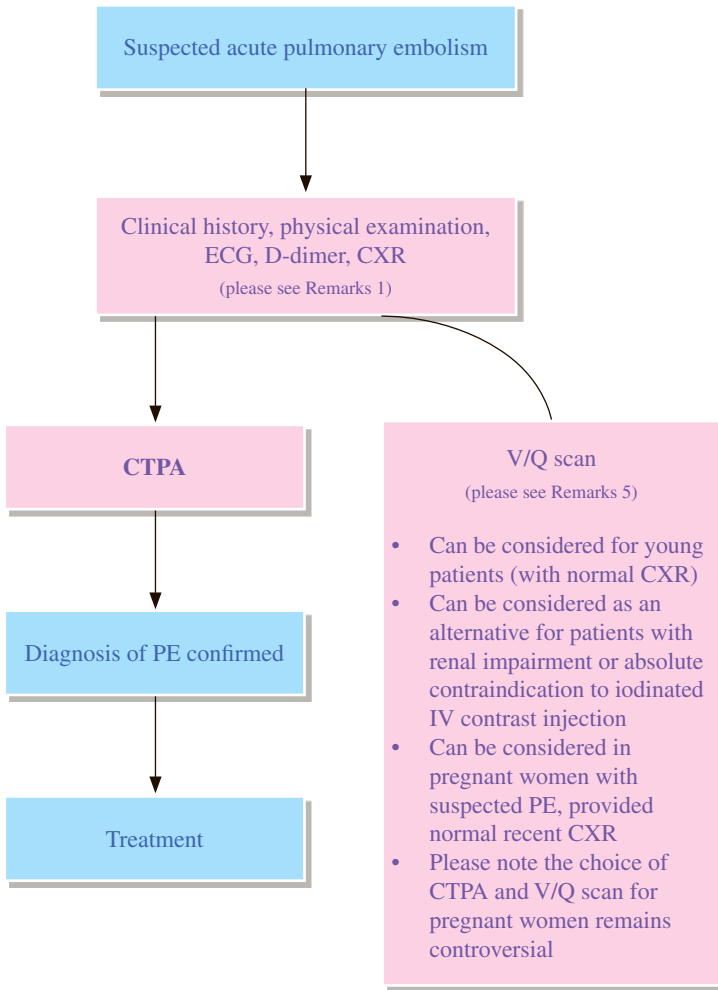
- 4.1 Non-invasive with no ionizing radiation.
- 4.2 Majority of MRI employs contrast-enhanced MRA sequences.
- 4.3 Non-contrast MRI sequences can be considered for patients with renal insufficiency.
- 4.4 Limitations of MRI which affect image quality include longer scanning time (may be more prone to motion artefacts); unreliable visualization of lesions with high flow and turbulence; suboptimal assessment of stent lumen or lumen close to prosthesis.

5. Catheter angiography

- 5.1 DSA is considered the gold standard for imaging of peripheral vascular disease.
 - 5.2 Can allow for intervention such as balloon angioplasty or stenting.
 - 5.3 It is invasive, needs iodinated IV contrast, requires multiple projections and involves ionizing radiation.
 - 5.4 It is now mainly indicated if intervention is planned.
6. Choices of non-invasive investigations (duplex US, CTA, MRA) depend on local expertise and experience.

REFERENCES

1. Ahmed O, Hanley M, Bennett SJ, et al. ACR Appropriateness Criteria® Vascular Claudication – Assessment for Revascularization. Available at <http://acsearch.acr.org/docs/69411/Narrative/>. American College of Radiology. Accessed 2017 Sep 24.
2. Schenker MP, Rybicki FJ, Dill KE, et al. ACR Appropriateness Criteria® Recurrent Symptoms Following Lower Extremity Angioplasty. Available at <https://acsearch.acr.org/docs/69415/Narrative/>. American College of Radiology. Accessed 2017 May 21.
3. The Royal College of Radiologists. iRefer: Making the best use of clinical radiology. 8th ed. London: The Royal College of Radiologists; 2017. Section CC14.
4. The Royal College of Radiologists. iRefer: Making the best use of clinical radiology. 8th ed. London: The Royal College of Radiologists; 2017. Section I01.
5. Ouwendijk R, de Vries M, Stijnen T, Pattynama PM, van Sambeek MR, Buth J, et al. Multicenter randomized controlled trial of the costs and effects of noninvasive diagnostic imaging in patients with peripheral arterial disease: the DIPAD trial. *AJR Am J Roentgenol*. 2008; 190: 1349-1357.
6. Gerhard-Herman MD, Gornik HL, Barrett C, Barshes NR, Corriere MA, Drachman DE, et al. 2016 AHA/ACC Guideline on the Management of Patients with Lower Extremity Peripheral Artery Disease: Executive Summary. *J Am Coll Cardiol*. 2017; 69: 1465-1508.



REMARKS

1 General

- 1.1 Diagnosis of pulmonary embolism (PE) based on clinical symptoms and signs can be difficult, as chest pain, shortness of breath and tachycardia are non-specific.
- 1.2 To diagnose or to exclude PE, it would be helpful to use an agreed protocol combining clinical features, pretest probability and results of D-dimer assay in order to utilize imaging appropriately, such as Wells' criteria for PE.
- 1.3 Wells' Prediction Rule for Diagnosing PE: Clinical Evaluation Table for Predicting Pretest Probability of PE
 - Symptoms of deep vein thrombosis (DVT): 3 points
 - No alternative diagnosis: 3 points
 - Heart rate >100 bpm: 1.5 points
 - Recent immobilization or surgery: 1.5 points
 - Previous DVT or PE: 1.5 points
 - Haemoptysis: 1 point
 - Malignancy: 1 point
- 1.4 The followings may be considered by referring clinicians as determinants of work-up for PE:
 - 1.4.1 Clinical probability of PE: low 0-1 point; intermediate 2-6 points; high \geq 7 points.
 - 1.4.1.1 If the patient is at LOW RISK, clinicians should use the eight Pulmonary Embolism Rule-Out Criteria (PERC); if a patient meets all eight criteria, the risks of testing are greater than the risk for embolism, and no testing is needed.
 - 1.4.1.2 For patients at INTERMEDIATE RISK, or for those at low risk who do not meet all of the rule-out criteria, use a high-sensitivity plasma D-dimer test as the initial test.
 - 1.4.1.3 Patients at HIGH RISK should skip the D-dimer test and proceed to CT pulmonary angiography, because a negative D-dimer test does not eliminate the need for imaging in these patients.
 - 1.4.2 Alternatively, a two-tier model can be used, if score \leq 4, D-dimer evaluation is needed first.

2 Plain radiograph

- 2.1 Chest x-ray (CXR) is non-specific for PE.
- 2.2 Normal or abnormal CXR cannot exclude presence of PE.
- 2.3 There are no specific findings on CXR which are sufficient to confirm PE.
- 2.4 CXR is useful to exclude other causes of acute chest pain.
- 2.5 A recent CXR is required to allow accurate interpretation of abnormal radionuclide ventilation / perfusion scintigraphy (V/Q scan).

3 Computed tomography pulmonary angiogram (CTPA)

- 3.1 CTPA is the current standard of care and primary imaging modality for detecting PE.
- 3.2 CTPA is highly sensitive and specific.
- 3.3 There are fewer non-diagnostic studies of CTPA than that of V/Q scan.
- 3.4 CTPA can identify features of right ventricular dysfunction which indicates poor prognosis of PE.

4 US

- 4.1 Doppler US of lower extremity veins is useful as there is high association of DVT with PE.
- 4.2 Presence of DVT does not indicate the presence (or absence) of PE, but may increase (or decrease) its likelihood.
- 4.3 In pregnant women with suspected PE and clinical features suggestive of DVT, compression Doppler US of the symptomatic leg veins should be the initial investigation.
- 4.4 Transthoracic echocardiogram (TTE) or transoesophageal echocardiogram (TOE) are generally not indicated for the diagnosis of acute PE, but are useful in the assessment of right ventricular morphology and function.

5 Ventilation / Perfusion scintigraphy (V/Q scan)

- 5.1 Overall decreasing role in evaluation of suspected PE as compared to CTPA.
- 5.2 Scan findings classified by the modified Prospective Investigation of Pulmonary Embolism Diagnosis (PIOPED) II criteria are reported as “PE present” (high probability), “PE absent” (very low probability or normal), or “not diagnostic” (all other findings).
- 5.3 A normal perfusion scan can obviate the need of ventilation scan, further reducing the dose.
- 5.4 V/Q scan can be an alternative to CTPA in patients without pre-existing pulmonary disease and with normal CXR.
- 5.5 V/Q scan delivers lower radiation dose to the breasts and lower overall maternal radiation dose when compared with CTPA.
- 5.6 V/Q scan can be considered as the first choice of assessment for suspected PE in young patients, particularly during pregnancy (provided normal CXR) and in patients with renal impairment.
- 5.7 Use of single photon emission computed tomography (SPECT) may decrease the rate of non-diagnostic test and improves the diagnostic performance.
- 5.8 V/Q scan is the most sensitive test for chronic pulmonary embolism.
- 5.9 The use of CTPA or V/Q scan in pregnant patients remains a matter of debate.
- 5.10 Not every hospital provides nuclear medicine clinical services. CT is available in most hospitals.

6 MRI

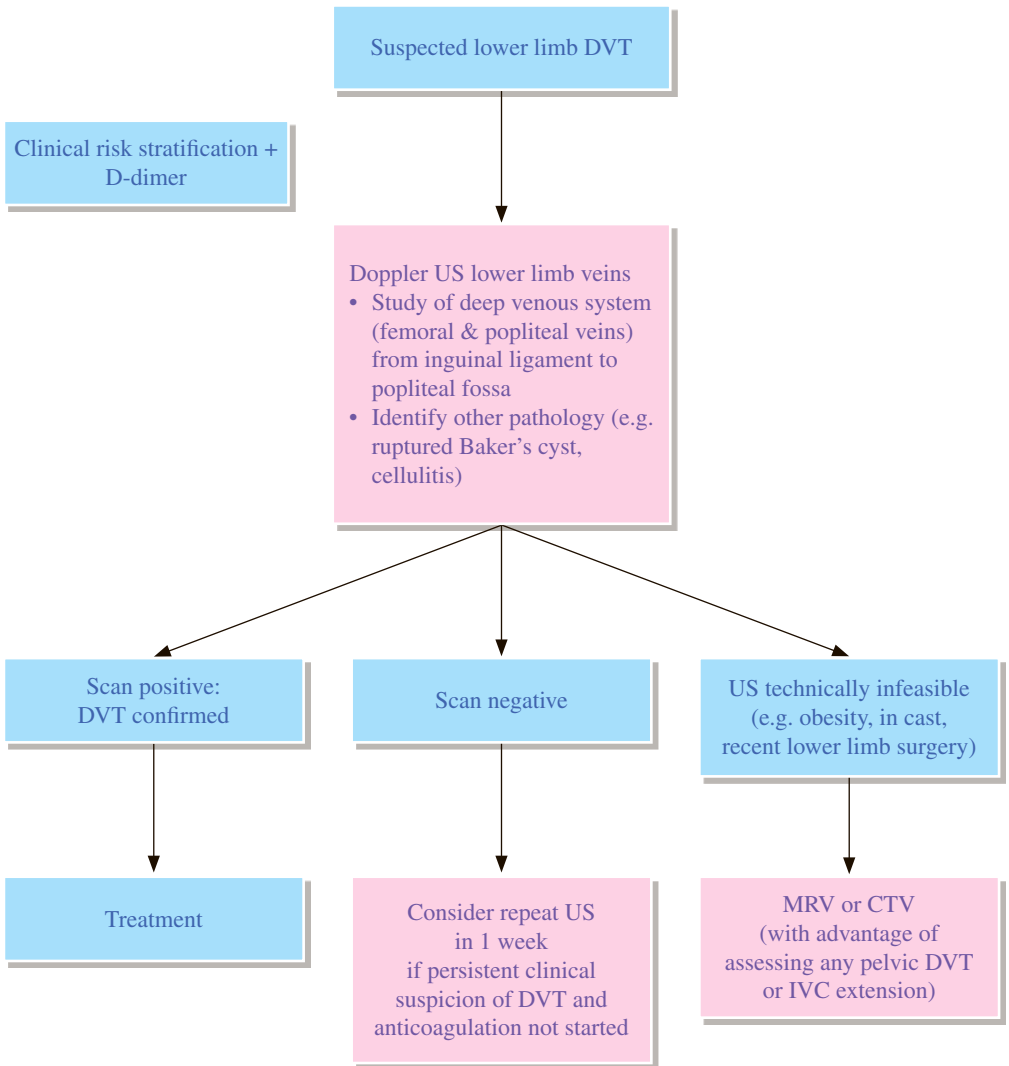
- 6.1 MRI and magnetic resonance angiogram (MRA) are not generally advocated.

7 Catheter-directed angiography of pulmonary arteries

- 7.1 Conventional catheter angiography of pulmonary arteries is generally not necessary for the diagnosis of PE.
- 7.2 Useful if intervention such as thrombectomy or thrombolysis is needed.

REFERENCES

1. Kirsch J, Brown RKJ, Henry TS, et al. ACR Appropriateness Criteria® Suspected Pulmonary Embolism. Available at <https://acsearch.acr.org/docs/69404/Narrative/>. American College of Radiology. Accessed 2017 Jun 27.
2. Stein PD, Fowler SE, Goodman LR, Gottschalk A, Hales CA, Hull RD, et al. Multidetector computed tomography for acute pulmonary embolism. *N Engl J Med*. 2006; 354: 2317-2327.
3. Yazdani M, Lau CT, Lempel JK, Yadav R, El-Sherief AH, Azok JT, et al. Historical Evolution of Imaging Techniques for the Evaluation of Pulmonary Embolism: RSNA Centennial Article. *Radiographics*. 2015; 35: 1245-1262.
4. Leung AN, Bull TM, Jaeschke R, Lockwood CJ, Boisselle PM, Hurwitz LM, et al. An official American Thoracic Society/Society of Thoracic Radiology clinical practice guideline: evaluation of suspected pulmonary embolism in pregnancy. *Am J Respir Crit Care Med*. 2011; 184: 1200-1208.
5. Konstantinides SV, Torbicki A, Aqnelli G, Danchin N, Fitzmaurice D, Galie N, et al. 2014 ESC guidelines on the diagnosis and management of acute pulmonary embolism. *Eur Heart J*. 2014; 35: 3033-3069.
6. Bajc M, Neilly JB, Miniati M, Schuemichen C, Meignan M, Jonson B; EANM committee. EANM guidelines for ventilation/perfusion scintigraphy: Part 1. Pulmonary imaging with ventilation/perfusion single photon emission scintigraphy. *Eur J Nucl Med Mol Imaging*. 2009; 36: 1356-1370.
7. The Royal College of Radiologists. iRefer: Making the best use of clinical radiology. 8th ed. London: The Royal College of Radiologists; 2017. Sections CC04, CC31.



REMARKS

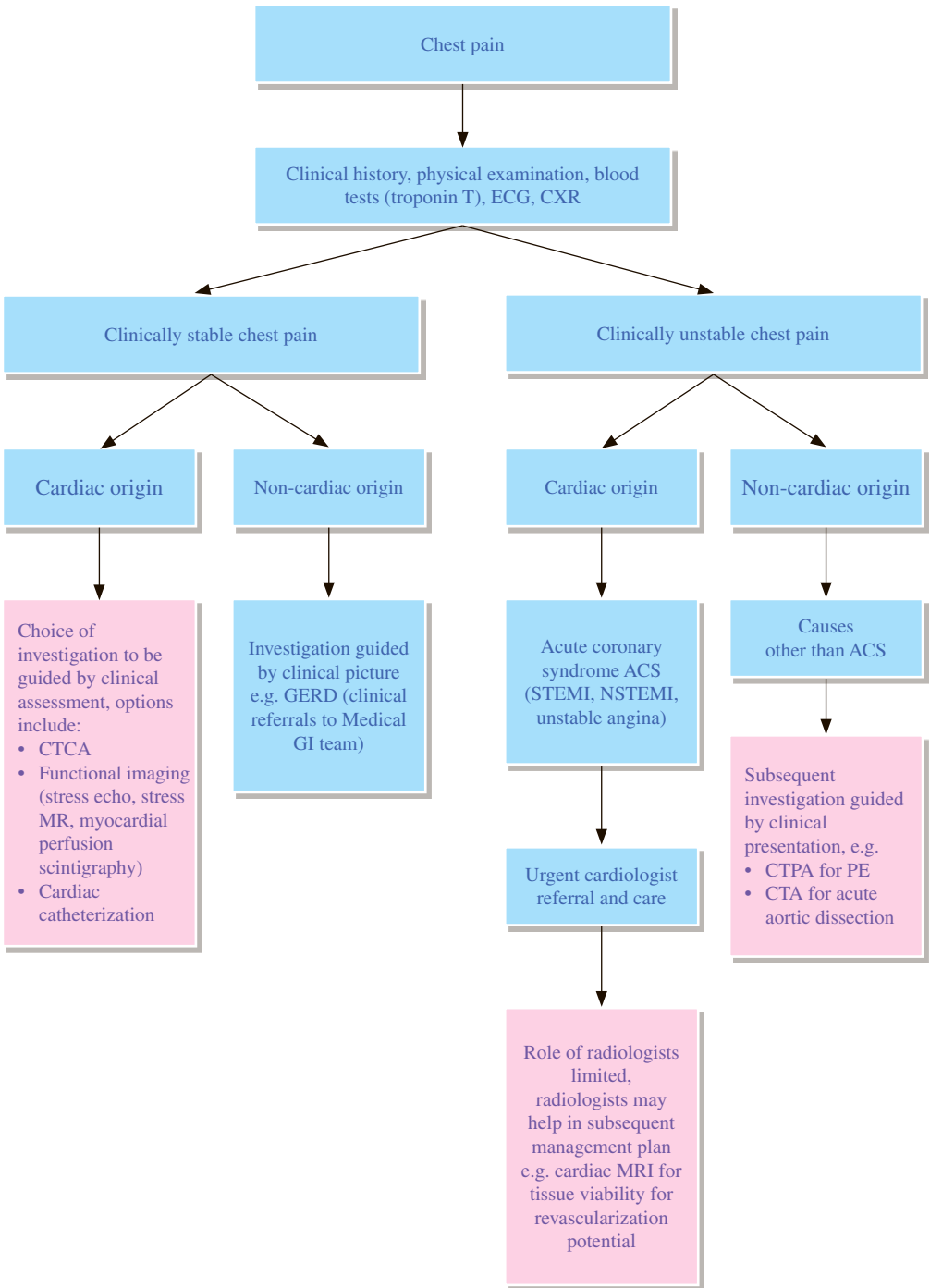
- 1 Initial screening for possible deep vein thrombosis (DVT) includes a combination of clinical risk stratification score (e.g. Wells' score) and plasma D-dimer assay.
- 2 Both clinical risk stratification scoring and D-dimer assay have limitations. Imaging is typically required for confirmation of DVT.
- 3 **US**
 - 3.1 Preferred primary imaging modality for diagnosing proximal DVT (from inguinal ligament to popliteal fossa).
 - 3.2 Non-invasive, no exposure to ionizing radiation or iodinated contrast media, widely available and easily performed at patient's bedside.
 - 3.3 Compression US is most important, often combined with real time Doppler imaging.
 - 3.4 Duplex US for augmentation of venous flow rarely provides additional information.
 - 3.5 High sensitivity (range: 93.2% - 95.0%, pooled sensitivity 94.2%) and high specificity (range: 93.1% - 94.4%, pooled sensitivity 93.8%) for diagnosing proximal DVT.
 - 3.6 Much lower sensitivity for diagnosing distal DVT (below knee).
 - 3.7 Difficult to assess pelvic DVT using US.
 - 3.8 DVT limited to infrapopliteal calf veins (distal DVT) often resolves spontaneously and is rarely associated with pulmonary embolism. Treatment of distal DVT remains controversial. US calf veins is not recommended as a routine.
 - 3.9 When there is persistent high clinical suspicion of DVT in patients who had an initial negative US and in whom anti-coagulation was not started, follow-up US in 1 week may be considered to exclude a calf thrombus that is propagating proximally.
- 4 **Magnetic resonance venography (MRV) / Computed tomography venography (CTV)**
 - 4.1 Viable imaging options in patients in whom US is technically not feasible (e.g. in cast, obesity); and in patients with high suspicion of pelvic DVT or non-diagnostic US examinations.
 - 4.2 Distinct advantage over US in demonstrating pelvic vein / inferior vena cava (IVC) involvement and extravascular pathology that may account for DVT.
 - 4.3 MRV: no ionizing radiation, can be done with or without contrast; limitation include scanner availability, longer scanning time, patient factors and implants / devices which are MRI incompatible.
 - 4.4 CTV: involves ionizing radiation and use of intravenous contrast; CTV may be incorporated into CT investigation of pulmonary embolism and proximal DVT.

5 Contrast X-ray venography

- 5.1 Historic gold standard for diagnosing DVT.
- 5.2 Rarely used nowadays.
- 5.3 Has a role in assessing recurrent acute DVT in patients with a previous history of DVT and in whom venous anatomy is complex.

REFERENCES

1. Hanley M, Donahue J, Rybicki FJ, et al. ACR Appropriateness Criteria® Suspected Lower-Extremity Deep Vein Thrombosis. Available at <https://acsearch.acr.org/docs/69416/Narrative/>. American College of Radiology. Accessed 2017 May 28.
2. The Royal College of Radiologists. iRefer: Making the best use of clinical radiology. 8th ed. London: The Royal College of Radiologists; 2017. Section CC13.
3. Wells PS, Owen C, Doucette S, Fergusson D, Tran H. Does this patient have deep vein thrombosis? *JAMA*. 2006; 295: 199-207.
4. Stein PD, Hull RD, Patel KC, Olson RE, Ghali WA, Brant R, et al. D-Dimer for the Exclusion of Acute Venous Thrombosis and Pulmonary Embolism: A Systematic Review. *Ann Intern Med*. 2004; 140: 589-602.
5. Masuda EM, Kistner RL, Musikasinthorn C, Liquido F, Geling O, He Q. The controversy of managing calf vein thrombosis. *J Vasc Surg*. 2012; 55: 550-561.
6. Sampson FC, Goodacre SW, Thomas SM, van Beek EJ. The accuracy of MRI in diagnosis of suspected deep vein thrombosis: systematic review and meta-analysis. *EurRadiol*. 2007; 17: 175-181.
7. Thomas SM, Goodacre SW, Sampson FC, van Beek EJ. Diagnostic value of CT for deep vein thrombosis: results of a systematic review and meta-analysis. *Clin Radiol*. 2008; 63: 299-304.



REMARKS

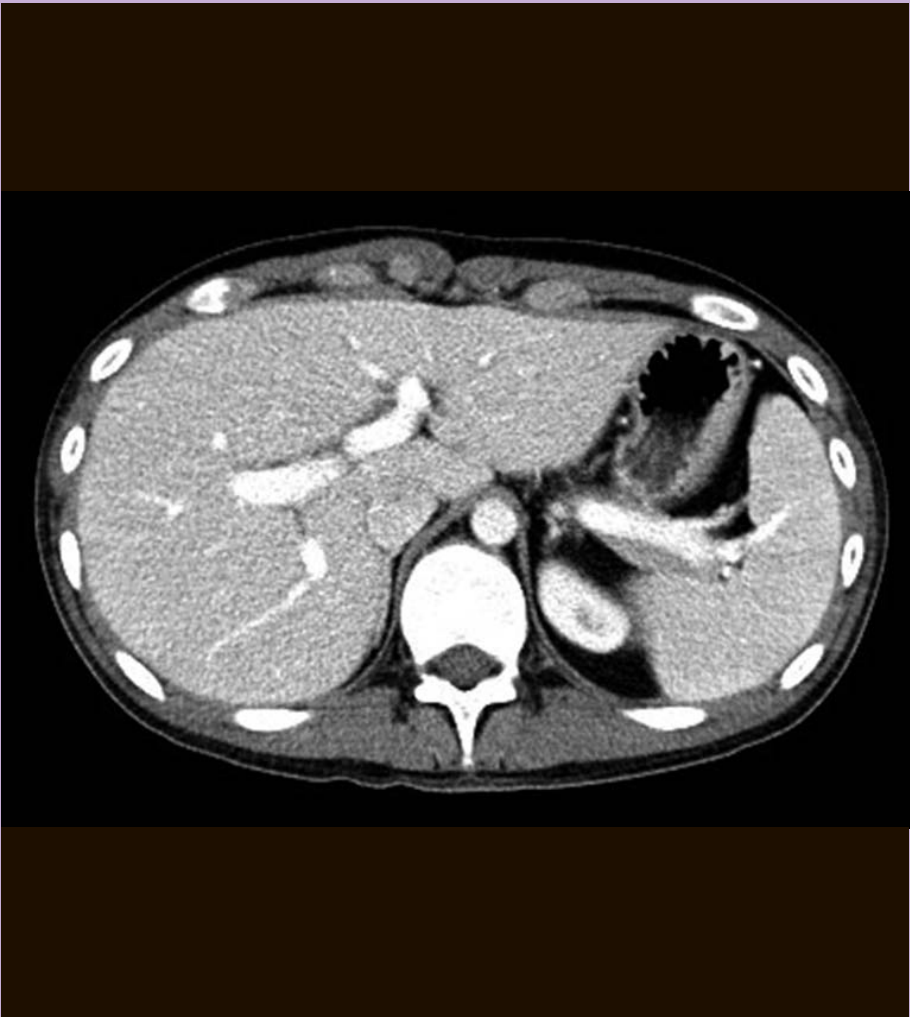1. There are many aetiologies of chest pain.
 - 1.1 **Cardiac origin** such as acute coronary syndrome (ACS) [including ST-segment-elevation myocardial infarction (STEMI), non-ST-segment-elevation myocardial infarction (NSTEMI), unstable angina], myocarditis, pericarditis.
 - 1.2 **Non-cardiac origin** such as pneumothorax, pulmonary embolism, acute aortic dissection, pneumonia, pulmonary carcinoma.
Gastroesophageal reflux disease (GERD) is the commonest cause of non-cardiac cause of chronic chest pain.
- 2 Initial clinical assessment [history, physical examination, electrocardiogram (ECG), blood test - troponin, chest X-ray (CXR)] is mandatory to distinguish clinically stable and clinically unstable patients presenting with chest pain.
- 3 For clinically stable chest pain; approaches are as discussed below:
 - 3.1 National Institute for Health and Care Excellence (NICE) guideline (CG 95): Chest pain of recent onset: assessment and diagnosis
 - 3.1.1 Clinical assessment (based on clinical history and physical examination) is important.
 - 3.1.2 64-slice (or above) CT coronary angiography (CTCA) if clinical assessment indicates typical or atypical angina; or clinical assessment indicates non-anginal chest pain but 12-lead resting ECG indicates ST-T changes or Q waves.
 - 3.1.3 Non-invasive functional testing for patients with confirmed / known coronary artery disease (CAD) (such as previous myocardial infarction, revascularization, previous angiography) when uncertain whether chest pain is caused by myocardial ischaemia.
 - 3.2 American College of Radiology (ACR) Appropriateness Criteria: Chronic chest pain
 - 3.2.1 Low to Intermediate probabilities of CAD (2012)
 - 3.2.2 Stress studies (myocardial perfusion scintigraphy, stress cardiac MRI, stress echo); CTCA
 - 3.3 American College of Radiology (ACR) Appropriateness Criteria: Chronic chest pain
 - 3.3.1 High probability of CAD (2016)
 - 3.3.2 Myocardial perfusion scintigraphy, stress echocardiography, stress cardiac MRI
- 4 For clinically unstable chest pain, if initial clinical assessment indicates clear ACS (STEMI, NSTEMI, unstable angina), patients should be urgently taken care of by cardiologists.
 - 4.1 Roles of radiologists are limited in this scenario.
 - 4.2 Radiologists may have a role in subsequent management plan such as,
 - 4.2.1 Assessment of tissue viability for revascularization potential (cardiac MRI).
 - 4.2.2 Assessment of coronary artery anatomy (CTCA), in cases of complex vessel anatomy (chronic total occlusion, anomalies) found in invasive cardiac catheterization, and planning of percutaneous coronary intervention (PCI) / coronary artery bypass graft (CABG).
 - 4.3 For a certain subset of patients who present with clinically stable ACS (unstable angina/NSTEMI) and not selected for urgent catheter catheterization, a number of imaging modalities can be considered for evaluation, e.g. myocardial perfusion scintigraphy, CTCA, cardiac MRI, stress echocardiography.

- 5 For clinically unstable chest pain, if initial clinical assessment suggests conditions other than ACS, subsequent imaging investigations shall be guided by the individual clinical presentation.
 - 5.1 CXR is routinely/universally performed and may give clues to the causes of chest pain (such as pneumothorax, widened mediastinum indicating possibility of aortic dissection).
 - 5.2 Normal CXR cannot rule out significant pathology.
 - 5.3 Computed tomography pulmonary angiogram (CTPA) for suspected pulmonary embolism.
 - 5.4 CT aortogram for suspected intramural haematoma, aortic dissection.
 - 5.5 Cardiac MRI for suspected myocarditis.
 - 5.6 Echocardiography for pericardial effusion, infective endocarditis.
 - 5.7 US abdomen for acute cholecystitis or acute pancreatitis which may be the cause of chest pain; CT abdomen for suspected perforated hollow viscus which may cause excruciating chest pain.

REFERENCES

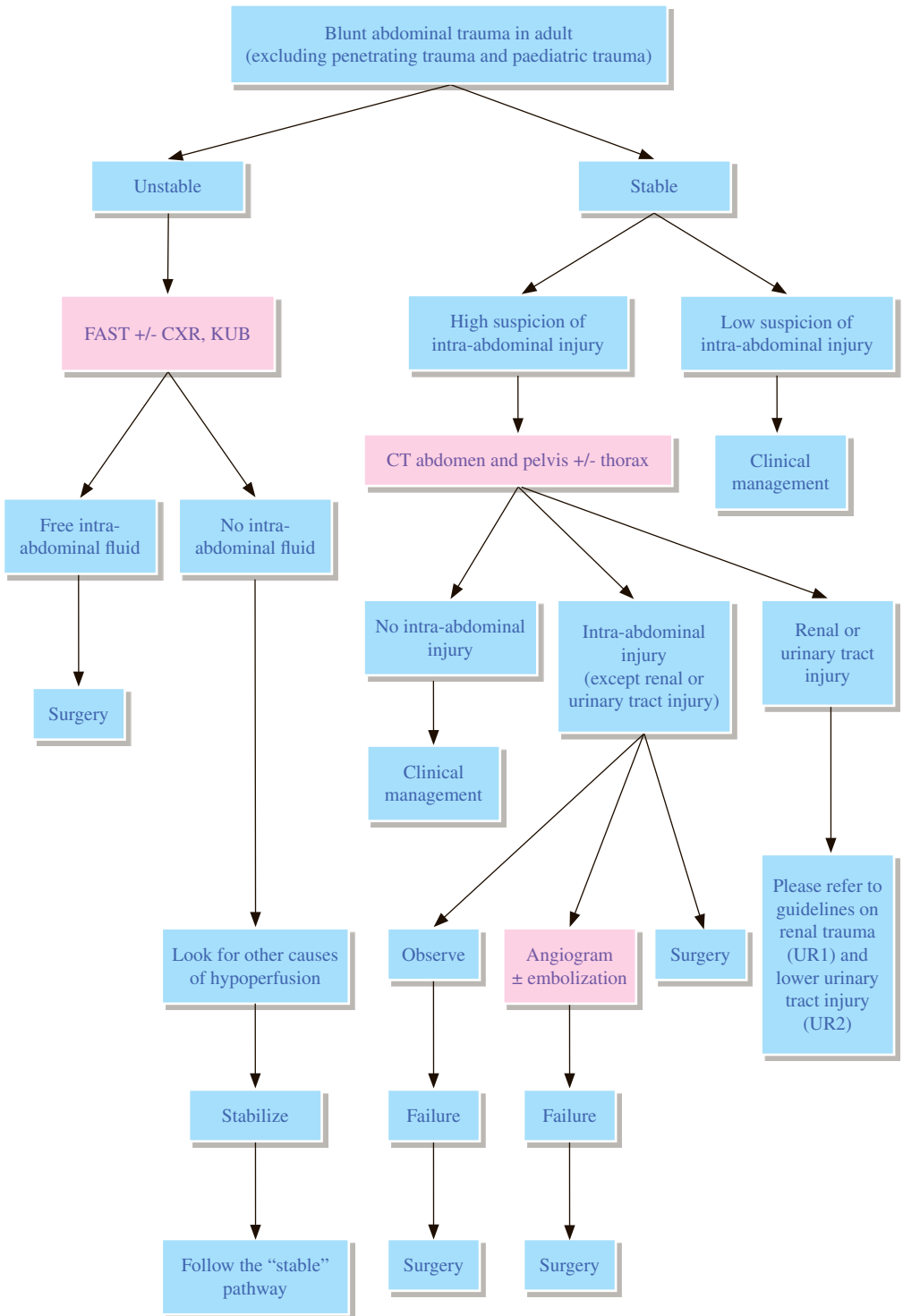
1. Hofmann U, Akers SR, Brown RKJ, et al. ACR Appropriateness Criteria® Acute Nonspecific Chest Pain – Low Probability of Coronary Artery Disease. Available at <https://acsearch.acr.org/docs/69401/Narrative/>. American College of Radiology. Accessed 2017 May 29.
2. Woodard PK, White RD, Abbara S, et al. ACR Appropriateness Criteria® Chronic Chest Pain – Low to Intermediate Probability of Coronary Artery Disease. Available at <https://acsearch.acr.org/docs/69337/Narrative/>. American College of Radiology. Accessed 2017 May 29.
3. Akers SR, Panchal V, Ho VB, et al. ACR Appropriateness Criteria® Chronic Chest Pain – High Probability of Coronary Artery Disease. Available at <https://acsearch.acr.org/docs/69405/Narrative/>. American College of Radiology. Accessed 2017 May 29.
4. Mammen L, Abbara S, Dorbala S, et al. ACR Appropriateness Criteria® Chest Pain Suggestive of Acute Coronary Syndrome. Available at <https://acsearch.acr.org/docs/69403/Narrative/>. American College of Radiology. Accessed 2017 May 29.
5. National Institute for Health and Clinical Excellence (2010) Chest pain of recent onset: assessment and diagnosis. NICE Guideline (CG 95).

Gastrointestinal Radiology



Hong Kong College of Radiologists

GI 1 Blunt abdominal trauma in adult



REMARKS

1 General

- 1.1 Penetrating trauma and paediatric trauma are excluded in this guideline.
- 1.2 The extent and choice of imaging is influenced by the haemodynamic stability of the patient together with the severity of trauma, site of trauma, and other associated injuries.

2 Plain radiograph

- 2.1 Plain radiographs including chest X-ray (CXR) and kidney, ureter and bladder radiograph (KUB) can evaluate fracture, pneumothorax, pneumomediastinum, and abnormal intra-abdominal gas collection, but they are frequently negative.
- 2.2 CXR, KUB and focused assessment with sonography for trauma (FAST) are complementary examinations if patient condition permits.

3 US

- 3.1 US is not an appropriate modality to evaluate organ injury in a patient with blunt abdominal trauma. A negative US does not rule out visceral injury.
- 3.2 FAST is to check for intra-abdominal free fluid that can guide decisions on further management.
- 3.3 A negative FAST does not completely rule out haemoperitoneum. There is a false negative rate of >15%.

4 CT

- 4.1 In stable patients with blunt abdominal trauma, CT abdomen and pelvis is the primary imaging modality for deciding whether the patient needs urgent surgery, angiography +/- therapeutic embolization, or close observation.
- 4.2 CT is excellent for identifying active haemorrhage, or hepatobiliary, splenic, pancreatic, genitourinary, intestinal, or diaphragmatic injury.
- 4.3 CT evaluation of abdomen and pelvis for blunt trauma does not require the use of oral contrast. Scanning should include the lower thorax through to the floor of the pelvis with administration of intravenous (IV) contrast.

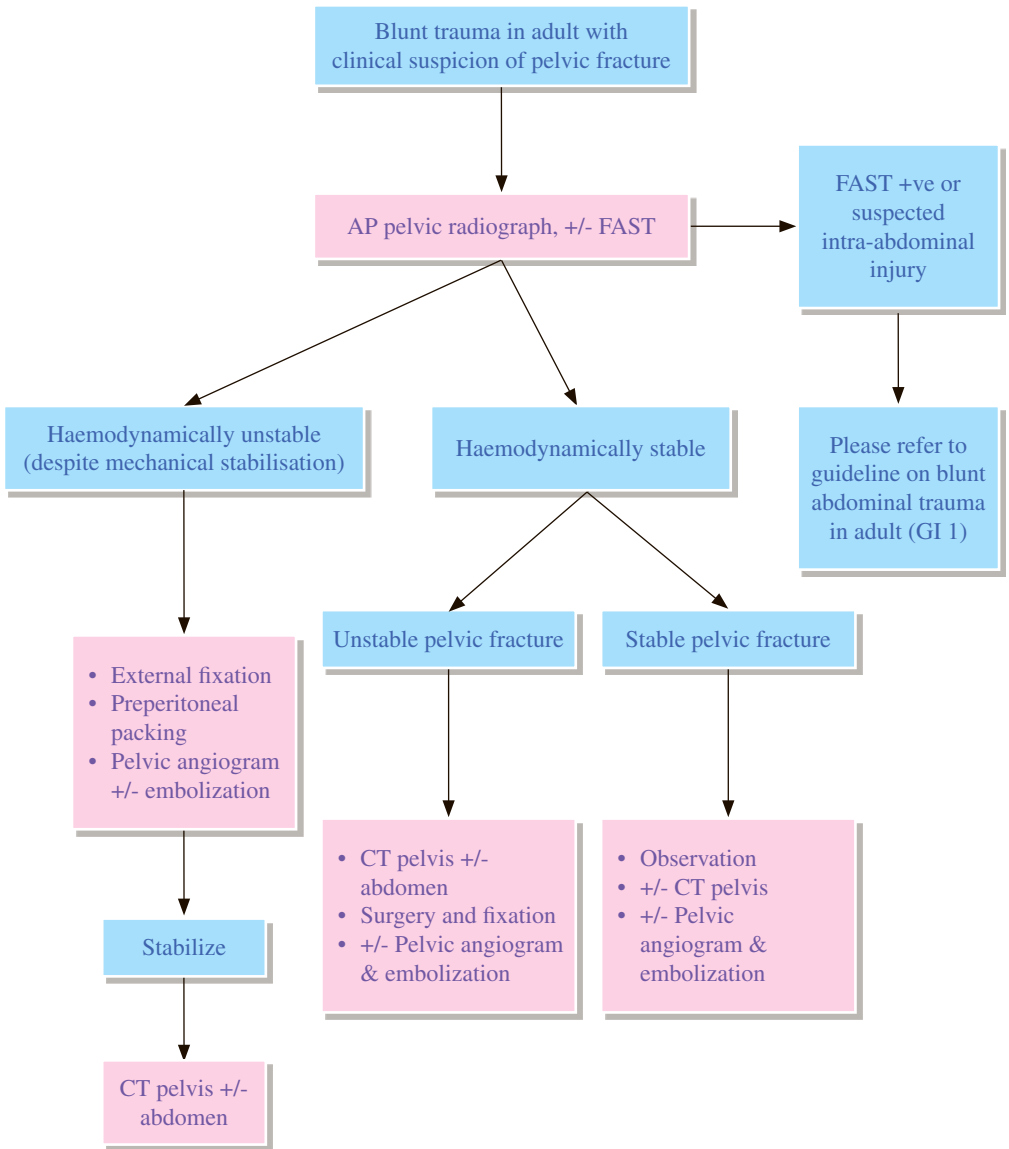
5 Angiography

- 5.1 Not appropriate as an initial imaging modality. It is appropriate if additional clinical information or imaging suggests possibility of active haemorrhage or pseudoaneurysm in haemodynamically stable patients.

REFERENCES

1. Gay SB, Sistrom CL. Computed tomographic evaluation of blunt abdominal trauma. *Radiol Clin North Am.* 1992; 30: 367-388.
2. Jeffrey RB, Olcott EW. Imaging of blunt hepatic trauma. *Radiol Clin North Am.* 1991; 29: 1299-1310.
3. Tso P, Rodriguez A, Cooper C, Militello P, Mirvis S, Badellino MM, et al. Sonography in blunt abdominal trauma: a preliminary progress report. *J Trauma.* 1992; 33: 39-44.
4. Rizzo MJ, Federle MP, Griffiths BG. Bowel and mesenteric injury following blunt abdominal trauma: evaluation with CT. *Radiology.* 1989; 173: 143-148.
5. Forster R, Pillasch J, Zielke A, Malewski U, Rothmund M. Ultrasonography in blunt abdominal trauma: influence of the investigator's experience. *J Trauma.* 1992; 34: 264-269.
6. Sudakoff GS, Rosen MP, Rybicki FJ, et al. ACR Appropriateness Criteria® Blunt Abdominal Trauma. Available at <https://acsearch.acr.org/docs/69409/Narrative/>. American College of Radiology. Accessed 2017 April 5.
7. Jansen JO, Yule SR, Loudon MA. Investigation of blunt abdominal trauma. *BMJ.* 2008; 336: 938-942.
8. Department of Health, Government of Western Australia. Diagnostic Imaging Pathways – Abdominal Blunt Trauma. Perth: Department of Health, Government of Western Australia; 2013 August.
9. Stassen NA, Bhullar I, Cheng JD, Crandall M, Friese R, Guillaumondegui O, et al. Non-operative management of blunt hepatic injury: An Eastern Association for the Surgery of Trauma practice management guideline. *J Trauma Acute Care Surg.* 2012; 73: S288-S293.
10. Stassen NA, Bhullar I, Cheng JD, Crandall M, Friese R, Guillaumondegui O, et al. Selective non-operative management of blunt splenic injury: An Eastern Association for the Surgery of Trauma practice management guideline. *J Trauma Acute Care Surg.* 2012; 73: S294-S300.
11. Moore FA, Davis JW, Moore EE, Cocanour CS, West MA, McIntyre RC Jr. WTA Critical Decisions in Trauma: Management of Adult Blunt Splenic Injury. *J Trauma.* 2008; 65: 1012-1015.
12. American College of Emergency Physicians. ACEP Evaluation of Adult Emergency Department Patients with Acute Blunt Abdominal Trauma. Dallas: American College of Emergency Physicians; 2011.

GI 2 Blunt pelvic trauma



REMARKS

1 General

- 1.1 The clinical management of pelvic trauma is dependent on the haemodynamic status and the amount of blood loss.
- 1.2 Concomitant major trauma to other sites has to be excluded in significant pelvic trauma.
- 1.3 Unstable fracture includes rotationally unstable or vertically unstable fractures, please refer to Young and Burgess Classification.¹³

2 Plain radiograph

- 2.1 Anterior-posterior (AP) radiograph of the pelvis is recommended in patients with high clinical suspicion of pelvic fracture.
- 2.2 Additional images, such as pelvic inlet or outlet views, need not be obtained in acute phase of injury.
- 2.3 Plain radiograph can underestimate the extent of bony injury and fracture pattern on plain radiograph does not predict haemorrhage or the need for angiography.

3 CT

- 3.1 CT pelvis is required for haemodynamically stable patients with high-energy pelvic injuries or disruption of pelvic ring.
- 3.2 CT is useful in pre-operative planning of pelvic, sacral and acetabular fractures. 2- and 3-dimensional reformats are useful in selected cases.
- 3.3 CT abdomen and pelvis should be done if intra-abdominal and pelvic injuries are suspected.

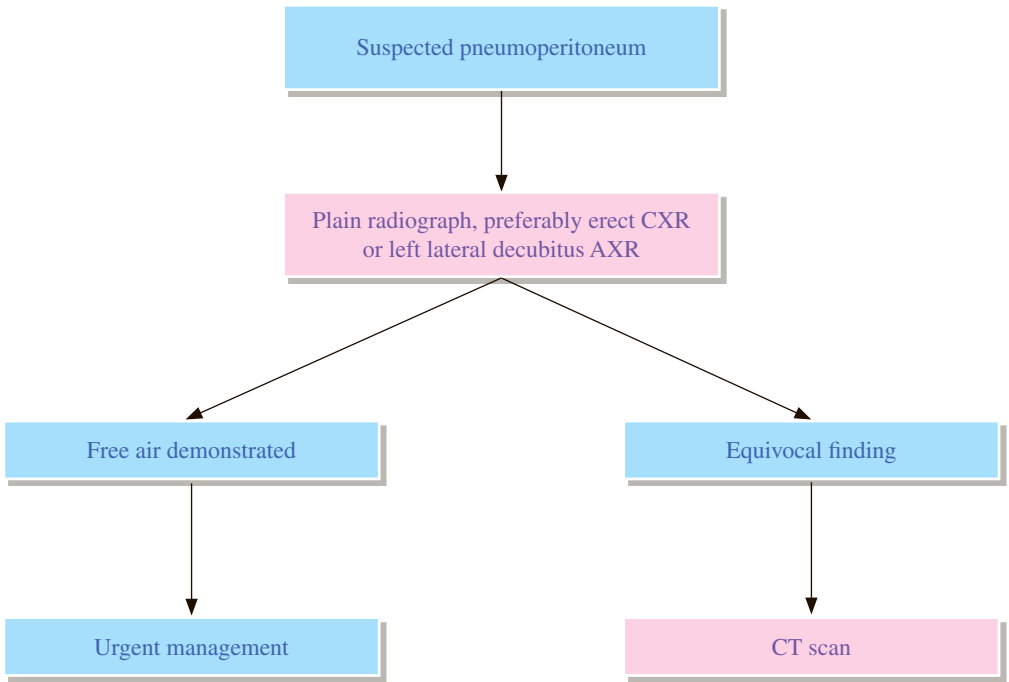
4 Angiography

- 4.1 Angiography with pelvic embolization is useful in patients with pelvic fractures who are haemodynamically unstable.
- 4.2 Patients with evidence of contrast extravasation in pelvis on CT may require pelvic angiography and embolization regardless of haemodynamic status.

REFERENCES

1. Rogers LF. Radiology of skeletal trauma. 2nd edition. New York: Churchill Livingstone; 1992. p. 991-1105.
2. Hunter JC, Brandsen EA, Tran KA. Pelvic and acetabular trauma. Radiol Clin North Am. 1997; 35: 559-590.
3. Montana MA, Richardson ML, Kilcoyne RF, Harley JD, Shuman WP, Mack LA. CT of sacral injury. Radiology. 1986; 161: 499-503.
4. Guy RL, Butler-Manuel PA, Holder P, Brueton RN. The role of 3D CT in the assessment of acetabular fractures. Br J Radiol. 1992; 65: 384-389.
5. Ben-Menachem Y, Coldwell DM, Young JWR, Burgess AR. Haemorrhage associated with pelvic fractures: causes, diagnosis, and emergent management. AJR Am J Roentgenol. 1991; 157: 1005-1014.
6. Hilty MP, Behrendt I, Benneker LM, Martinolli L, Stoupis C, Buggy DJ, Zimmermann H, Exadaktylos AK. Pelvic radiography in ATLS algorithms: A diminishing role? World J Emerg Surg. 2008; 3: 11.
7. Adams JG. Emergency Medicine Clinical Essentials, 2nd ed. Saunders Elsevier; 2013. p. 696-714.
8. Heetveld MJ, Harris I, Schlaphoff G, Sugrue M. Guidelines for the management of haemodynamically unstable pelvic fracture patients. ANZ J Surg. 2004; 74: 520-529.
9. Davis JW, Moore FA, McIntyre RC Jr, Cocanour CS, Moore EE, West MA. Western trauma association critical decisions in trauma: management of pelvic fracture with hemodynamic instability. J Trauma. 2008; 65: 1012-1015.
10. Cullinane DC, Schiller HJ, Zielinski MD, Bilaniuk JW, Collier BR, Como J, Holevar M, Sabater EA, Sems SA, Vassy WM, Wynne JL. Eastern Association for the Surgery of Trauma practice management guidelines for hemorrhage in pelvic fracture--update and systematic review. J Trauma. 2011; 71: 1850-1868.
11. Asadollahi S1, de Steiger R, Gruen R, Richardson M. Management guideline in haemodynamically unstable patients with pelvic fractures: Outcomes and challenges. Emerg Med Australas. 2010; 22: 556-564.
12. Khurana B, Sheehan SE, Sodickson AD, Weaver MJ. Pelvic ring fractures: what the orthopedic surgeon wants to know. Radiographics. 2014; 34: 1317-1333.
13. Young JW, Burgess AR, Brumback RJ, Poka A. Pelvic fractures: value of plain radiography in early assessment and management. Radiology. 1986; 160: 445-451.

GI 3 Suspected pneumoperitoneum



REMARKS

1 Plain radiograph

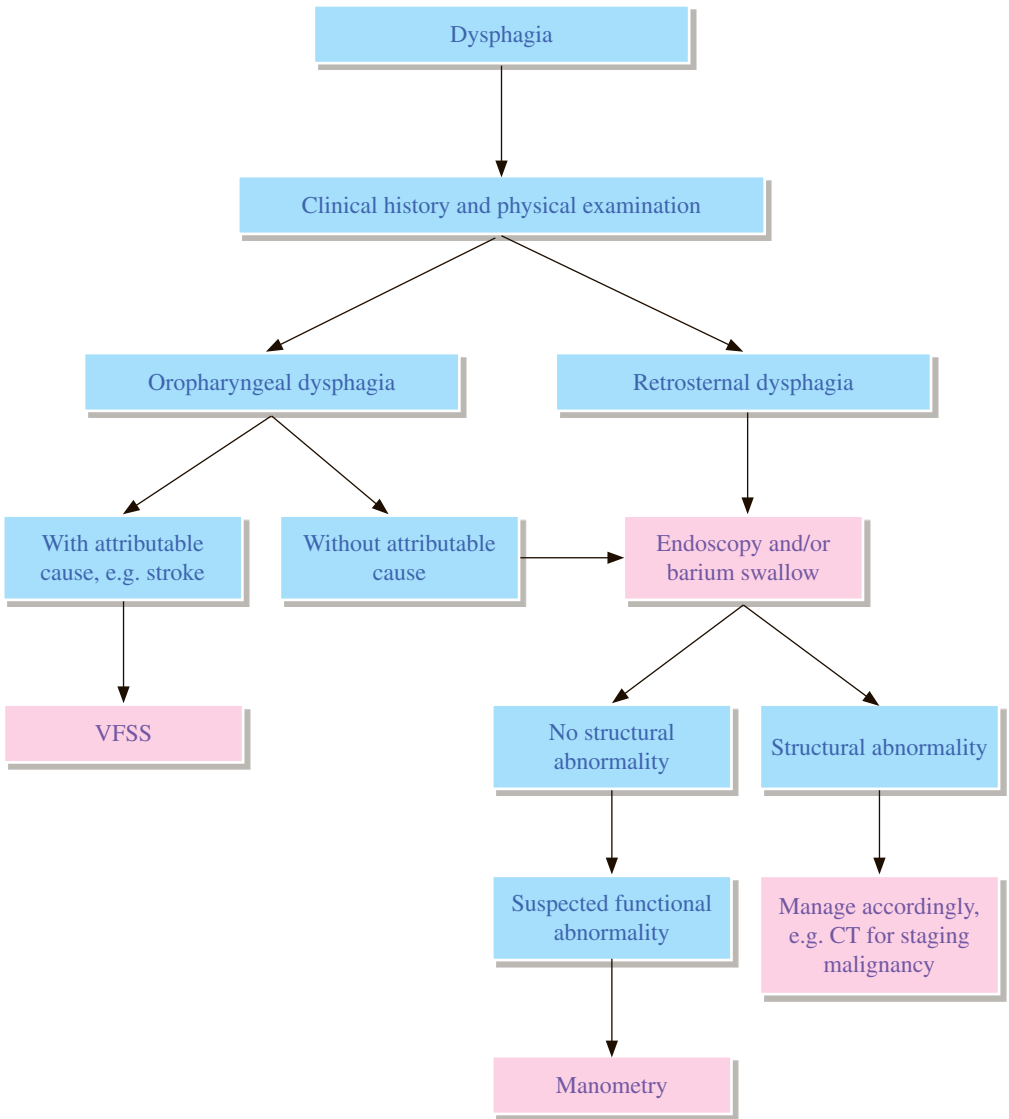
- 1.1 Erect chest X-ray (CXR) is used to detect subphrenic gas.
- 1.2 Left lateral decubitus abdominal X-ray (AXR) also helps to demonstrate free air, especially in ill patients who cannot sit or stand.

2 CT

- 2.1 CT is useful for clarification of equivocal finding on plain radiograph.

REFERENCES

1. Stoker J, van Randen A, Lameris W, Boermeester MA. Imaging Patients with Acute Abdominal Pain. *Radiology*. 2009; 253: 31-46.
2. Chiu YH, Chen JD, Tiu CM, Chou YH, Yen DH, Huang CI, et al. Reappraisal of radiographic signs of pneumoperitoneum at emergency department. *Am J Emerg Med*. 2009; 27: 320-327.



REMARKS

1 General

- 1.1 Dysphagia can be classified by level (oropharyngeal or retrosternal) and aetiology (structural or functional).
- 1.2 Careful history taking often helps to differentiate the level of dysphagia and provides clues about the underlying aetiology, especially for oropharyngeal dysphagia.
- 1.3 Abnormalities of mid & lower oesophagus to gastric cardia may cause referred dysphagia to upper chest or pharynx. Therefore, the oesophagus and gastric cardia should also be assessed in patients with oropharyngeal dysphagia without attributable causes.

2 Barium swallow

- 2.1 Barium swallow and endoscopy are complementary to each other in assessing oesophageal strictures and tumours.
- 2.2 The length and the severity of stenosis are well demonstrated on barium swallow.
- 2.3 Barium swallow can detect motility disorders and it may be more sensitive to detect certain structural abnormalities such as oesophageal webs and rings.
- 2.4 Endoscopy allows biopsies to be taken and is more sensitive to detect mild reflux oesophagitis or other subtle oesophagitis.

3 Video-fluoroscopic swallowing study (VFSS)

- 3.1 VFSS focuses on evaluating the oral cavity, pharynx and cervical oesophagus to access for oral and pharyngeal swallowing phase abnormalities.

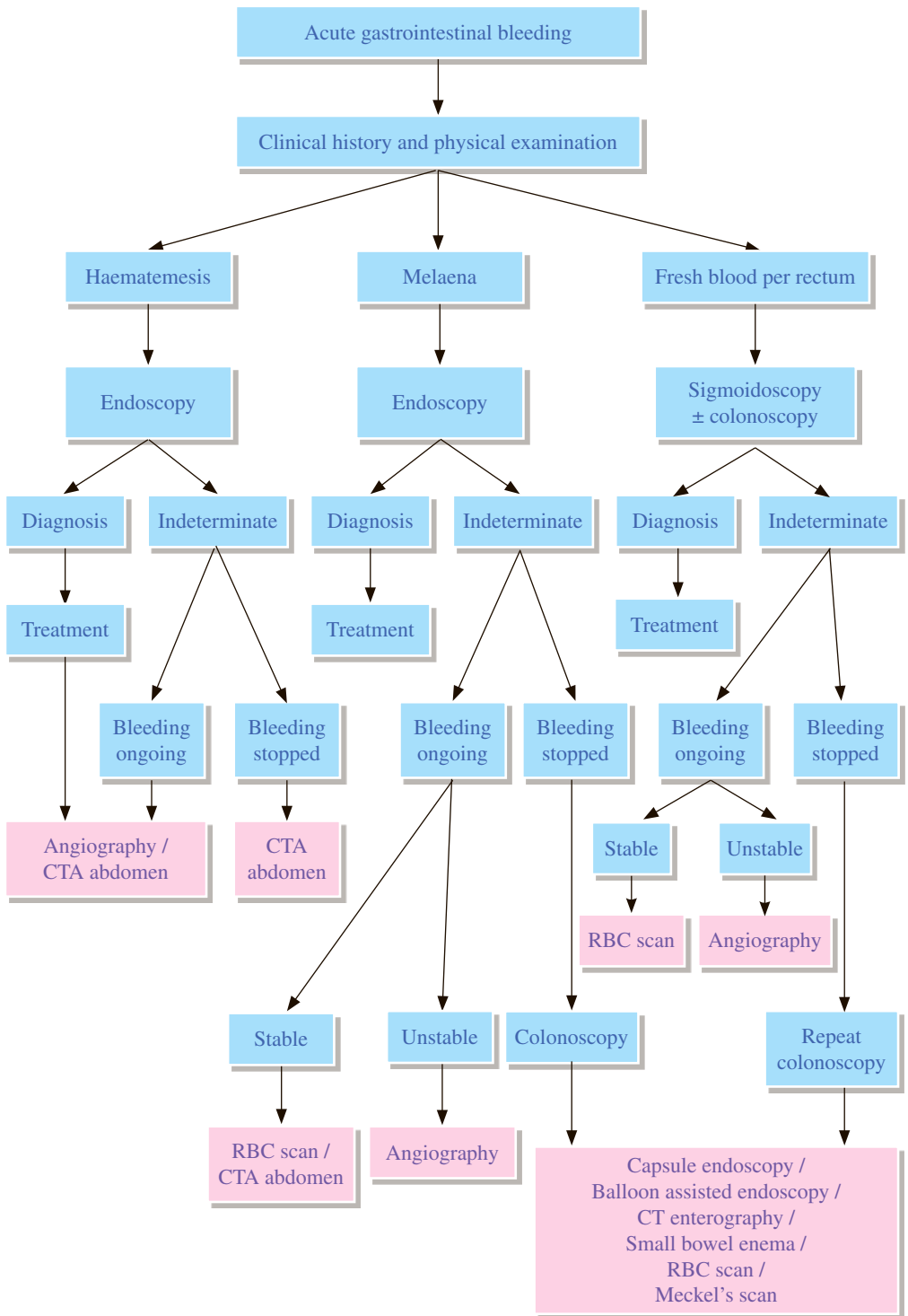
4 CT

- 4.1 CT can be used to assess extrinsic lesions and for tumour staging prior to surgery.

REFERENCES

1. Carucci LR, Lalani T, Rosen MP, et al. ACR Appropriateness Criteria® Dysphagia. Available at <https://acsearch.acr.org/docs/69471/Narrative/>. American College of Radiology. Accessed 2017 April 5.
2. Kuo P, Holloway RH, Nguyen NQ. Current and future techniques in the evaluation of dysphagia. *J Gastroenterol Hepatol.* 2012; 27: 873-881.
3. Malagelada JR, Bazzoli F, Boeckxstaens G, De Looze D, Fried M, Kahrilas P, et al. World Gastroenterology Organisation Global Guidelines: Dysphagia – Global Guidelines and Cascades update September 2014. *J Clin Gastroenterol.* 2015; 49: 370-378.

GI 5 Acute gastrointestinal bleeding



REMARKS

1 Plain radiograph

- 1.1 Abdominal X-ray (AXR) is of no value in diagnosing acute gastrointestinal (GI) bleeding.

2 Small bowel study

- 2.1 Small bowel barium studies may detect Meckel's diverticulum or small bowel tumours. If both small bowel study and angiography are required for investigation of acute GI bleeding, angiography should be performed first.

3 Nuclear medicine

- 3.1 Technetium-99m (Tc-99m) labelled red blood cell (RBC) scan
 - 3.1.1 It is indicated primarily for overt mid or lower GI bleeding.
 - 3.1.2 It is also helpful in identifying the source of obscure GI bleeding.
 - 3.1.3 It can detect a bleeding rate as low as 0.05-0.1ml/min and can help to localize the bleeding site, but errors in localization occur in cases of gastric or duodenal source.
 - 3.1.4 It can localize intermittent bleeding.
- 3.2 Meckel's scan
 - 3.2.1 In a young patient with lower GI bleeding, Meckel's diverticulum has to be considered.

4 CT abdomen (CT angiography & CT enterography)

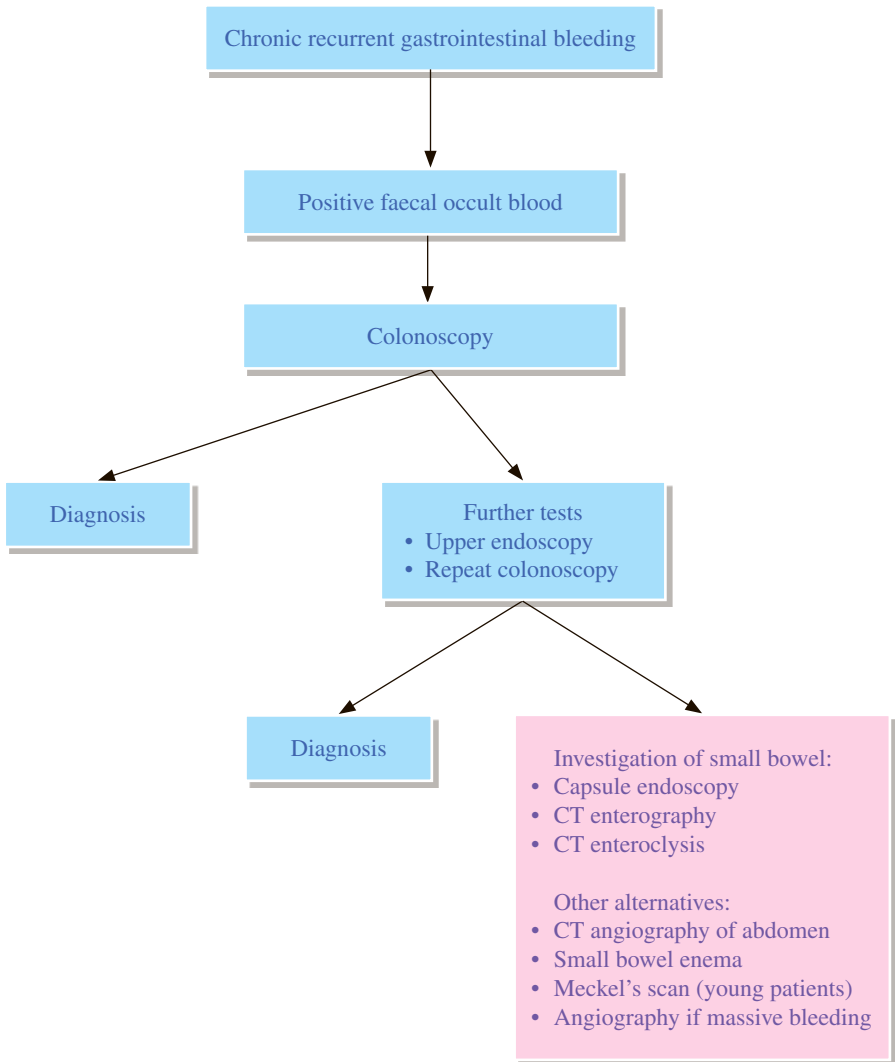
- 4.1 In upper gastrointestinal bleeding (UGIB), it is useful for localizing obscure UGIB, and for work-up in patients with UGIB with prior history of aortic reconstruction or pancreaticobiliary procedure.
- 4.2 In lower gastrointestinal bleeding (LGIB), it can be used to localize LGIB, identify the pathological causes and direct treatment, as well as provide arterial anatomy for treatment planning.
- 4.3 CT enterography or CT enteroclysis is the choice in obscure LGIB when capsule endoscopy is contraindicated, e.g. suspected obstruction or suspected stricture.

5 Angiography

- 5.1 For bleeding to be detected on angiography, it must be active arterial or capillary bleeding, with rate greater than 0.5 ml/min. It is usually not useful in venous bleeding.
- 5.2 The bleeding site can be localized on angiography, and in selected cases, vasopressin infusion or embolization can be used to arrest the bleeding.
- 5.3 Roles in UGIB
 - 5.3.1 In active UGIB when upper endoscopy is unable to control or localize the bleeding source, or when re-bleeding occurs, or when the patient is haemodynamically unstable.
- 5.4 Roles in LGIB
 - 5.4.1 In massive LGIB with haemodynamic instability or heavy transfusion need;
 - 5.4.2 Also allows treatment by means of embolization.

REFERENCES

1. Singh-Bhinder N, Kim DH, Holly BP, et al. ACR Appropriateness Criteria® Nonvariceal Upper Gastrointestinal Bleeding. Available at <https://acsearch.acr.org/docs/69413/Narrative/>. American College of Radiology. Accessed 2017 May 2.
2. Darcy MD, Cash BD, Feig BW, et al. ACR Appropriateness Criteria® Radiologic Management of Lower Gastrointestinal Tract Bleeding. Available at <https://acsearch.acr.org/docs/69457/Narrative/>. American College of Radiology. Accessed 2017 May 2.
3. National Institute for Health and Care Excellence (2013) Acute upper gastrointestinal bleeding in adults. NICE quality standard (QS38).
4. National Institute for Health and Care Excellence (2016) Acute upper gastrointestinal bleeding in over 16s: management. NICE guideline (CG141).
5. Zuccaro G, Jr. Management of the Adult Patient with Acute Lower Gastrointestinal Bleeding. *Am J Gastroenterol.* 1998; 93: 1202-1208.
6. Dam HQ, Brandon DC, Grantham VV, Hilson AJ, Howarth DM, Maurer AH et al. The SNMMI procedure standard/EANM practice guideline for gastrointestinal bleeding scintigraphy 2.0. *J Nucl Med Technol.* 2014; 42: 308-317.
7. Strate LL, Gralnek IM. ACG clinical guideline: management of patients with acute lower gastrointestinal bleeding. *Am J Gastroenterol.* 2016; 111: 459-474.



REMARKS**1 Barium enema**

- 1.1 Vascular lesions such as angiodysplasia may not be detected on barium enema.

2 Small bowel study

- 2.1 Small bowel enema is preferred to follow through study. The diagnostic yield of follow through study is low.
- 2.2 Meckel's diverticulum and small bowel tumours might be detected on small bowel study.

3 Nuclear medicine

- 3.1 Meckel's scan
 - 3.1.1 In a young patient with chronic recurrent gastrointestinal bleeding, Meckel's diverticulum has to be considered.

4 CT enterography or CT enteroclysis

- 4.1 There is no consensus on the diagnostic algorithm for the investigation of small bowel bleeding after exclusion by upper endoscopy and colonoscopy. Capsule endoscopy is generally regarded as the first line investigation.
- 4.2 CT enterography or CT enteroclysis are alternatives, especially in patients with contraindications to capsule endoscopy such as:
 - 4.2.1 Suspected obstruction
 - 4.2.2 Suspected stricture

5 CT angiography of abdomen

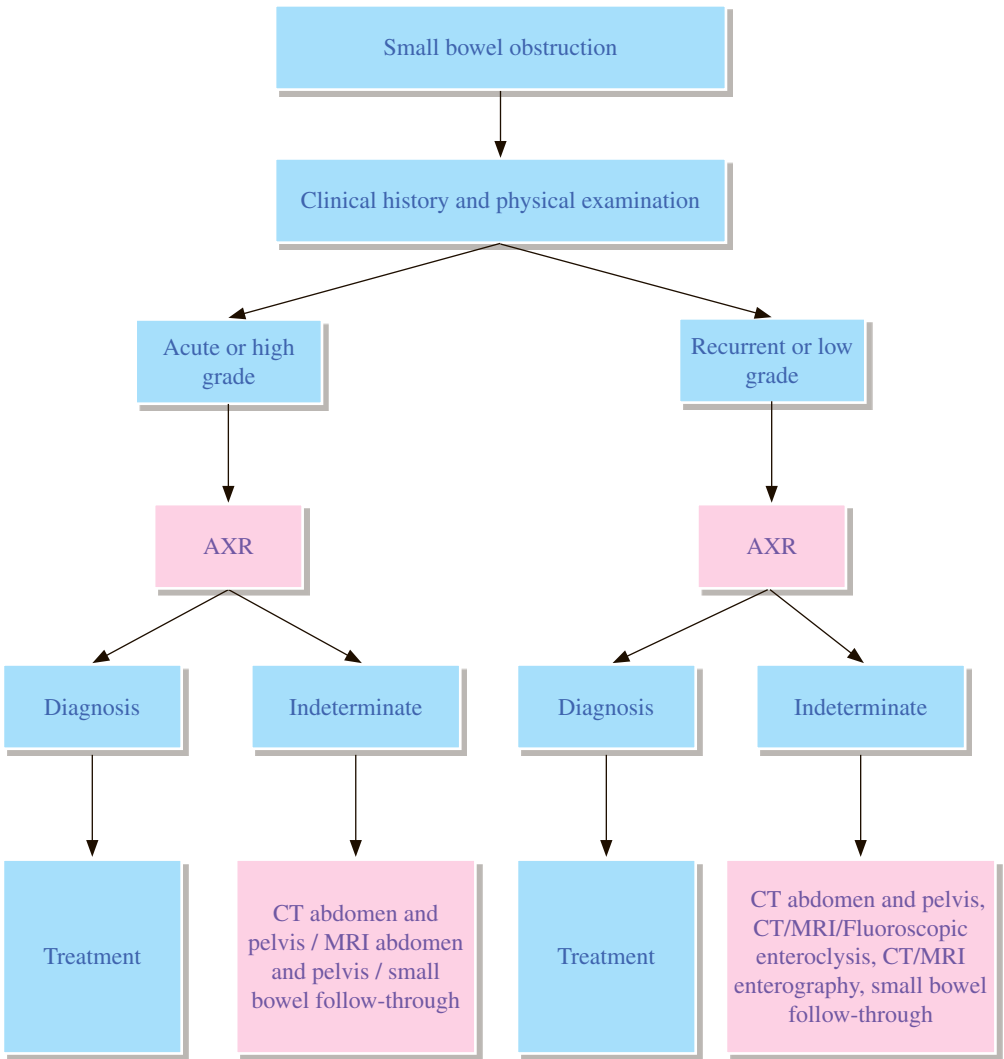
- 5.1 CT angiography of abdomen is useful in patients with active bleeding, chronic bleeding not localized by other means, for diagnosing underlying pathological causes and vascular causes, and for planning angiography and endovascular intervention.

6 Angiography

- 6.1 Catheter angiography is helpful in conditions of massive gastrointestinal bleeding and chronic bleeding not localized by other means; it can provide treatment by means of embolization.

REFERENCES

1. Owensby S, Taylor K, Wilkins T. Diagnosis and Management of Upper Gastrointestinal Bleeding in Children. *J Am Board Fam Med.* 2015; 28: 134-145.
2. Romano C, Oliva S, Martelossi S, Miele E, Arrigo S, Graziani MG, et al. Pediatric gastrointestinal bleeding: Perspectives from the Italian Society of Pediatric Gastroenterology. *World J Gastroenterol.* 2017; 23: 1328-1337.
3. The Royal College of Radiologists. *iRefer: Making the best use of clinical radiology.* 8th ed. London: The Royal College of Radiologists; 2017. Section P27.
4. The Royal College of Radiologists. *iRefer: Making the best use of clinical radiology.* 8th ed. London: The Royal College of Radiologists; 2017. Section G10.



REMARKS

1 Plain radiograph

- 1.1 Often the first line investigation to detect the presence of obstruction.¹
- 1.2 Useful to establish if bowel obstruction is high or low grade.²
- 1.3 For patients in whom a strong clinical suspicion of small bowel obstruction is present, consideration should be given to immediate cross-sectional imaging, particularly CT.³

2 CT

- 2.1 Standard CT, performed with an intravenous (IV) contrast if possible, but generally without oral contrast, is the primary imaging modality for evaluating small bowel obstruction and should be strongly considered in the initial evaluation of patients with suspected high-grade small bowel obstruction.³
- 2.2 When abdominal X-ray (AXR) is equivocal and low-grade, and subacute small bowel obstruction is suspected clinically, CT enteroclysis has a higher site-specific sensitivity and specificity than standard CT.²

3 Small bowel study

- 3.1 In suspected small bowel obstruction due to adhesions, presence of water-soluble contrast in the colon on a plain radiograph obtained 24 hours after oral administration of 100 ml water-soluble contrast medium is a good predictor of resolution without operation.²
- 3.2 Fluoroscopic small bowel examinations play a much less substantial role and should not be used as a primary imaging modality in diagnosing an acute small bowel obstruction.³
- 3.3 If intermittent, recurrent, or low-grade small bowel obstruction is a primary concern, an enteroclysis is likely the next best test.³

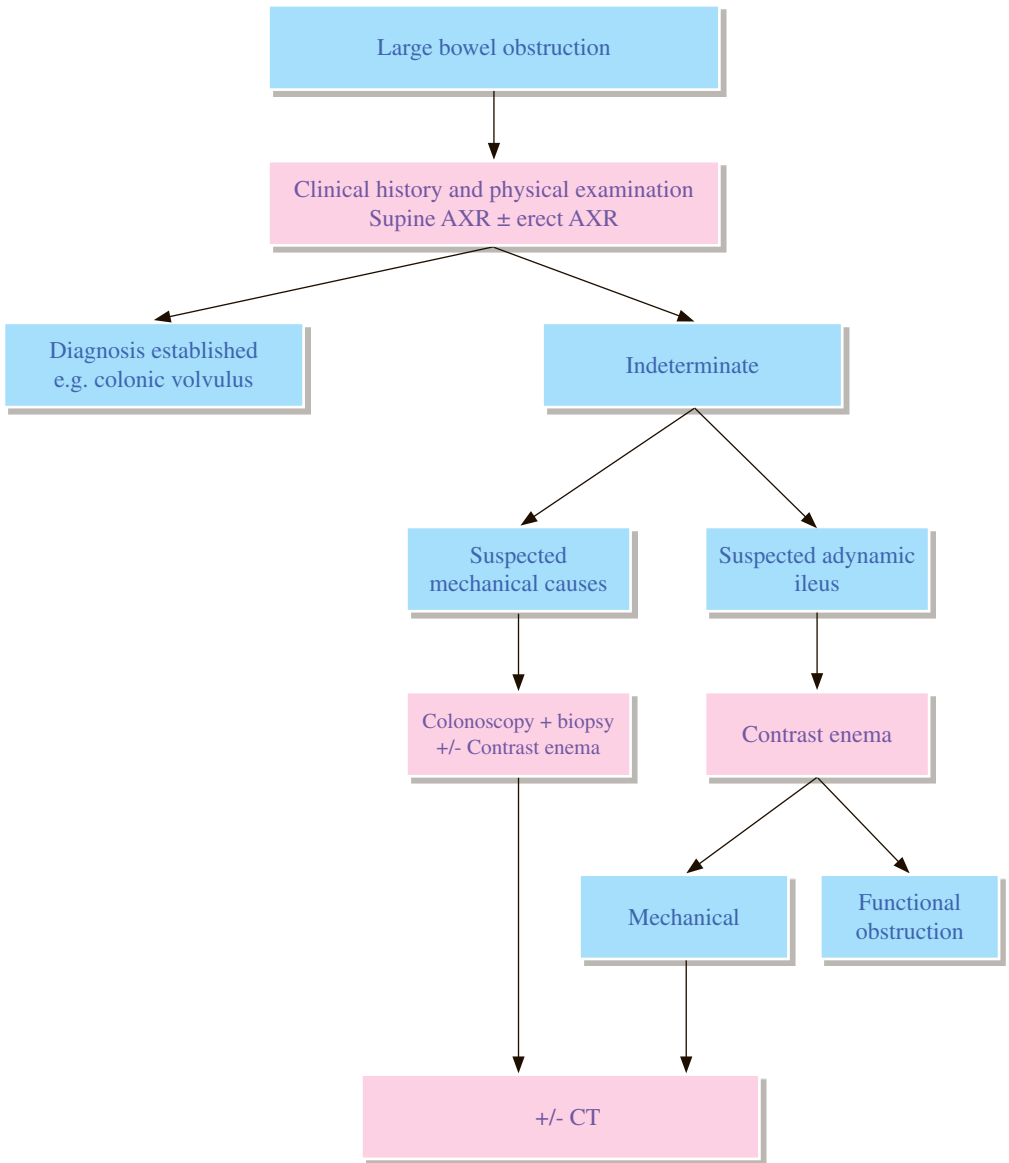
4 MRI

- 4.1 Children and in particular pregnant patients with known or suspected small bowel obstruction, as well as younger patients with repeated episodes of obstruction, are the ideal population to undergo MRI. In pregnant patients, only non-contrast sequences are obtained. In non-pregnant individuals, sequences with or without IV gadolinium contrast can be performed.³

REFERENCES

1. Canadian Association of Radiologists. 2012 CAR Diagnostic Imaging Referral Guidelines. Ottawa: Canadian Association of Radiologists; 2012. Section G13-G14.
2. The Royal College of Radiologists. iRefer: Making the best use of clinical radiology. 7th ed. London: The Royal College of Radiologists; 2012. Section G13-G14.
3. Katz DS, Baker ME, Rosen MP, et al. ACR Appropriateness Criteria® Suspected Small-Bowel Obstruction. Available at <https://acsearch.acr.org/docs/69476/Narrative/>. American College of Radiology. Accessed 2017 April 6.

GI 8 Large bowel obstruction



REMARKS

1 Plain radiograph

- 1.1 When acute large bowel obstruction is suspected, abdominal X-ray (AXR) may be used as an initial examination to help establish the diagnosis and to indicate the likely level.¹
- 1.2 Erect AXR is not indicated routinely. It may be taken when supine AXR is normal but there is strong clinical suspicion of bowel obstruction.

2 CT

- 2.1 CT is the investigation of choice after AXR. It will confirm the diagnosis, delineate the level of acute large bowel obstruction and can also identify the cause.²
- 2.2 CT is also used for evaluation of extrinsic lesions and for staging of confirmed carcinoma.

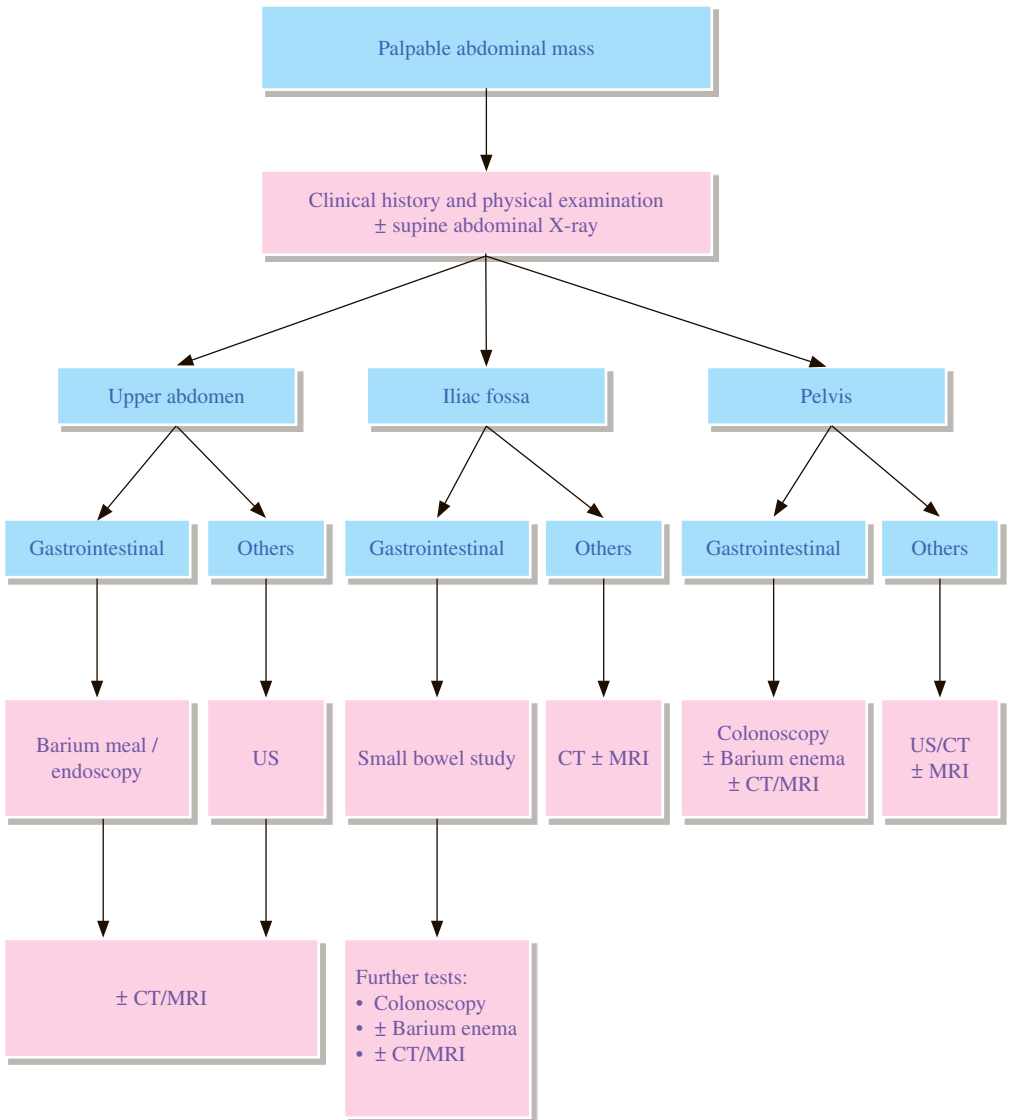
3 Contrast enema

- 3.1 Helps to exclude pseudo-obstruction.
- 3.2 May consider it for problem solving if CT is not available or equivocal.¹

REFERENCES

1. Canadian Association of Radiologists. 2012 CAR Diagnostic Imaging Referral Guidelines. Ottawa: Canadian Association of Radiologists; 2012. Section G17.
2. The Royal College of Radiologists. iRefer: Making the best use of clinical radiology. 7th ed. London: The Royal College of Radiologists; 2012. Section G17.

GI 9 Palpable abdominal mass



REMARKS

1 General

- 1.1 The choice of examination depends on the symptoms and the organs suspected to be abnormal.
- 1.2 US and CT should precede barium studies to avoid barium related artefacts.

2 Plain radiograph

- 2.1 Plain radiograph is of limited value.

3 Fluoroscopy

- 3.1 Request should clearly indicate areas of interest so that the most appropriate studies can be employed, e.g. small bowel enema for small bowel lesions.

4 US

- 4.1 US is useful in hepatobiliary system, kidneys and female pelvis but may be limited by bowel gas in both iliac fossae.

5 CT

- 5.1 CT is a useful alternative to US to exclude a lesion especially in obese patients and to provide excellent survey of the abdominal organs and retroperitoneum.

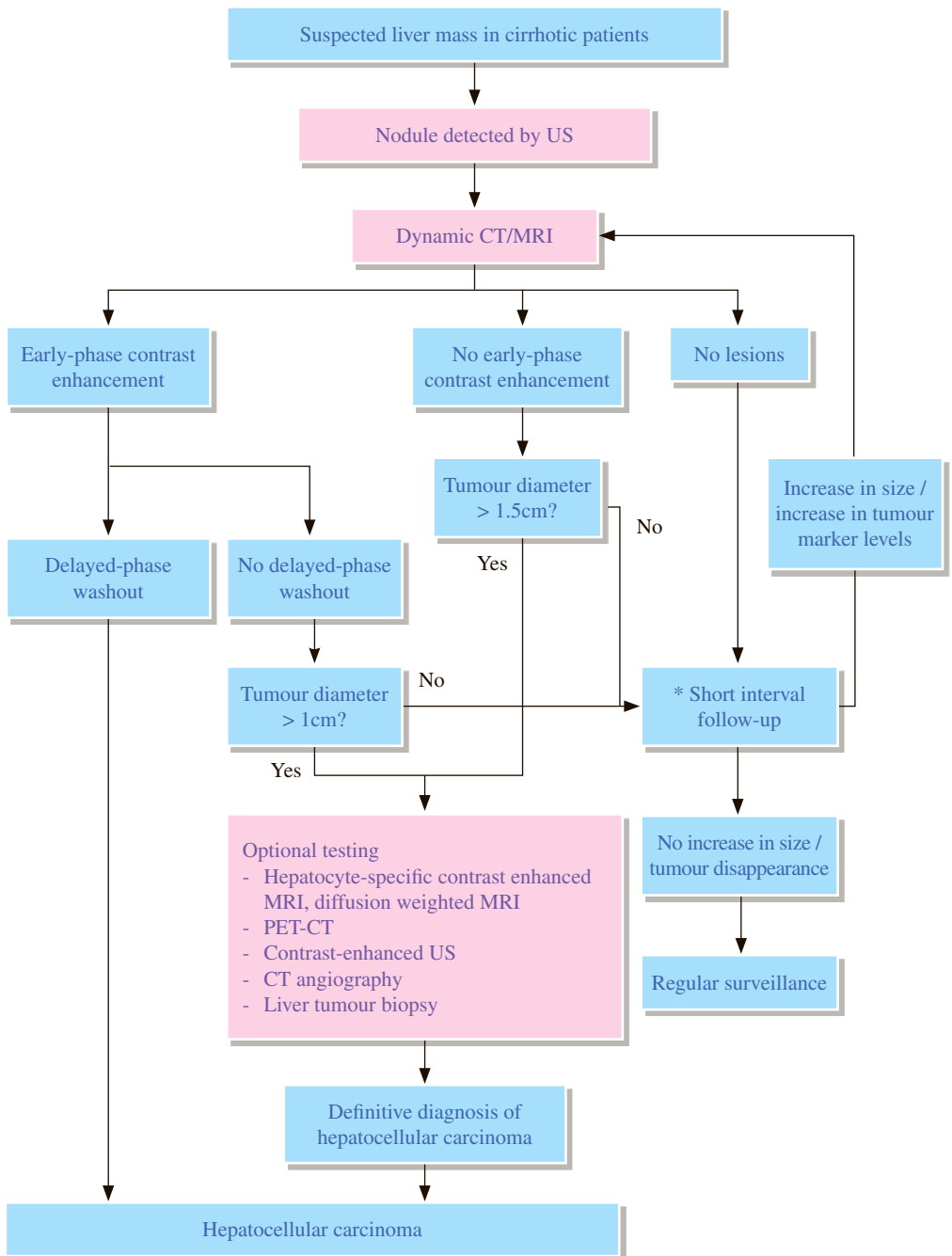
6 MRI

- 6.1 MRI may be used to evaluate complex lesions not definitely characterized by US or CT.²

REFERENCES

1. The Royal College of Radiologists. iRefer: Making the best use of clinical radiology. 7th ed. London: The Royal College of Radiologists; 2012. Section G21.
2. Yaghami V, Yee J, Cash BD, et al. ACR Appropriateness Criteria® Palpable Abdominal Mass. Available at <https://acsearch.acr.org/docs/69473/Narrative/>. American College of Radiology. Accessed 2017 May 20.

GI 10 Suspected liver mass in cirrhotic patients



* 3rd JSH HCC Evidence-based guidelines recommend 3 months interval. Actual time interval for investigation and choice of tests will vary between hospitals depending on resources and machine availability.

REMARKS

1 General

- 1.1 Radiological investigations are essential in detecting hepatomegaly (and its cause) and liver masses. It is useful in differentiating benign and malignant hepatic lesions and in assessing the resectability of liver tumours.
- 1.2 The American Association for the Study of Liver Disease (AASLD) and European Association for the Study of Liver (EASL) guidelines propose a diagnostic algorithm starting from the tumor size, whereas the Asian Pacific Association for the Study of the Liver (APASL) and Japanese Society of Hepatology (JSH) guidelines recommend an algorithm starting from arterial tumour vascularity (hyper- or hypovascular in the arterial phase).

2 US

- 2.1 US is the best initial imaging modality as it is non-invasive and sensitive in detecting liver lesions. It is a screening test and not a diagnostic test for confirmation.
- 2.2 Contrast-enhanced US is considered as sensitive as dynamic CT or MRI in the diagnosis of hepatocellular carcinoma (HCC).

3 CT and MRI

- 3.1 Dynamic CT or MRI is recommended as a first-line diagnostic tool for HCC when a screening test result is abnormal.
- 3.2 Hallmark of HCC during CT or MRI is the presence of arterial enhancement, followed by washout of the tumour in the portal-venous and/or delayed phases. The AASLD and EASL guidelines accept only four-phase CT and dynamic contrast MRI for HCC diagnosis, whereas the APASL and JSH guidelines also accept contrast-enhanced US.
- 3.3 Various studies have verified the usefulness of liver specific contrast enhanced MRI. It is included in the Japanese Society of Hepatology Liver Cancer Study Group 2014 Surveillance and Diagnostic Algorithm of HCC.

4 Nuclear Medicine

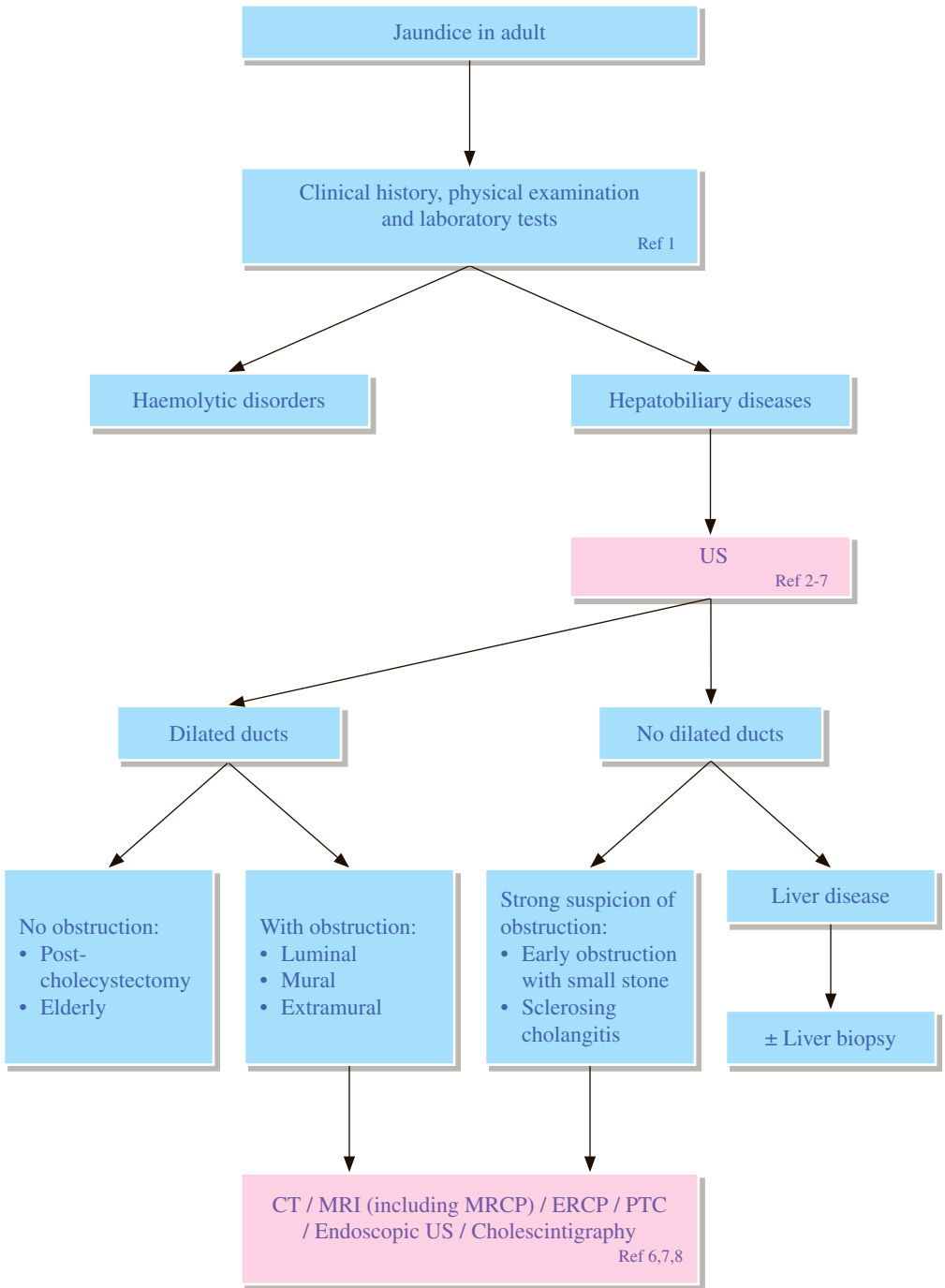
- 4.1 Fluorodeoxyglucose (FDG) PET has limited sensitivity for well differentiated HCC. Its low sensitivity is due to low uptake in well-differentiated HCC. However, focal FDG hypermetabolism in liver suggests high likelihood of malignancy (primary or secondary). False positive includes liver abscess.
- 4.2 For identification of intrahepatic HCC lesions, limited evidence found PET with C-11 acetate and other alternative tracers such as F-18 fluorocholine and F-18 fluorothymidine have substantially higher sensitivity than F-18 FDG PET. Currently PET is not a routine diagnostic tool according to most of the international guidelines.
- 4.3 F-18 FDG PET-CT was useful in ruling in extrahepatic metastases of HCC and valuable for ruling out recurrent HCC.
- 4.4 Tc-99m sulfur colloid scintigraphy (+/- Tc-99m mebrofenin scintigraphy) is helpful in differentiation of focal nodular hyperplasia from other hepatic lesions that do not contain Kupffer cells (e.g. hepatic adenoma and HCC).

5 Angiography

- 5.1 Angiography does not assume a major diagnostic role in modern liver imaging and is superseded by CT and MRI.

REFERENCES

1. Bruix J, Sherman M. American Association for the Study of Liver Disease: Management of hepatocellular carcinoma: an update. *Hepatology*. 2011; 53: 1020-1022.
2. European Association for the Study of the Liver: European Organisation for Research and Treatment of Cancer: EASL-EORTC clinical practice guidelines: management of hepatocellular carcinoma. *J Hepatol*. 2012; 56: 908-943.
3. Omata M, Lesmana LA, Tateishi R, Chen PJ, Lin SM, Yoshida H, et al. Asian Pacific Association for the Study of the Liver consensus recommendations on hepatocellular carcinoma. *Hepatology*. 2010; 4: 439-474.
4. The Japan Society of Hepatology. Clinical practice guidelines for hepatocellular carcinoma 2013. Tokyo: The Japan Society of Hepatology; 2013.
5. Kudo M, Matsui O, Izumi N, Iijima H, Kadoya M, Imai Y, et al. Liver Cancer Study Group of Japan: JSH Consensus-based Clinical Practice Guideline for the Management of Hepatocellular Carcinoma: 2014 Update by the Liver Cancer Study Group of Japan. *Liver Cancer*. 2014; 3: 458-468.
6. Bota S, Piscaglia F, Marinelli S, Pecorelli A, Terzi E, Bolondi L. Comparison of International Guidelines for Noninvasive Diagnosis of Hepatocellular Carcinoma. *Liver Cancer*. 2012; 1: 190-200.
7. Ye F, Liu J, Ouyang H. Gadolinium Ethoxybenzyl Diethylenetriamine Pentaacetic Acid (Gd-EOB-DTPA)-Enhanced Magnetic Resonance Imaging and Multidetector-Row Computed Tomography for the Diagnosis of Hepatocellular carcinoma: A Systemic Review and Meta-analysis. *Medicine (Baltimore)*. 2015; 94: e1157.
8. Jungiang L, Yinzhong W, Li Z, Shunlin G, Xiaohui W, Yanan Z, et al. Gadoteric acid disodium (Gd-EOBDTPA)-enhanced magnetic resonance imaging for the detection of hepatocellular carcinoma: a meta-analysis. *J Magn Reson Imaging*. 2014; 39: 1079-1087.
9. Liu X, Zou L, Liu F, Zhou Y, Song B. Gadoteric Acid Disodium-Enhanced Magnetic Resonance Imaging for the Detection of Hepatocellular Carcinoma: A Meta-analysis. *PLoS ONE*. 2013; 8: e70896.
10. Chen L, Zhang L, Liang M, Bao J, Zhang J, Xia Y, et al. Magnetic resonance imaging with gadoteric acid disodium for the detection of hepatocellular carcinoma: a meta-analysis of 18 studies. *Acad Radiol*. 2014; 21: 1603-1613.
11. Chou R, Cuevas C, Fu R, Devine B, Wasson N, Ginsburg A, et al. Imaging Techniques for the Diagnosis and Staging of Hepatocellular Carcinoma. Comparative Effectiveness Review No. 143. Rockville: Agency for Health Research and Quality (US); 2014 October.
12. Ho CL, Yu SC, Yeung DW. 11C-acetate PET imaging in hepatocellular carcinoma and other liver masses. *J Nucl Med*. 2003; 44: 213-221.
13. Ho CL, Chen S, Yeung DW, Cheng TK. Dual-tracer PET/CT imaging in evaluation of metastatic hepatocellular carcinoma. *J Nucl Med*. 2007; 48: 902-909.
14. Park JW, Kim JH, Kim SK, Kang KW, Park KW, Choi JI, et al. A prospective evaluation of 18F-FDG and 11C-acetate PET/CT for detection of primary and metastatic hepatocellular carcinoma. *J Nucl Med*. 2008; 49: 1912-1921.
15. Lin CY, Chen JH, Liang JA, Lin CC, Jeng LB, Kao CH. 18F-FDG PET or PET/CT for detecting extrahepatic metastases or recurrent hepatocellular carcinoma: a systematic review and meta-analysis. *Eur J Radiol*. 2012; 81: 2417-2422.
16. Delbeke D, Martin WH, Sandler MP, Chapman WC, Wright JK Jr, Pinson CW. Evaluation of benign vs malignant hepatic lesions with positron emission tomography. *Arch Surg*. 1998; 133: 510-515.
17. American College of Radiology. ACR-SNMMLI-SPR Practice Guideline for the Performance of Liver and Spleen Scintigraphy. Revised 2010 (Resolution 27). Reston: American College of Radiology; 2010.



REMARKS

1 US

- 1.1 US is a non-invasive, accurate and reliable technique for assessing the gallbladder, common bile duct and intrahepatic ducts, and should be employed as the primary investigation for evaluating the biliary system. It is also valuable in the detection of liver diseases.
- 1.2 US detection of pancreatic lesion is less reliable in certain patients, mainly due to overlying bowel gas.

2 Nuclear medicine

- 2.1 In very early biliary obstruction, nuclear medicine may be useful as US may not detect abnormality in the liver. Alternatively, a repeat US may show progressively dilated bile ducts. US is preferred as the initial screening test to provide anatomic details of the bile ducts.
- 2.2 Hepatobiliary scintigraphy provides a non-invasive method for evaluation of biliary system patency.

3 CT

- 3.1 CT is indicated when tumour is suspected and when US is inadequate.
- 3.2 It is very sensitive in detecting gallstones, air in the biliary tree and extrahepatic lesions obscured by bowel gas on US.

4 MRI

- 4.1 MRI can demonstrate both the site and cause of biliary obstruction. For detection of ductal calculi, magnetic resonance cholangiopancreatography (MRCP) is the most sensitive non-invasive technique.⁶

5 Cholangiography

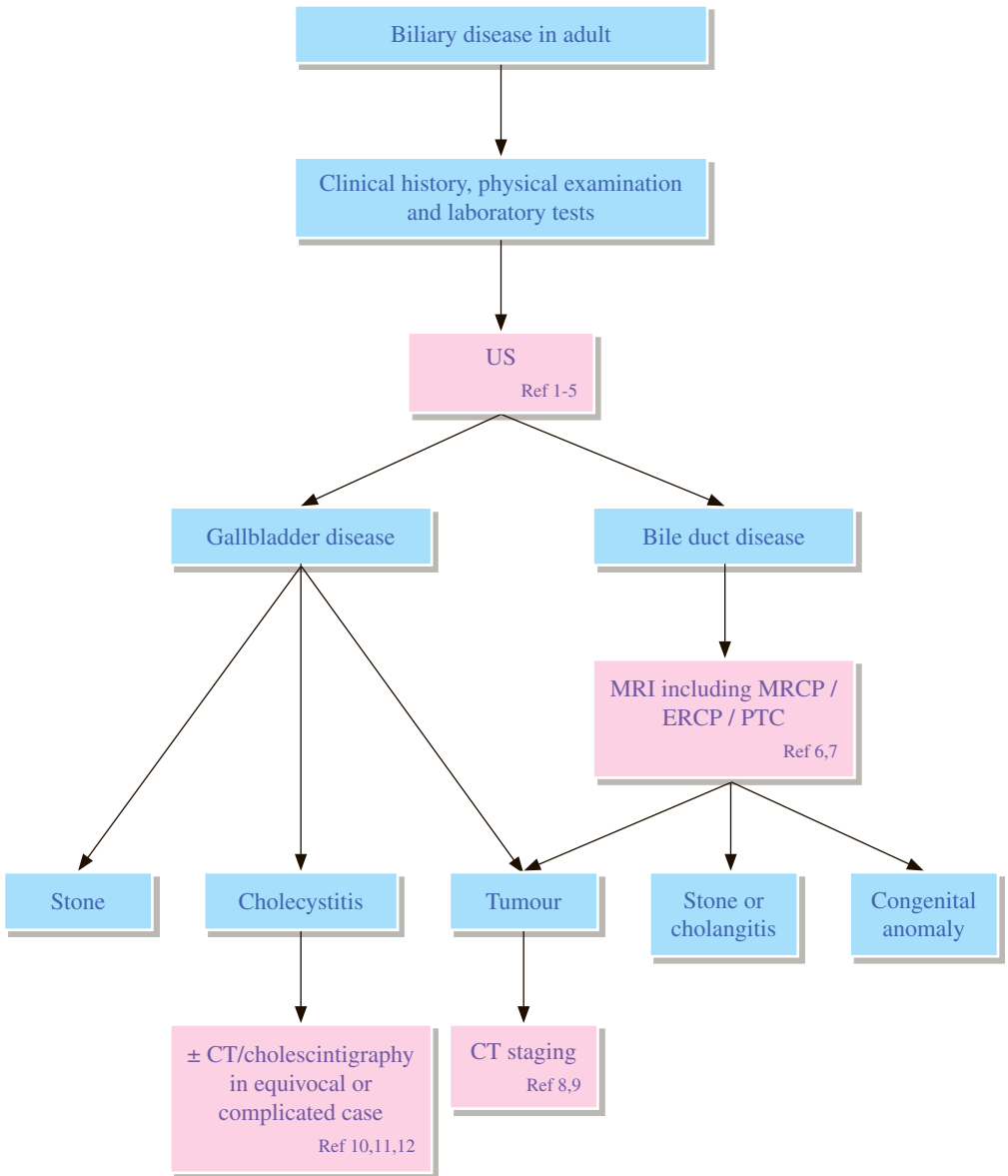
- 5.1 Cholangiography by endoscopic retrograde cholangiopancreatography (ERCP) or percutaneous transhepatic cholangiogram (PTC) is the definitive imaging modality in the assessment of the biliary tree but both are invasive. ERCP is better for low obstruction while PTC is more reliable for high obstruction.
- 5.2 Due to significant advances in cross-sectional imaging, in particular the advent of MRCP, ERCP currently has an almost exclusively therapeutic role. The main indication for ERCP remains management of common bile duct stones. It also remains the standard for stent placement in cases of obstructive jaundice.⁶

6 Endoscopic US

- 6.1 Endoscopic US is the most accurate method for the detection of small ductal stones and small papillary or periampullary tumours. It allows biopsy of the pancreas without risk of tumour seeding.

REFERENCES

1. Moseley RH. Evaluation of abnormal liver function tests. *Med Clin North Am.* 1996; 80: 887-906.
2. Baron RL, Stanley RJ, Lee JKT, Koehler RE, Melson GL, Balfe DM, et al. A prospective comparison of the evaluation of biliary obstruction using computed tomography and ultrasonography. *Radiology.* 1982; 145: 91-98.
3. Mittelstaedt CA. Ultrasound of bile ducts. *Semin Roentgenol.* 1997; 32: 161-171.
4. Baron RL. Computed tomography of the bile ducts. *Semin Roentgenol.* 1997; 32: 172-187.
5. Robledo R, Muro A, Prieto ML. Extrahepatic bile duct carcinoma: US characteristics and accuracy in demonstration of tumors. *Radiology.* 1996; 198: 867-873.
6. Lalani T, Couto CA, Rosen MP, et al. ACR Appropriateness Criteria@ Jaundice. Available at <https://acsearch.acr.org/docs/69497/Narrative/>. American College of Radiology. Accessed 2017 June 2.
7. The Royal College of Radiologists. iRefer: Making the best use of clinical radiology. 7th ed. London: The Royal College of Radiologists; 2012. Section G27.
8. Shlansky-Goldbery R, Weintraub J. Cholangiography. *Semin Roentgenol.* 1997; 32: 150-160.
9. Tulchinsky M, Ciak BW, Delbeke D, Hilson A, Holes-Lewis KA, Stabin MG, et al. SNM Practice Guideline for Hepatobiliary Scintigraphy 4.0. *J Nucl Med Technol.* 2010; 38: 210-218.



REMARKS

1 Plain radiograph

- 1.1 Abdominal X-ray (AXR) is not indicated as the majority of gallstones are not radio-opaque.

2 US

- 2.1 US is the initial imaging modality of choice in the work-up of suspected biliary disease as it is sensitive to diagnose gallstones and gallbladder diseases.
- 2.2 Although cholescintigraphy is recognized to have a higher sensitivity and specificity, US remains the initial test of choice for imaging patients with suspected acute cholecystitis for a variety of reasons, including greater availability, shorter study time, lack of ionizing radiation, morphologic evaluation, confirmation of the presence or absence of gallstones, evaluation of intrahepatic and extrahepatic bile ducts, and identification or exclusion of alternative diagnoses.¹¹

3 CT

- 3.1 CT plays an important role in the detection of complications of acute cholecystitis in patients who fail to improve on conventional treatment.¹⁰
- 3.2 CT also plays a role in the staging of malignant biliary disease. It has the advantage of detecting extrahepatic metastases.

4 MRI

- 4.1 MRI including magnetic resonance cholangiopancreatography (MRCP) is a non-invasive method to assess the biliary tree.

5 Cholangiography

- 5.1 Endoscopic retrograde cholangiopancreatography (ERCP) and percutaneous transhepatic cholangiogram (PTC) provide direct imaging of the biliary tree but are not very reliable in diagnosing gallbladder calculi. Stone extraction can be performed at the same time during ERCP.
- 5.2 PTC is good for hilar ductal obstruction and its management.

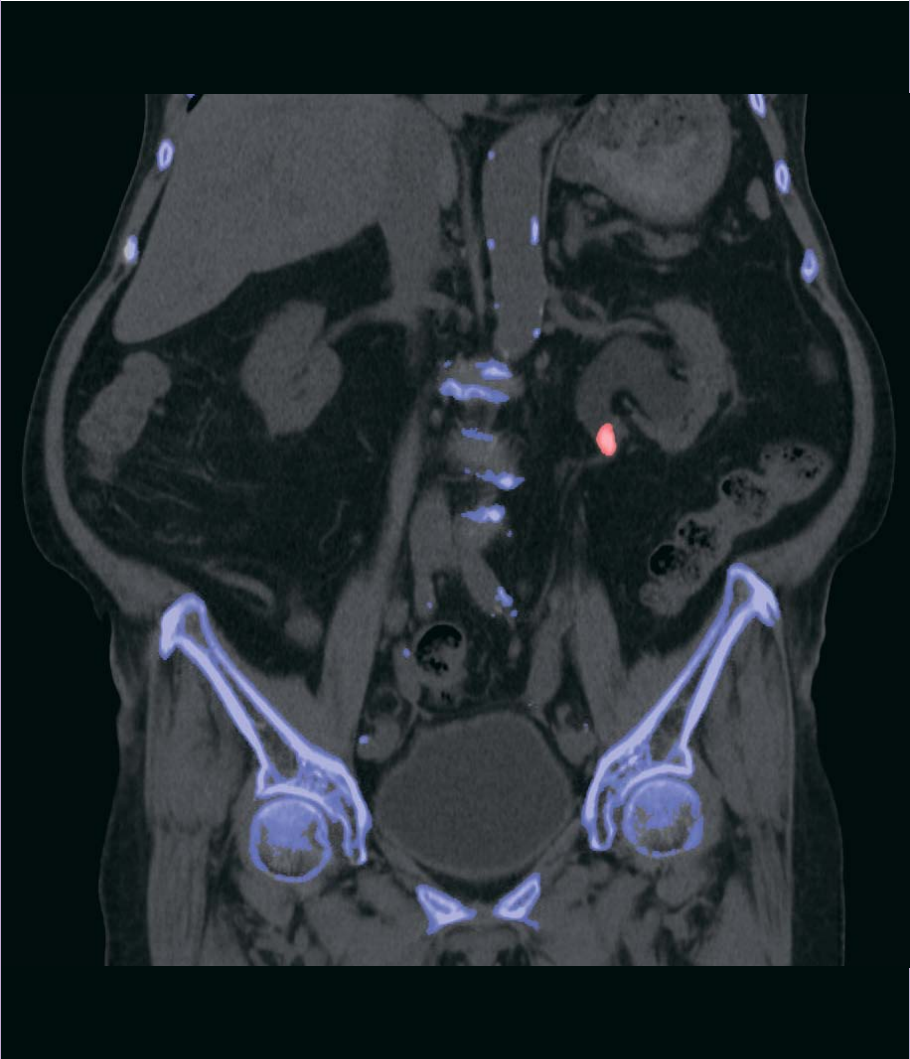
6 Cholescintigraphy

- 6.1 Cholescintigraphy has the highest sensitivity and specificity in patients suspected with acute cholecystitis.¹³ In clinically equivocal cases, cholescintigraphy should be considered.
- 6.2 Cholescintigraphy is indicated in a number of hepatobiliary diseases,¹² including: acute cholecystitis, chronic cholecystitis (with gallbladder ejection fraction calculation), functional biliary pain syndromes, sphincter of Oddi dysfunction, assessment of biliary system patency and bile leakage, liver transplant assessment etc.

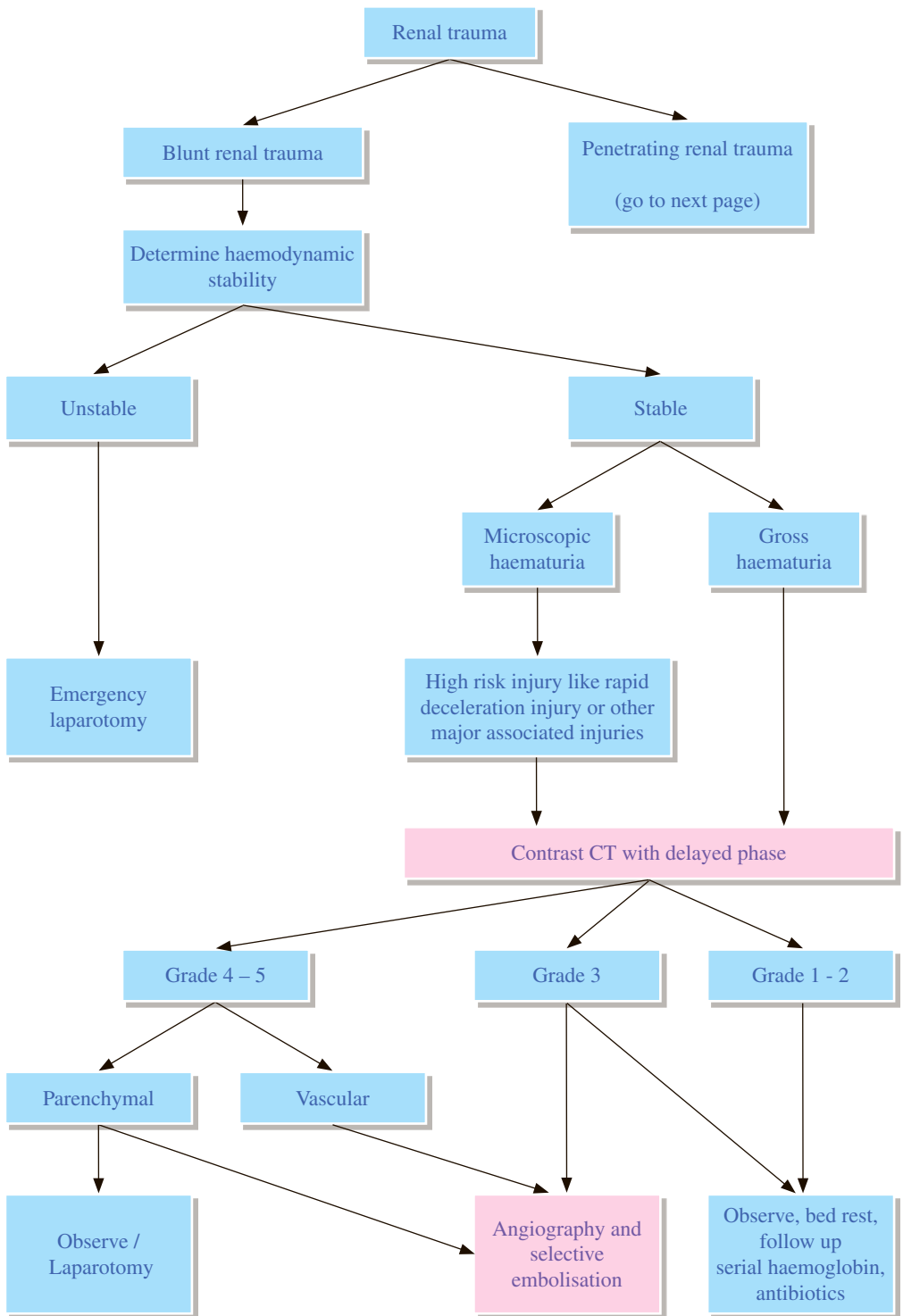
REFERENCES

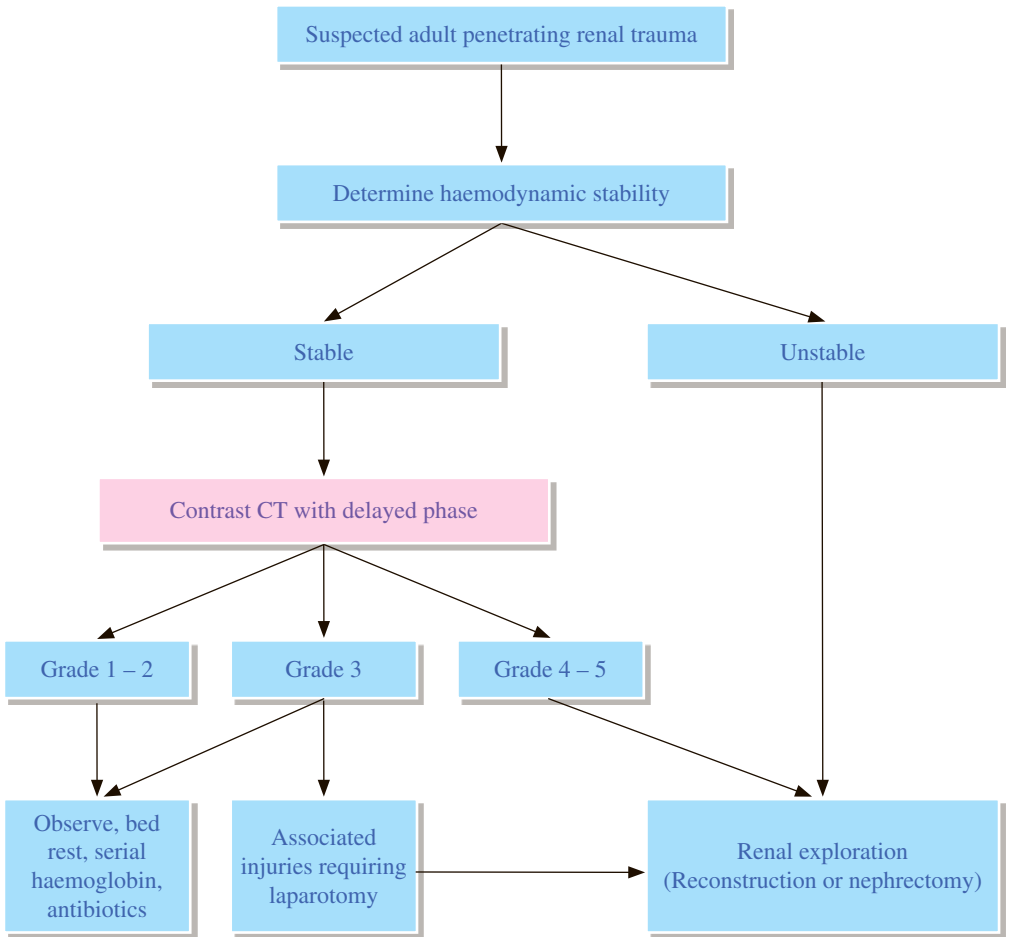
1. Lim JH, Ko YT, Kim SY. Ultrasound changes of the gallbladder wall in cholecystitis: a sonographic-pathological correlation. *Clin Radiol.* 1987; 38: 389-393.
2. Mittelstaedt CA. Ultrasound of bile ducts. *Semin Roentgenol* 1997; 32: 161-171.
3. Feng B, Song Q. Does the common bile duct dilate after cholecystectomy? - sonographic evaluation in 234 patients. *AJR Am J Roentgenol.* 1995; 165: 859-861.
4. Robledo R, Muro A, Prieto ML. Extrahepatic bile duct carcinoma: US characteristics and accuracy in demonstration of tumors. *Radiology.* 1996; 198: 867-873.
5. Chang VH, Cunningham JJ, Fromkes JJ. Sonographic measurement of the extrahepatic bile duct before and after retrograde cholangiography. *AJR Am J Roentgenol.* 1985; 144: 753-755.
6. Sirinek KR, Levine BA. Percutaneous transhepatic cholangiography and biliary decompression - invasive, diagnostic, and therapeutic procedures with too high a price?. *Arch Surg.* 1989; 124: 885-888.
7. Elias E, Hamlyn AN, Jain S, Long RG, Summerfield JA, Dick R, et al. A randomized trial of percutaneous transhepatic cholangiography with the Chiba needle versus endoscopic retrograde cholangiography for bile duct visualization in jaundice. *Gastroenterology.* 1976; 71: 439-443.
8. Fleischmann D, Ringl H, Schofl R, Potzi R, Kontrus M, Henk C, et al. Three-dimensional spiral CT cholangiography in patients with suspected obstructive biliary disease: comparison with endoscopic retrograde cholangiography. *Radiology.* 1996; 198: 861-868.
9. Gulliver DJ, Baker ME, Cheng CA, Meyers WC, Pappas TN. Malignant biliary obstruction: efficacy of thin-section dynamic CT in determining resectability. *AJR Am J Roentgenol.* 1992; 159: 503-507.
10. The Royal College of Radiologists. iRefer: Making the best use of clinical radiology. 7th ed. London: The Royal College of Radiologists; 2012. Section G28.
11. Yarmish GM, Smith MP, Rosen MP, et al. ACR Appropriateness Criteria® Right Upper Quadrant Pain. Available at <https://acsearch.acr.org/docs/69474/Narrative/>. American College of Radiology. Accessed 2017 June 6.
12. Tulchinsky M, Ciak BW, Delbeke D, Hilson A, Holes-Lewis KA, Stabin MG, et al. SNM Practice Guideline for Hepatobiliary Scintigraphy 4.0. *J Nucl Med Technol.* 2010; 38: 210-218.
13. Kiewiet JJ, Leeuwenburgh MM, Bipat S, Bossuyt PM, Stoker J, Boermeester MA. A systematic review and meta-analysis of diagnostic performance of imaging in acute cholecystitis. *Radiology.* 2012; 264: 708-720.

Uroradiology



Hong Kong College of Radiologists





Renal injuries are classified into grades 1 to 5 based on the severity of the injury using the American Association for the Surgery of Trauma (AAST) organ injury severity scale:

- Grade 1: Contusion or nonexpanding subcapsular haematoma without parenchymal laceration.
- Grade 2: Non-expanding perirenal haematoma laceration <1 cm deep without extravasation.
- Grade 3: Laceration >1 cm without urinary extravasation.
- Grade 4: Laceration extending through renal cortex into collecting system, or segmental renal artery or vein injury with contained hemorrhage, or partial vessel laceration, or vessel thrombosis.
- Grade 5: Laceration with shattered kidney, or renal pedicle injury, or avulsion of renal hilum.

REMARKS

1 General

- 1.1 Surgical operation should be given first priority if the patient is haemodynamically unstable.

2 Intravenous urogram (IVU)

- 2.1 The use of IVU is recommended when it is the only modality available. IVU can be used to establish the presence or absence of one or both kidneys, clearly define the parenchyma, and outline the collecting system. The most significant findings are non-function and extravasation.

3 US

- 3.1 US should not be used as a primary imaging modality because it gives no information about the renal function and may show an apparently normal kidney when the renal artery is occluded.
- 3.2 While the role of Focused Assessment with Sonography for Trauma (FAST) in the haemodynamically unstable trauma patient is well recognized, its utility in the haemodynamically stable patient is more controversial, as CT is usually required for precise delineation of underlying injuries.
- 3.3 US is useful for the routine follow-up of parenchymal lesions or haematomas in the intensive care unit and for serially evaluating stable injuries for the resolution of urinomas and retroperitoneal haematomas.

4 CT

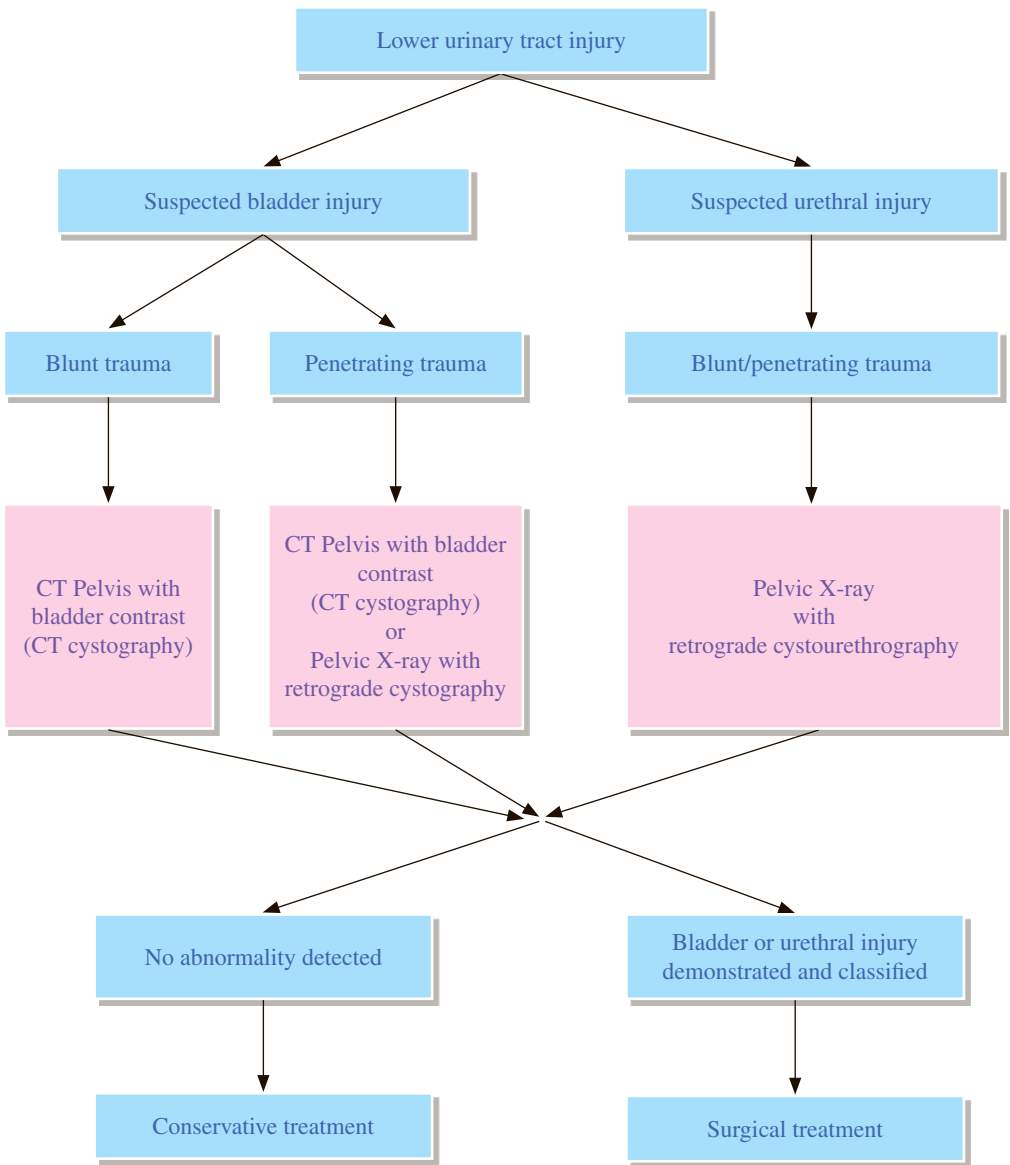
- 4.1 CT is currently the gold standard to assess renal trauma.
- 4.2 Contusions, lacerations (and their extent), extra-renal haematomas and urinary extravasation can all be identified on CT.
- 4.3 Intravenous contrast administration is necessary.

5 Angiography

- 5.1 Arteriography has a high degree of specificity in detecting the bleeder, it is usually performed as part of a therapeutic embolization and directed towards a suspected abnormality detected on contrast-enhanced CT. The additional contrast load administered during embolotherapy does not seem to have long-term impact on renal function. Embolotherapy has been shown to be safe and effective in the management of renovascular injuries and may be associated with shorter hospital stay compared to surgical intervention.

REFERENCES

1. Sheth S, Casalino DD, Remer EM, et al. ACR Appropriateness Criteria® Renal Trauma. Available at <https://acsearch.acr.org/docs/69373/Narrative/>. American College of Radiology. Accessed 2017 May 15.
2. Summerton DJ, Djakovic N, Kitrey ND, Kuehhas FE, Lumen N, Serafitinidis E, et al. Guidelines on Urological trauma. Arnhem: European Association of Urology; 2014.
3. Buckley JC, McAninch JW. Revision of current American Association for the Surgery of Trauma Renal Injury grading system. *J Trauma*. 2011; 70: 35-37.
4. Paparel P, N'Diaye A, Laumon B, Caillot JL, Perrin P, Ruffion A. The epidemiology of trauma of the genitourinary system after traffic accidents: analysis of a register of over 43,000 victims. *BJU Int*. 2006; 97: 338-341.
5. McAninch JW. Genitourinary trauma. *World J Urol*. 1999 Apr; 17: 65.



REMARKS

1 Plain radiograph

- 1.1 Approximately 10% of patients with pelvic fracture have an associated bladder injury.
- 1.2 About 70% of bladder injuries have an associated pelvic fracture. The severity of the pelvic injury roughly correlates with the likelihood of bladder and urethral injury.
- 1.3 About 10% of male patients with pelvic fracture have posterior urethral injury.
- 1.4 Can look for any foreign body e.g. bullet.

2 Cystogram and urethrogram

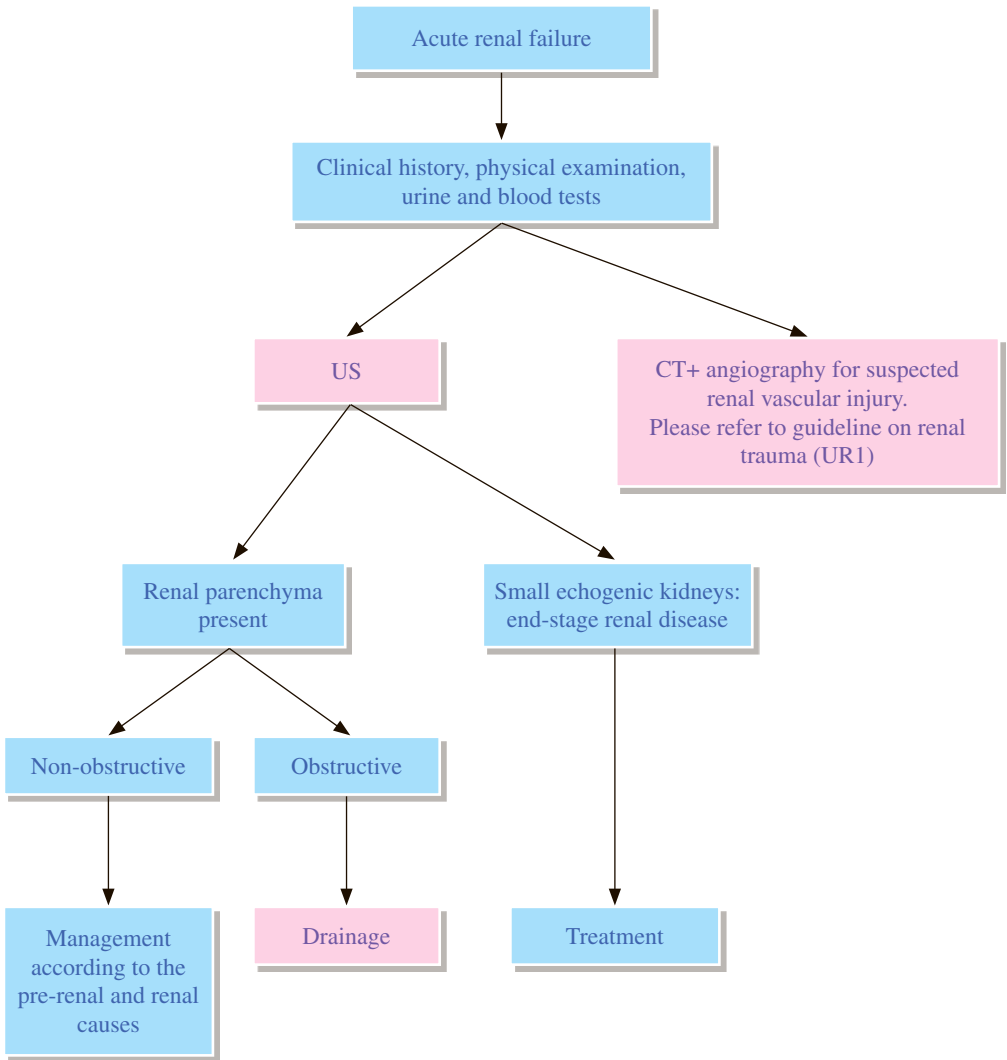
- 2.1 Catheterization into urinary bladder should only be performed after an associated urethral injury has already been excluded by a retrograde urethrogram. Cystogram should be performed with a suprapubic catheter in a patient with urethral injury.
- 2.2 A normal cystogram cannot exclude bladder contusion (type I injury), which is a diagnosis by exclusion.

3 CT Pelvis with bladder contrast (CT cystography)

- 3.1 CT cystography is a variation of the traditional fluoroscopic cystogram. Instead of antegrade opacification of the urinary collecting system (as with CT urography), contrast is instilled retrograde into the patient's bladder, and then the pelvis is imaged with CT.
- 3.2 Fluoroscopic and CT cystography are considered equivalent for suspected bladder rupture.
- 3.3 CT pelvis with CT cystography is considered to be the investigation of choice for patients with blunt trauma as about 80% of patients with bladder injuries due to blunt trauma have associated pelvic fractures which can be detected by CT pelvis.

REFERENCES

1. Gross JA, Lehnert BE, Linnau KF, Voelzke BB, Sandstrom CK. Imaging of Urinary System Trauma. *Radiol Clin North Am.* 2015; 53: 773-788.
2. Lockhart ME, Remer EM, Leyendecker JR, et al. ACR Appropriateness Criteria® Suspected Lower Urinary Tract Trauma. Available at <https://acsearch.acr.org/docs/69376/Narrative/>. American College of Radiology. Accessed 2017 May 15.
3. Ramchandani P, Buckler PM. Imaging of genitourinary trauma. *AJR Am J Roentgenol.* 2009 Jun; 192: 1514-1523.
4. Summerton DJ, Djakovic N, Kitrey ND, Kuehhas FE, Lumen N, Serafitinidis E, et al. Guidelines on Urological trauma. Arnhem: European Association of Urology; 2014.
5. The Royal College of Radiologist. Standards for intravascular contrast administration to adult patients. 3rd ed. London: The Royal College of Radiologists; 2015.



REMARKS

1 Intravenous urogram (IVU)

- 1.1 IVU has no role in acute renal failure.

2 US

- 2.1 US should be the initial imaging study. It helps to differentiate potentially reversible acute renal failure from chronic end-stage renal disease. In cases of chronic renal failure, US can define the renal sizes and their echogenicity, presence of pelvicalyceal dilatation and cystic disease.
- 2.2 Color Doppler US can be used to assess the renal arterial supply and venous drainage.

3 Nuclear medicine

- 3.1 Renal scan provides assessment of global and differential renal function which may reflect the potential reversibility of the renal failure. It is generally not useful in clinical decision making.

4 CT

- 4.1 CT is of value for ruling out stone disease, surveying the retroperitoneum for masses in patients with suspected post-renal cause of dysfunction.

5 MRI

- 5.1 In hypertensive patients or in those with extensive peripheral atherosclerotic vascular disease, magnetic resonance angiogram (MRA) with/without contrast is useful for detecting renal artery stenosis when duplex Doppler US is negative or non-diagnostic.

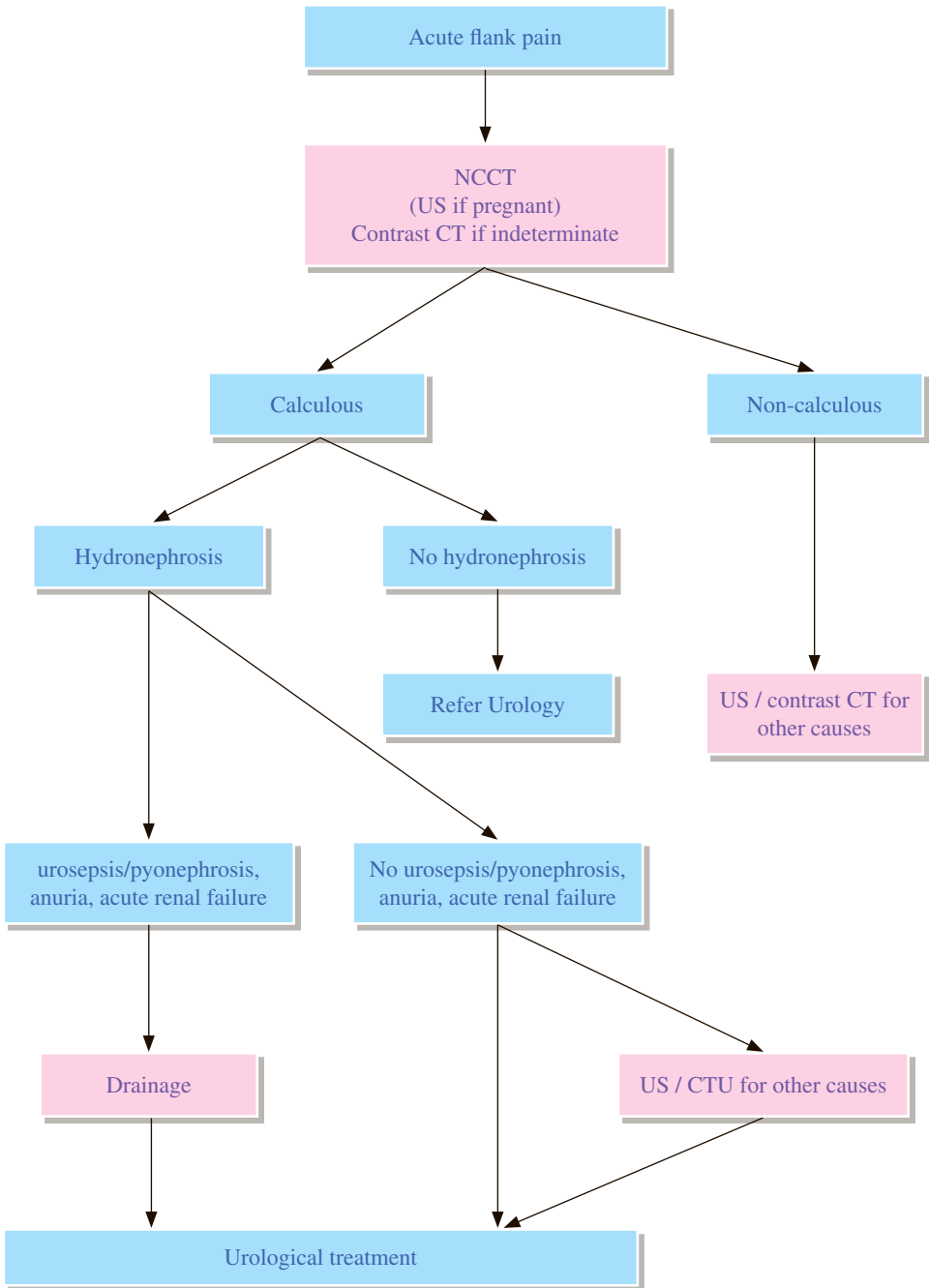
6 Pathological diagnosis

- 6.1 Percutaneous US-guided renal biopsy yields tissue for pathological examination in patients with intrinsic renal dysfunction, such as glomerular, vascular or tubulointerstitial diseases.

REFERENCES

1. Remer EM, Papanicolaou N, Casalino DD, et al. ACR Appropriateness Criteria® Renal Failure. Available at <https://acsearch.acr.org/docs/69492/Narrative/>. American College of Radiology. Accessed 2017 May 15.
2. Kidney Disease Improving Global Outcomes. KDIGO Clinical Practice Guideline for Acute Kidney Injury. Brussels: Kidney Disease Improving Global Outcomes; 2012.
3. Lorenz JM, Al-Refaie WB, Cash BD, et al. ACR Appropriateness Criteria® Radiological Management of Infected Fluid Collections. Available at <https://acsearch.acr.org/docs/69345/Narrative/>. American College of Radiology. Accessed 2017 May 15.
4. The Royal College of Radiologist. Standards for intravascular contrast administration to adult patients. 3rd ed. London: The Royal College of Radiologists; 2015.

UR 4 Acute flank pain



REMARKS

1 General

- 1.1 Renal calculi tend to be recurrent, and flank pain is a non-specific symptom that may be associated with other entities; therefore, evaluation with imaging is recommended at the initial presentation.

2 Plain radiograph

- 2.1 Kidney, ureter and bladder radiograph (KUB) may be sufficient to diagnose ureterolithiasis in patients with known stone disease and previous KUBs. The sensitivity of the KUB for ureterolithiasis in other patients is poor.
- 2.2 While the KUB may be a valuable part of the intravenous urogram (IVU) or US evaluation of flank pain, it has a very limited role when used alone, and it should not be used to triage which patients should receive non-contrast computed tomography (NCCT).

3 IVU

- 3.1 The IVU is the previous standard study for ureterolithiasis and is still the best investigation if NCCT is not available. It provides information regarding site and degree of obstruction, size of stone, and effect of obstruction on renal excretion.

4 US

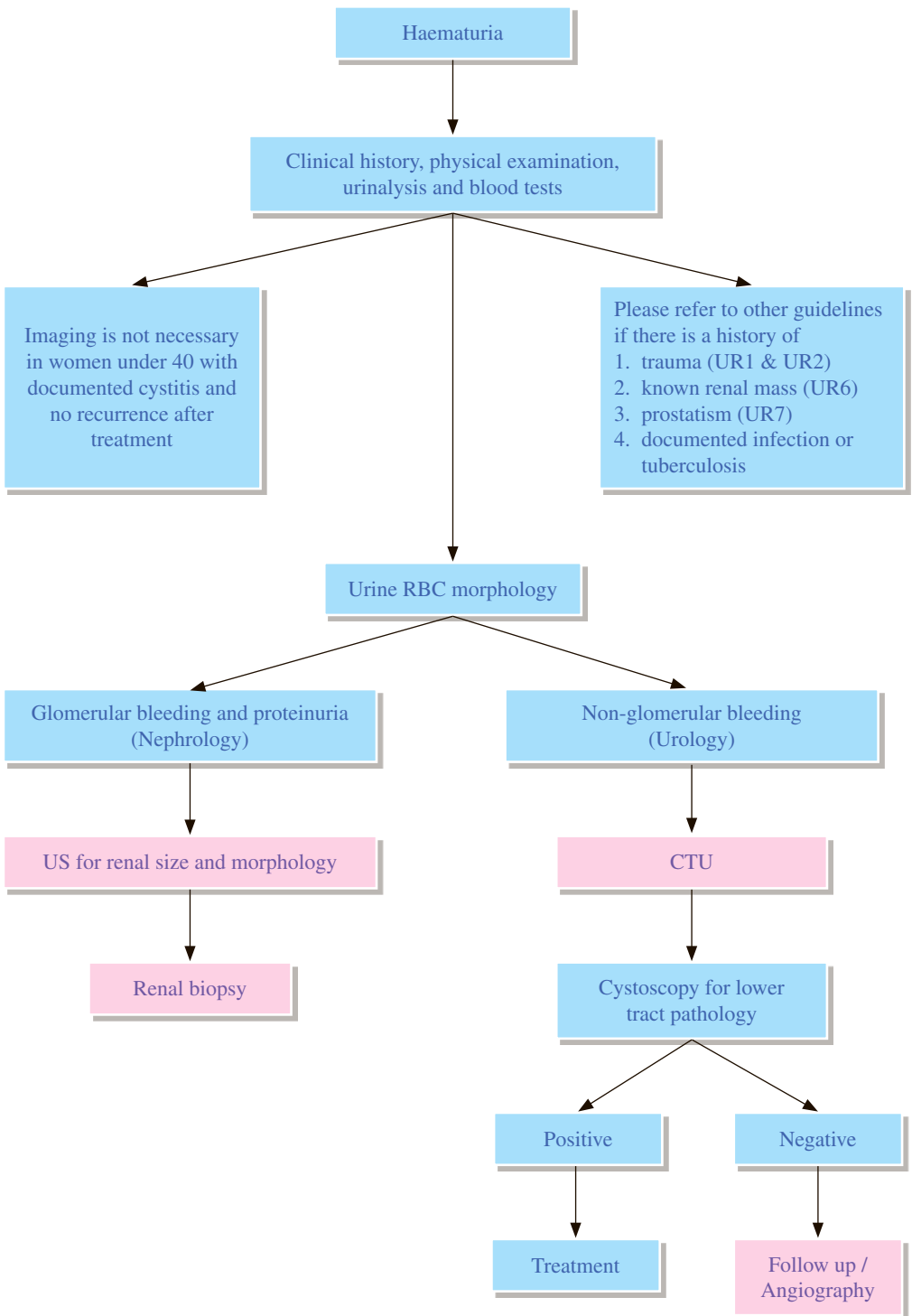
- 4.1 US is particularly useful in patient with high risk of contrast media reaction or pregnancy.
- 4.2 The size of stones cannot be measured accurately and ureteric stones may not be shown on US.
- 4.3 When US is combined with KUB, it can increase the capability to detect small stones and more accurately measure stone size.

5 CT

- 5.1 NCCT as the initial study in evaluating flank pain, numerous investigations have confirmed it to be the study with the highest sensitivity (95%-96%) and specificity (98%) for ureterolithiasis. Stone size can be measured accurately in cross-section, aiding in predicting outcome. Stone location, accurately depicted by NCCT, has also been associated with spontaneous stone passage rates, with the more proximal stones having a higher need for intervention.
- 5.2 NCCT is also reliable for diagnosing flank pain due to causes other than ureterolithiasis such as appendicitis and diverticulitis.
- 5.3 When CT is available, it is the best first study in the non-pregnant adult presenting with flank pain likely to be due to stone disease, and it has been shown to be more cost-effective than IVU.

REFERENCES

1. Moreno CC, Beland MD, Goldfarb S, et al. ACR Appropriateness Criteria® Acute Onset Flank Pain--Suspicion Of Stone Disease. Available at <https://acsearch.acr.org/docs/69362/Narrative/>. American College of Radiology. Accessed 2017 June 30.
2. Eikefjord E, Askildsen JE, Rorvik J. Cost-effectiveness analysis (CEA) of intravenous urography (IVU) and unenhanced multidetector computed tomography (MDCT) for initial investigation of suspected acute ureterolithiasis. *Acta Radiol.* 2008; 49: 222-229.
3. Mermuys K, De Geeter F, Bacher K, Van De Moortele K, Coenegrachts K, Steyaert L, et al. Digital tomosynthesis in the detection of urolithiasis: Diagnostic performance and dosimetry compared with digital radiography with MDCT as the reference standard. *AJR Am J Roentgenol.* 2010; 195: 161-167.



REMARKS

1 General

- 1.1 Haematuria can originate from any site in the urinary tract and be due to a wide range of causes, which can be roughly divided into renal, urothelial, or prostatic causes. Thorough evaluation of gross haematuria is recommended, and this is usually done with a combination of clinical examination, cystoscopic evaluation, and urinary tract imaging.
- 1.2 Patients on anticoagulants who present with gross or microscopic haematuria have a sufficiently high prevalence of important disease including tumours such that workup cannot be forgone.
- 1.3 In comparison to gross haematuria, the situation is somewhat different in patients with microscopic haematuria. The recommended definition of microscopic haematuria is three or more red blood cells per high-power field on microscopic evaluation of urinary sediment from two of three properly collected urinalysis specimens.
- 1.4 Young women with a clinical picture of simple cystitis, and other patients whose haematuria completely and permanently resolves after successful therapy, are unlikely to benefit from any imaging.

2 Intravenous urogram (IVU)

- 2.1 IVU has low sensitivity for detecting renal masses <2–3 cm in size, and even if a mass is visualized, further cross sectional studies such as US, CT, or MRI are then necessary to characterize the mass.

3 Retrograde pyelography

- 3.1 Retrograde pyelography does not rely on renal excretion of intravascular contrast. In patients with impaired renal function, or contraindications to computed tomography urogram (CTU) or magnetic resonance urogram (MRU), or suboptimal CTU or MRU, a retrograde pyelography may be a reasonable adjunct to cystoscopy in patients with suspected upper tract lesions.

4 US

- 4.1 US still has a role in the initial workup of haematuria to search for bleeding urinary tract lesions. It is especially useful in radiation-sensitive populations, such as children and pregnant or child-bearing age women, to detect renal calculi and renal masses.
- 4.2 In patients in whom glomerular disease is the cause of haematuria, US can examine the renal parenchyma and follow disease progression. US can evaluate renal length, echogenicity, cortical thickness, and parenchymal thickness.

5 CT

- 5.1 Numerous studies have established that CTU is superior to IVU for detecting upper tract urothelial lesions in patients with haematuria. In a meta-analysis, CTU was proved to be a very sensitive and specific method for the detection of urothelial malignancy with pooled sensitivity of 96% and pooled specificity of 99%, and was superior in direct comparison to IVU in terms of sensitivity and specificity.

6 Cystoscopy

6.1 Cystoscopy is still considered to be the optimal technique to detect the plaque-like lesions of early bladder cancers, although newer studies suggest that a properly performed CTU in an adequately distended bladder is quite sensitive in detecting bladder cancer. Patients with no bladder abnormality on CTU can proceed to office cystoscopy, while those with a suspected bladder neoplasm can undergo cystoscopy in the operating room with intent to biopsy.

7 Angiography

7.1 Rarely, vascular disorders such as aneurysms, arteriovenous malformations or obstruction of a calyx from overlying artery (Fraley's syndrome) may result in haematuria. In these suspected situations, catheter angiography may be useful for diagnosis and for therapeutic interventions.

8 MRI

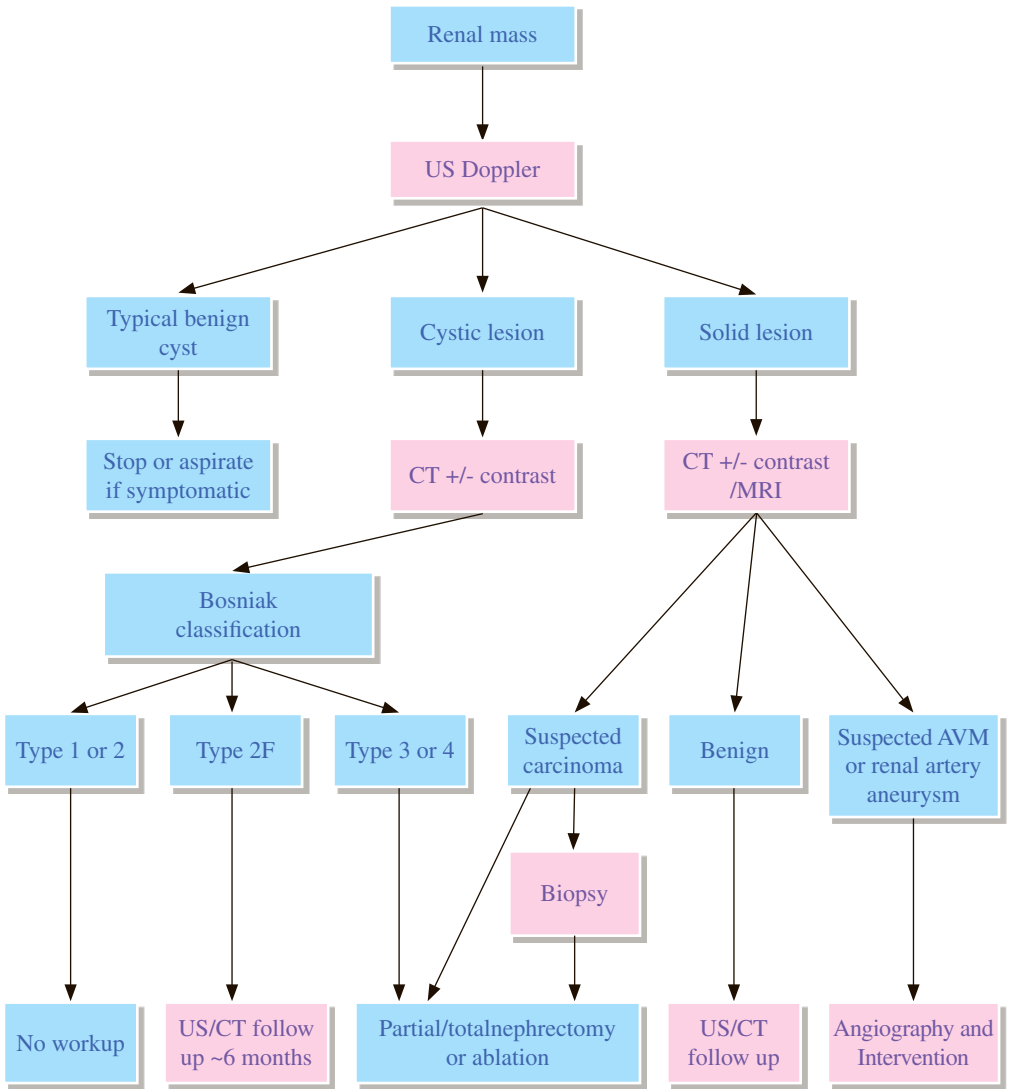
8.1 MRI is an excellent technique to evaluate the renal parenchyma for masses and other abnormalities; it is inferior to CTU and IVU in detection of small stones and urothelial lesions.

9 Pathological diagnosis

9.1 Renal biopsy should be performed for cases suspected to have glomerulonephritis.

REFERENCES

1. Shen L, Raman SS, Beland MD, et al. ACR Appropriateness Criteria® Hematuria. Available at <https://acsearch.acr.org/docs/69490/Narrative/>. American College of Radiology. Accessed 2017 May 16.
2. O'Connor OJ, Fitzgerald E, Maher MM. Imaging in hematuria. *AJR Am J Roentgenol.* 2010; 195: W263-267.
3. Davis R, Jones JS, Barocas DA, et al. American Urological Association Guideline: Diagnosis, Evaluation and Follow-up of Asymptomatic Microhematuria (AMH) in Adults. Available at [https://www.auanet.org/guidelines/asymptomatic-microhematuria-\(2012-reviewed-and-validity-confirmed-2016\)](https://www.auanet.org/guidelines/asymptomatic-microhematuria-(2012-reviewed-and-validity-confirmed-2016)). American Urological Association. Accessed 2017 June 30.
4. Kurtz M, Feldman AS, Cho KC, et al. Evaluation of hematuria in adults. Available at <https://www.uptodate.com/contents/etiology-and-evaluation-of-hematuria-in-adults/UpToDate>. Accessed 2017 June 30.



Bosniak Classification 2005 version

Bosniak 1

- simple cyst: imperceptible wall, rounded

Bosniak 2

- minimally complex: a few thin <1 mm septa or thin calcifications (thickness not measurable); non-enhancing high-attenuation (due to proteinaceous or haemorrhagic fluid) renal lesions of less than or up to 3 cm are also included in this category; these lesions are generally well margined

Bosniak 2F

- minimally complex: increased number of septa, minimally thickened wall or septa with nodular or thick calcifications but no measurable contrast enhancement, hyperdense (>20 Hounsfield unit) cyst >3 cm diameter, mostly intrarenal (less than 25% of wall visible)

Bosniak 3

- indeterminate: thick, nodular multiple septa or wall, with measurable enhancement, hyperdense on CT (see 2F)

Bosniak 4

- clearly malignant: solid mass with a large cystic or a necrotic component

REMARKS

1 Plain radiograph

- 1.1 Kidney, ureter and bladder radiograph (KUB) has a very low sensitivity and specificity in detecting renal mass.

2 Intravenous urogram (IVU)

- 2.1 IVU with nephrotomography has only 67% sensitivity in detecting renal masses ≤ 3 cm in diameter, and without tomography the sensitivity is even less. It is rarely used in current management of the indeterminate renal mass.

3 US

- 3.1 When all the criteria of a simple benign cyst (anechoic, good through transmission, thin, sharply marginated, smooth walls) are found on US, no further imaging study is needed.
- 3.2 A hyperechoic mass is highly suggestive of angiomyolipoma. CT or angiogram may be required in doubtful cases.

4 CT

- 4.1 CT is used to clarify all hypoechoic masses or complex cysts not fulfilling all the criteria of a simple cyst e.g. cyst with septa, thick or calcified walls, infection or haemorrhage.
- 4.2 CT is more accurate than US in detecting small renal lesions less than 1.5cm. Small lesion < 1.5 cm suspected to be renal cell carcinoma can be followed up by CT at 6-month, 1 year and then yearly interval.
- 4.3 Demonstration of a small amount of fat in a lesion on CT can accurately suggest an angiomyolipoma.

5 MRI

- 5.1 MRI is indicated when CT cannot be performed due to the risk of contrast media reaction or renal insufficiency.
- 5.2 MRI is as accurate as CT. However, MRI is more sensitive in detecting thrombus in renal veins and inferior vena cava.

6 Angiography

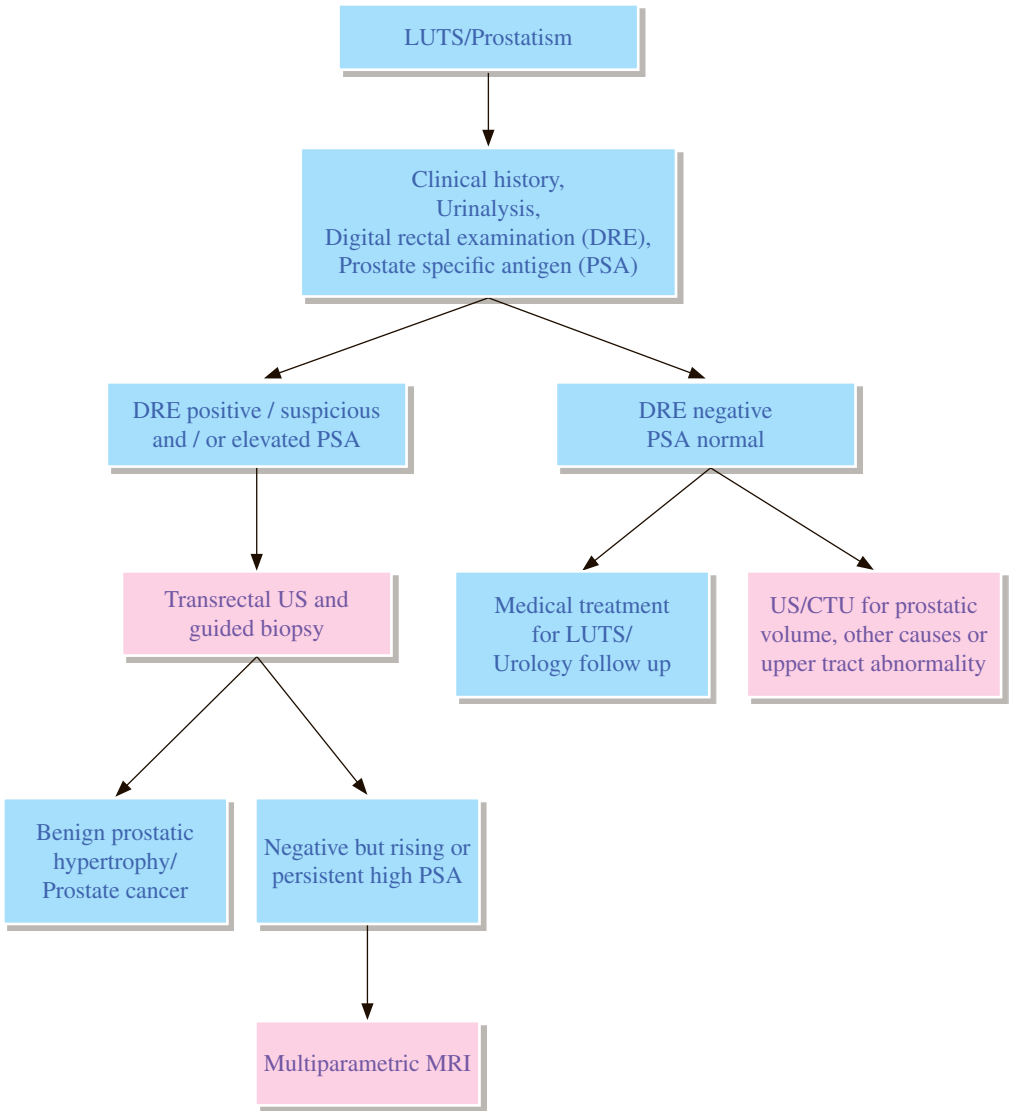
- 6.1 Although two-thirds of renal tumours have enough vascularity to allow identification of tumour neovascularity, one-third will be of such a hypovascular or “avascular” state that angiography will not help identify the lesion as benign or malignant.
- 6.2 Angiogram is useful to exclude arteriovenous malformation (AVM) and renal artery aneurysm.

7 Pathological diagnosis

- 7.1 Tissue diagnosis is rarely necessary in establishing diagnosis of renal mass and a negative result does not exclude malignancy. However, it is useful to confirm infected cyst, lymphoma and metastasis.

REFERENCES

1. Heilbrun ME, Casalino DD, Beland MD, et al. ACR Appropriateness Criteria[®] Indeterminate Renal Mass. Available at <https://acsearch.acr.org/docs/69367/Narrative/>. American College of Radiology 2015. Accessed 2017 May 21.
2. Hindman NM, Hecht EM, Bosniak MA. Follow-up for Bosniak category 2F cystic renal lesions. *Radiology*. 2014; 272: 757-766.
3. Bosniak MA. The current radiological approach to renal cysts. *Radiology*. 1986; 158: 1-10.
4. Bosniak MA. The Bosniak renal cyst classification: 25 years later. *Radiology*. 2012; 262: 781-785.



REMARKS

1 Pelvic US / Transrectal US

- 1.1 Both transabdominal US and transrectal US (TRUS) are equally accurate for measuring prostate volume. Identifying the size of the prostate is important since it helps determine the type of therapy indicated.
- 1.2 The US pattern is still too nonspecific to differentiate benign from malignant prostate lesions. TRUS-guided biopsy greatly improves accuracy.
- 1.3 Generally TRUS is more accurate than CT in detecting capsular transgression but the accuracy does not appear high enough to support decision regarding the operability of individual lesion.
- 1.4 TRUS allows volume correlation with PSA level.

2 Nuclear medicine

- 2.1 Bone scan is important in staging of prostate cancer and sensitive for bone metastasis detection.

3 CT

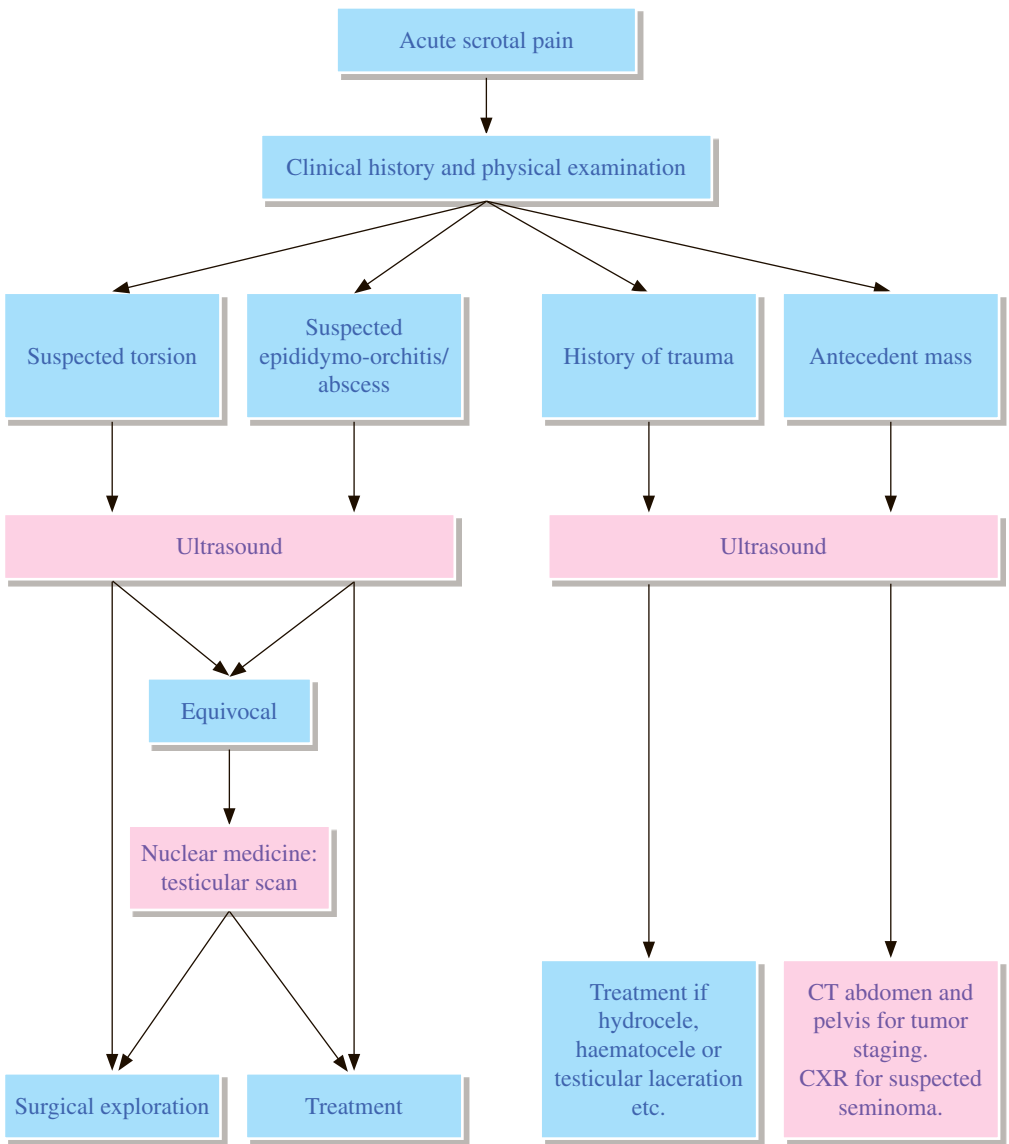
- 3.1 CT is used in staging pelvic extent of prostate cancer.
- 3.2 CT has not proven to be of much value in evaluating the benign, enlarged prostate.

4 MRI

- 4.1 The primary indication for MRI of the prostate is in the evaluation of prostate cancer after an ultrasound guided prostate biopsy has confirmed cancer in order to determine if there is extracapsular extension.
- 4.2 MRI is also useful in evaluating prostate size, although other less costly procedures, such as US, are preferred.
- 4.3 Increasingly MRI is also being used to detect prostate cancer particularly when the PSA is persistently elevated, but routine TRUS biopsy is negative; and to localize and stage a newly diagnosed prostate cancer for optimal treatment.

REFERENCES

1. Barentsz JO, Richenberg J, Clements R, Choyke P, Verma S, Villeirs G, et al. ESUR prostate MR guidelines 2012. *Eur Radiol.* 2012; 22: 746-757.
2. Bomers JGR, Bittencourt LK, Villeirs G, Barentsz JO. Prostate. In: Grainger RG, Allison DJ, editors. *Grainger & Allison's diagnostic radiology - a textbook of medical imaging.* 6th ed. London: Churchill Livingstone; 2015. p. 931-944.
3. Dighe M, Francis IR, Casalino DD, Arellano RS, Baumgarten DA, Curry NA, et al. ACR Appropriateness Criteria® on Obstructive Voiding Symptoms Secondary to Prostate Disease. *J Am Coll Radiol.* 2010; 7: 255-259.
4. Grossfeld GD, Coakley FV. Benign prostatic hyperplasia: clinical overview and value of diagnostic imaging. *Radiol Clin North Am.* 2000; 38: 31-47.
5. McAchran SE, Hartke DM, Nakamoto DA, Resnick MI. Sonography of the Urinary Bladder. *Ultrasound Clinics.* 2007; 2: 17-26.
6. McVary KT, Roehrborn CG, Avins AL, Barry MJ, Bruskewitz RC, Donnell RF, et al. Update on AUA guideline on the management of benign prostatic hyperplasia. *J Urol.* 2011; 185: 1793-1803.
7. Quon J, Kielar AZ, Jain R, Schieda N, et al. Assessing the utilization of functional imaging in multiparametric prostate MRI in routine clinical practice. *Clin Radiol.* 2015; 70: 373-378.
8. Ren J, Huan Y, Wang H, Zhao H, Ge Y, Chang Y, et al. Diffusion-weighted imaging in normal prostate and differential diagnosis of prostate diseases. *Abdom Imaging.* 2008; 33: 724-728.
9. Stacul F, Rossi A, Cova MA. CT urography: the end of IVU? *Radiol Med.* 2008; 113: 658-669.



REMARKS

1 General

- 1.1 For surgery to be successful, the diagnosis of acute torsion must be established within 4-8 hours from the onset of pain.
- 1.2 Patients in whom there is strong clinical suspicion for testicular torsion can be promptly referred for scrotal exploration.

2 US

- 2.1 The studies should include both the scrotum and inguinal areas.
- 2.2 US can localize a scrotal swelling to see whether it is arising from the testis or from the epididymis and to distinguish a varicocele from a hydrocele.
- 2.3 Color Doppler US can reliably assess blood flow within the testis. Blood flow is markedly reduced or absent in torsion of testis but is increased in epididymo-orchitis. In adults, with careful study and appropriate equipment, the specificity is close to 100%. Overall sensitivity is about 90%. False negatives may be found in incomplete torsion (less than 180 degrees) and in spontaneous de-torsion. Color Doppler US should be used in cases of suspected torsion or epididymo-orchitis.
- 2.4 Imaging in clinically equivocal cases may lead to an early diagnosis of testicular torsion and thus decrease the number of unnecessary surgeries.

3 Nuclear medicine

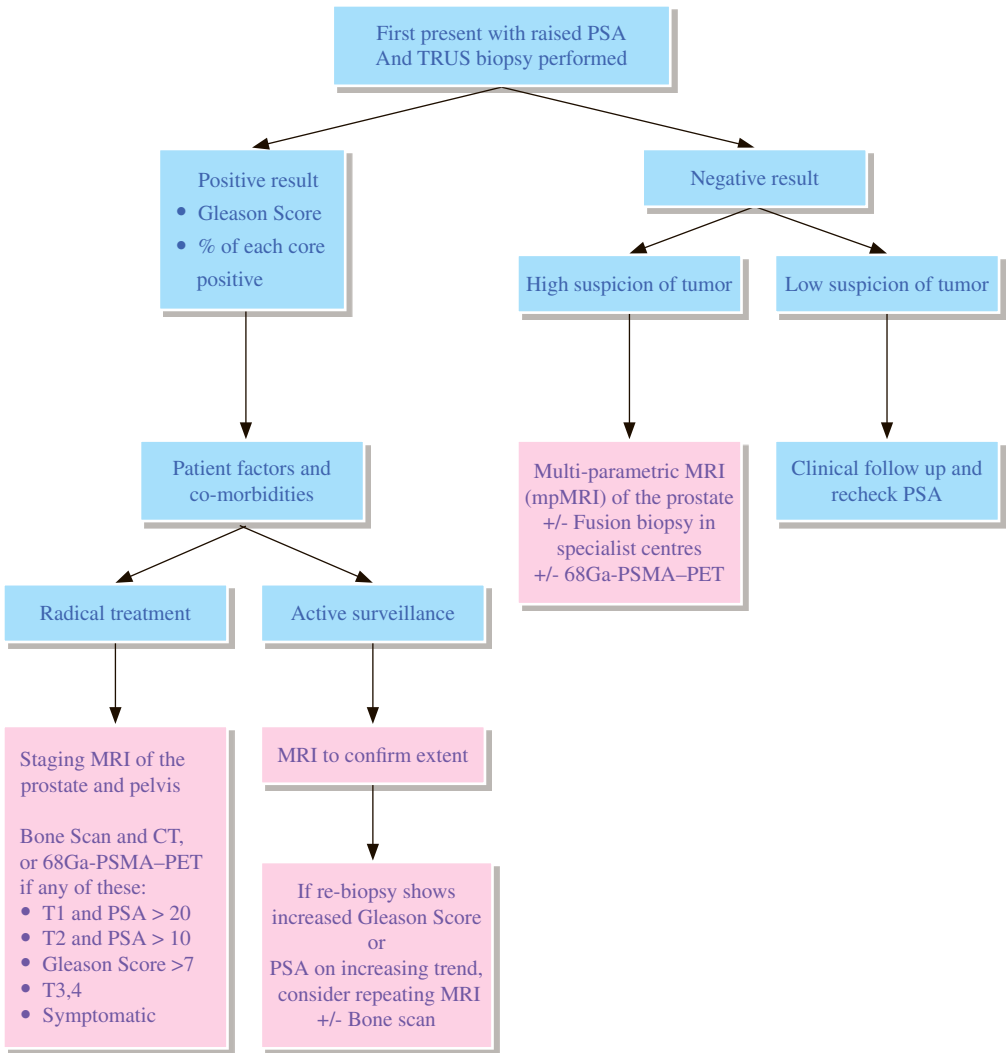
- 3.1 Testicular scan has 90% sensitivity and 98% specificity in assessing testicular torsion.
- 3.2 Testicular scan is uncommonly requested nowadays given the high accuracy of US. It may be used when diagnosis is less likely and if torsion of the testis still cannot be excluded from history and physical examination. This should be done without inordinate delays for emergency intervention.
- 3.3 Problems in examination performance may arise in infants and very small children whose genitalia are small and therefore difficult to image. Its poor anatomical detailing, and the time required for radionuclide scrotal imaging examinations are also limiting factors.

4 MRI

- 4.1 Techniques are not typically used for the acute scrotum due to the limited availability of equipment and the long examination time involved. However, the use of MRI in scrotal diseases is increasing. A retrospective study reports that MRI has 93% sensitivity and 100% specificity for diagnosing testicular torsion.
- 4.2 The most sensitive finding in torsion is decreased or lack of perfusion on dynamic contrast-enhanced MRI.

REFERENCES

1. Dogra V, Bhatt S. Acute painful scrotum. *Radiol Clin North Am.* 2004; 42: 349–363.
2. Lam WW, Yap TL, Jacobsen AS, Teo HJ. Colour Doppler ultrasonography replacing surgical exploration for acute scrotum: myth or reality? *Pediatr Radiol.* 2005; 35: 597–600.
3. Liang T, Metcalfe P, Sevcik W, Noga M. Retrospective review of diagnosis and treatment in children presenting to the pediatric department with acute scrotum. *AJR Am J Roentgenol.* 2013; 200: W444–W449.
4. Morey AF, Brandes S, Dugi DD, Armstrong JH, Breyer BN, Broghammer JA, et al. Urotrauma: AUA Guideline. *J Urol.* 2014; 192: 327–335.
5. Remer EM, Casalino DD, Arellano RS, Bishoff JT, Coursey CA, Dighe M, et al. ACR Appropriateness Criteria® acute onset of scrotal pain: without trauma, without antecedent mass. *Ultrasound Q.* 2012; 28: 47–51.
6. Riccabona M, Darge K, Lobo ML, Ording-Muller LS, Augdal TA, Avni FE, et al. ESPR Uroradiology Taskforce— Imaging recommendations in paediatric uroradiology, part VIII: retrograde urethrography, imaging disorder of sexual development and imaging childhood testicular torsion. *Pediatr Radiol.* 2015; 45: 2023–2028.
7. The Royal College of Radiologists. *iRefer: Making the best use of clinical radiology.* 8th ed. London: The Royal College of Radiologists; 2017. Section U12.



REMARKS

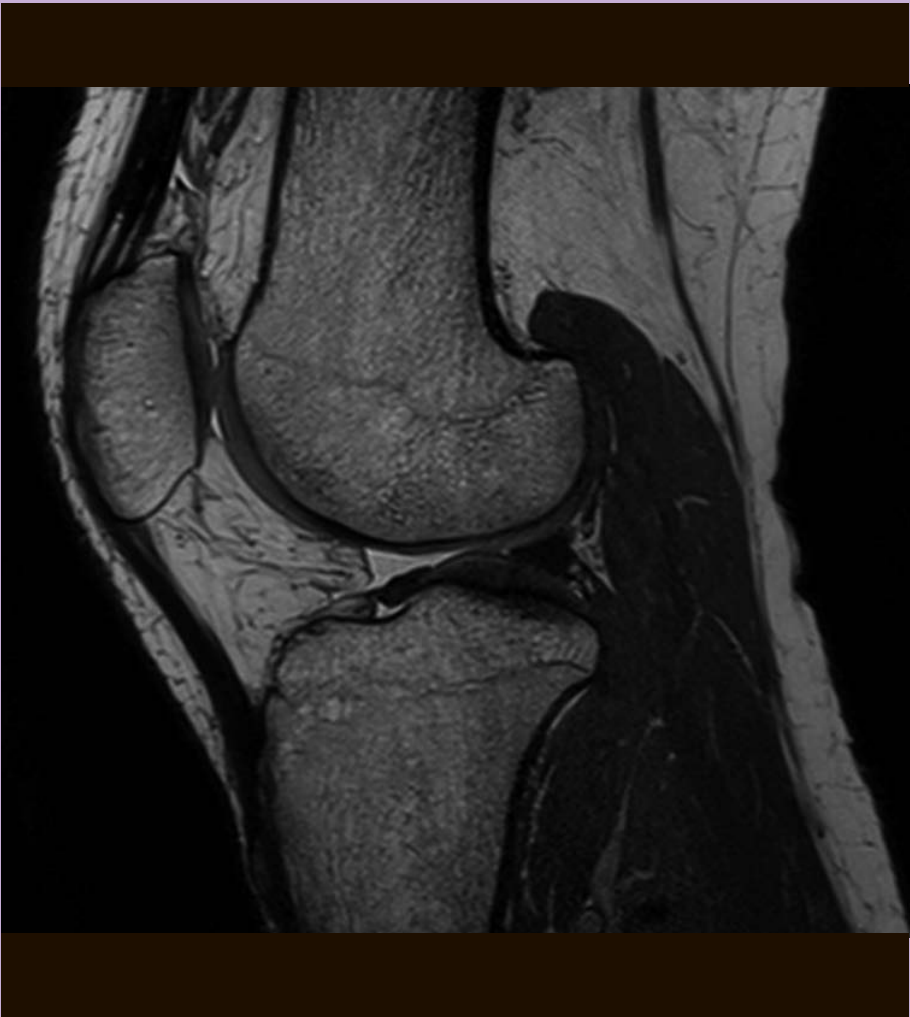
- 1 US and MRI are the most well established techniques for local imaging of prostate.
- 2 CT and Bone scans are traditionally used for high-risk patient or metastatic disease.
- 3 Choosing the correct imaging modality should be individualized based on consideration of the clinical parameters that are predictive of the likelihood of extra-prostatic extension, seminal vesicle invasion and metastatic disease. Clinical parameters to take into account include the pretreatment prostatic specific antigen (PSA) level and the rate of rise or doubling time, the Gleason score and sometimes the number of positive biopsies, including percentage of the core involved.
- 4 Imaging in low-risk patients is likely to have a low yield in detection of tumor. There may be a role for MRI in the context of active surveillance for low-risk patients.
- 5 For intermediate-risk and high-risk individuals, imaging has a role in staging and in selecting or tailoring therapy. MRI appears to be the most accurate imaging test available for local staging of the prostate, providing both loco-regional and nodal evaluation. Consensus is building around multi-parametric MRI (mpMRI) as the most accurate and useful approach. T2 weighted imaging with diffusion weighted imaging, dynamic contrast enhanced imaging and magnetic resonance spectroscopy imaging appear to be useful adjuncts depending on radiologist preference and experience.
- 6 Bone scan and CT is helpful for staging of localized disease with high-risk:
 - 6.1 clinical T3/T4, or
 - 6.2 T1 and PSA >20, or
 - 6.3 T2 and PSA >10, or
 - 6.4 Gleason score ≥ 8 , or
 - 6.5 any stage with symptoms suggestive of bone metastases
- 7 Bone scan is also useful for evaluation after radical treatment:
 - 7.1 After prostatectomy: if PSA fails to drop to undetectable level, or detectable PSA that increased on 2 subsequent times.
 - 7.2 After radiotherapy: if increasing PSA or positive digital rectal examination (to determine if patient needs additional local therapy or systemic treatment)
- 8 Bone scan is particularly important in metastatic prostate cancer for disease monitoring,
- 9 When there is strong clinical suspicion for the presence of prostate cancer in an individual due to rising or persistently high PSA despite (generally multiple) negative biopsy sessions, MRI may be useful in identifying suspicious regions in the prostate that can be targeted for diagnosis.

- 10** Gallium-68 prostate specific membrane antigen PET (68Ga-PSMA–PET) imaging is currently under rapid development and has been shown to be useful in localized, advanced, as well as recurrent disease. 68Ga-PSMA-PET holds great future promise with emerging indications including:
- 10.1** localized disease: for primary staging in high risk group
 - 10.2** advanced disease: for disease monitoring, as well as staging before and during PSMA-directed radiotherapy for metastatic castration-resistant prostate cancer
 - 10.3** recurrent disease: for localization of tumor
 - 10.4** for targeted biopsy after previous negative biopsy in patient with high suspicion of prostate cancer
- 11** C11-Choline PET imaging is a reasonable alternative for imaging local recurrence, nodal and distant metastasis in prostate cancer. However, its uptake overlaps between benign and malignant prostatic pathology and does not correlate with tumour grading, PSA, Gleason score.

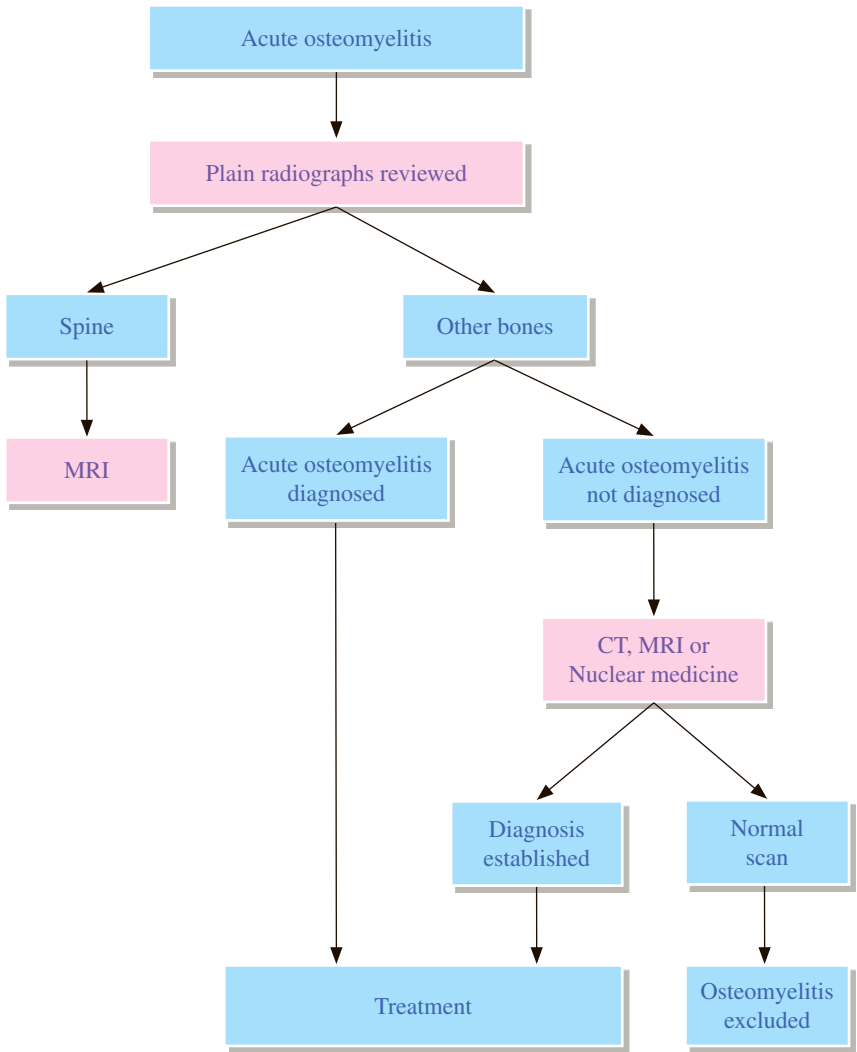
REFERENCES

1. Barentsz JO, Richenberg J, Clements R, Choyke P, Verma S, Villeirs G, et al. ESUR prostate MR guidelines 2012. *Eur Radiol.* 2012; 22: 746-757.
2. Eberhardt SC, Carter S, Casalino DD, Merrick G, Frank SJ, Gottschalk AR, et al. ACR Appropriateness Criteria prostate cancer – pretreatment detection, staging, and surveillance. *J Am Coll Radiol.* 2013; 10: 83-92.
3. Choi YF, Kim FK, Kim N, Kim KW, Choi EK, Cho KS. Functional MR Imaging of Prostate Cancer. *Radiographics.* 2007; 27: 63-77.
4. American College of Radiology. PI-RADS Prostate Imaging – Reporting and Data System 2015 version 2. Reston: American College of Radiology, 2015.
5. Rowe SP, Gorin MA, Allaf ME, Pienta KJ, Tran PT, Pomper MG, et al. PET imaging of prostate-specific membrane antigen in prostate cancer: current state of the art and future challenges. *Prostate Cancer Prostatic Dis.* 2016; 19: 223-230.
6. National Comprehensive Cancer Network. NCCN Clinical Practice Guidelines in Oncology (NCCN Guidelines®) Prostate Cancer. Version 2.2017. Fort Washington, PA: National Comprehensive Cancer Network; 2017.
7. Fendler WP, Eiber M, Beheshti M, Bomanji J, Ceci F, Cho S, et al. 68Ga-PSMA PET/CT: Joint EANM and SNMMI procedure guideline for prostate cancer imaging: version 1.0. *Eur J Nucl Med Mol Imaging.* 2017; 44: 1014-1024.

Musculoskeletal Radiology



Hong Kong College of Radiologists



REMARKS

1 Plain radiograph

- 1.1 Regional radiographs should be the initial examination to determine whether there is any underlying pathological condition.
- 1.2 Typical findings of bone destruction and periosteal reaction may not appear until 10-21 days after the onset of infection because 30-50% of bone density loss must occur before radiographs become abnormal.
- 1.3 Plain radiographs are unreliable to establish the diagnosis of osteomyelitis in patients with violated bone.
- 1.4 Plain radiographs of spine are not sensitive to detect vertebral osteomyelitis but findings of endplate destruction and progressive narrowing of adjacent disc space are highly suggestive of infection.

2 Nuclear medicine

- 2.1 Scans should be interpreted with contemporary radiographs.
- 2.2 Three-phase Technetium-99m methylene diphosphonate (Tc-99m-MDP) bone scan
 - 2.2.1 Bone scan is more sensitive than plain radiography (up to 90% sensitivity).
 - 2.2.2 Bone scan can be positive as early as 3 days after onset of disease (10-14 days earlier than plain radiograph).
- 2.3 Gallium scan
 - 2.3.1 Gallium scan is helpful as conjunction with a bone scan. Combined gallium and bone scan studies has sensitivity of 81-90% and specificity of 69-100%
- 2.4 White blood cells (WBC) scan
 - 2.4.1 This is sensitive and specific for bone infection and particularly useful in violated bone.
- 2.5 Flurodeoxyglucose (FDG) PET
 - 2.5.1 It has high accuracy (up to 96%) for confirming or excluding chronic osteomyelitis.
 - 2.5.2 It may be an alternative to MRI if suspecting chronic osteomyelitis.

3 CT

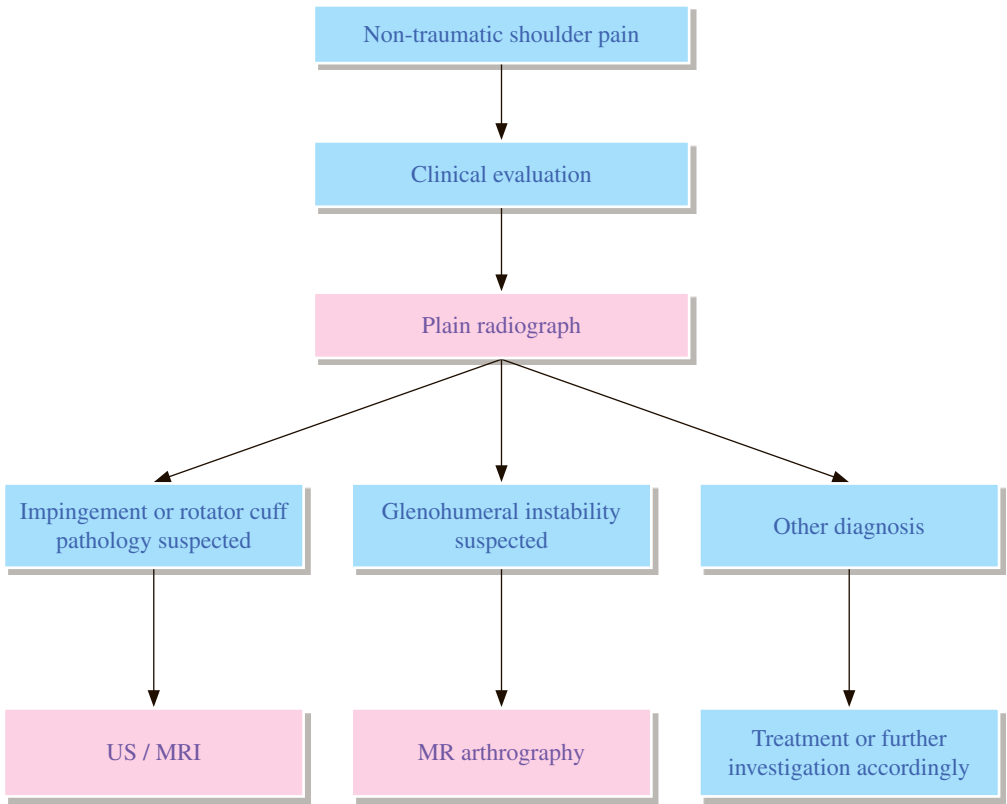
- 3.1 CT is useful to accurately define sequestra, soft tissue abscesses and bone destruction, and to guide biopsy.
- 3.2 Sequestra, cortical destruction, periosteal reaction and intraosseous gas undetected on MRI can be well seen on CT.

4 MRI

- 4.1 MRI is highly effective for detection of bone marrow edema in spine and long bones.
- 4.2 MRI can reveal the relationship between an infective process in spine, the adjacent spinal canal and soft tissue.
- 4.3 Contrast MRI is sensitive but should be correlated with other imaging studies.

REFERENCES

1. The Royal College of Radiologists. iRefer: Making the best use of clinical radiology. 7th ed. London: The Royal College of Radiologists; 2012. Section M07.
2. Beaman FD, Von Herrmann PF, Kransdorf MJ, et al. ACR Appropriateness Criteria® Suspected Osteomyelitis, Septic Arthritis, or Soft Tissue Infection (Excluding Spine and Diabetic Foot). Available at <https://acsearch.acr.org/docs/3094201/Narrative/>. American College of Radiology. Accessed 2017 May 2.
3. Termaat MF, Rajmakers PG, Scholten HJ, Bakker FC, Patka P, Haarman HJ. The accuracy of diagnostic imaging for the assessment of chronic osteomyelitis: a systematic review and meta-analysis. *J Bone Joint Surg Am.* 2005; 87: 2464-2471.
4. Sella EJ. Current concepts review: diagnostic imaging of the diabetic foot. *Foot Ankle Int.* 2009; 30: 568-576.
5. Schauwecker DS. The scintigraphic diagnosis of osteomyelitis. *AJR Am J Roentgenol.* 1992; 158: 9-18.
6. Modic M T, Feiglin DH, Piraino DW, Boumpfrey F, Weinstein MA, Duchesneau PM, et al. Vertebral osteomyelitis: assessment using MR. *Radiology.* 1985; 157: 157-166.
7. Jamar F, Buscombe J, Chiti A, Christian PE, Delbeke D, Donohoe KJ, et al. EANM/SNMMI guideline for 18F-FDG use in inflammation and infection. *J Nucl Med.* 2013; 54: 647-658.



REMARKS

1 General

- 1.1 Pain referred to shoulder should always be borne in mind in evaluating shoulder pain. Imaging examinations should be tailored to this regard.

2 Plain radiograph

- 2.1 Plain radiographs are useful for excluding skeletal abnormalities and calcific tendinitis.
- 2.2 Depending on site and type of lesion, additional special projections may be required.

3 US

- 3.1 It is operator-dependent and expertise is required for diagnosing tendinosis, partial or complete tear in cases of rotator cuff injury due to irritation or overuse of those tendons.
- 3.2 It is also useful for US guided aspiration and injection.
- 3.3 Bone changes or labral lesions cannot be detected.

4 MRI

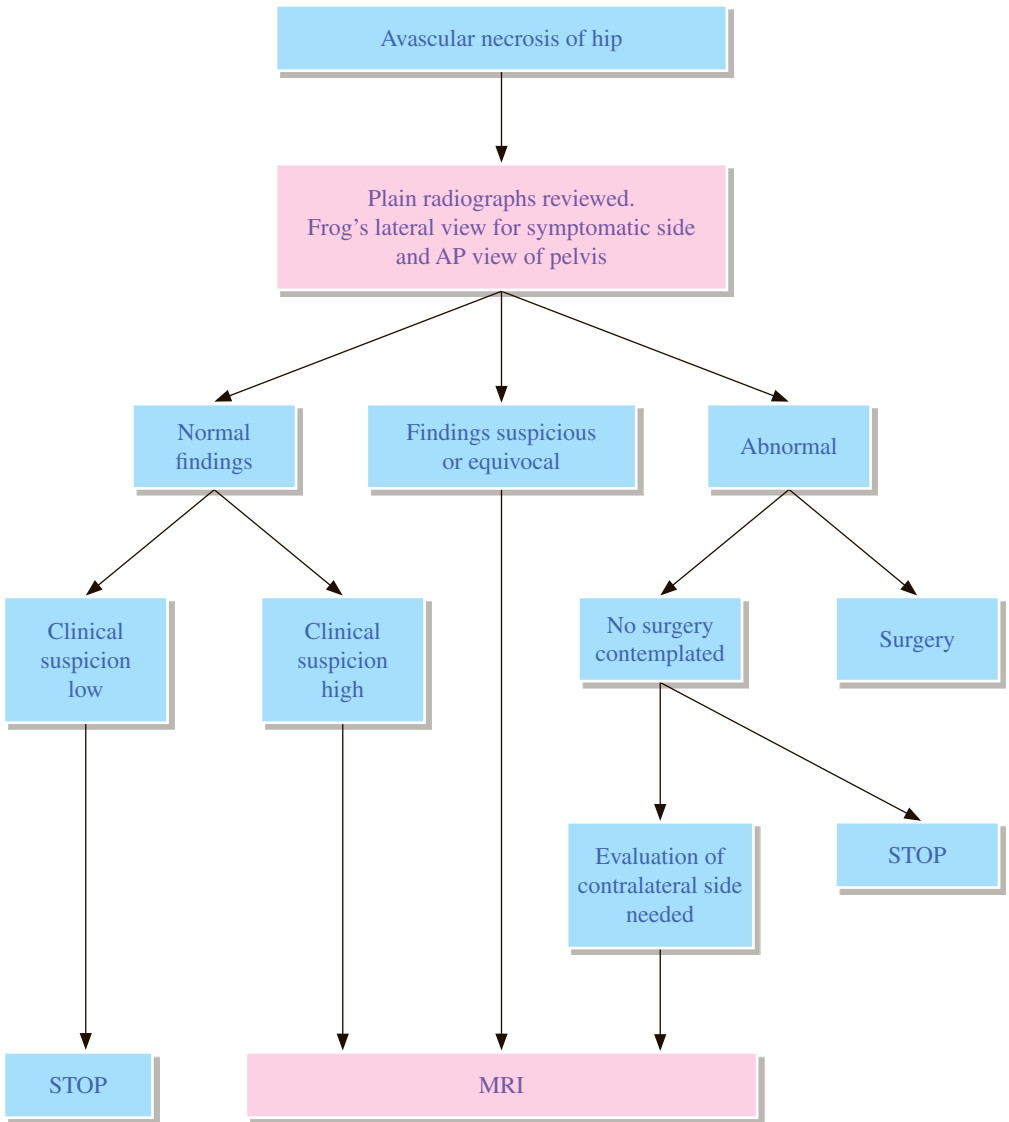
- 4.1 Conventional MRI
 - 4.1.1 MRI is accurate in evaluating rotator cuff pathology.
 - 4.1.2 It also aids in detecting other soft tissue or osseous abnormality.
- 4.2 MR arthrography
 - 4.2.1 Direct arthrography technique has the benefits of intraarticular distention by contrast with excellent anatomical details of glenoid labrum and biceps anchoring site.

5 CT arthrography

- 5.1 It may be considered if the patient is contraindicated for MRI arthrography.

REFERENCES

1. The Royal College of Radiologists. iRefer: Making the best use of clinical radiology. 7th ed. London: The Royal College of Radiologists; 2012. Sections M18-M19.
2. Wise JN, Daffner RH, Weissman BN, et al. ACR Appropriateness Criteria® Acute Shoulder Pain. Available at <https://acsearch.acr.org/docs/69433/Narrative/>. American College of Radiology. Accessed 2017 April 6.
3. Resnick D et al. Internal derangements of Joints. 2nd edition. Saunders Elsevier; 2007. p. 739-747.



REMARKS

1 Plain radiograph

- 1.1 Plain radiographs should be the initial imaging examination.
- 1.2 It is useful for staging the disorder from patchy sclerosis and subchondral lucency to collapse of the articular surface, dense bone sclerosis and fragmentation, degenerative changes.

2 Nuclear medicine

- 2.1 It is highly sensitive in detecting avascular necrosis with further improvement of its accuracy by the addition of single photon emission computed tomography (SPECT).

3 CT

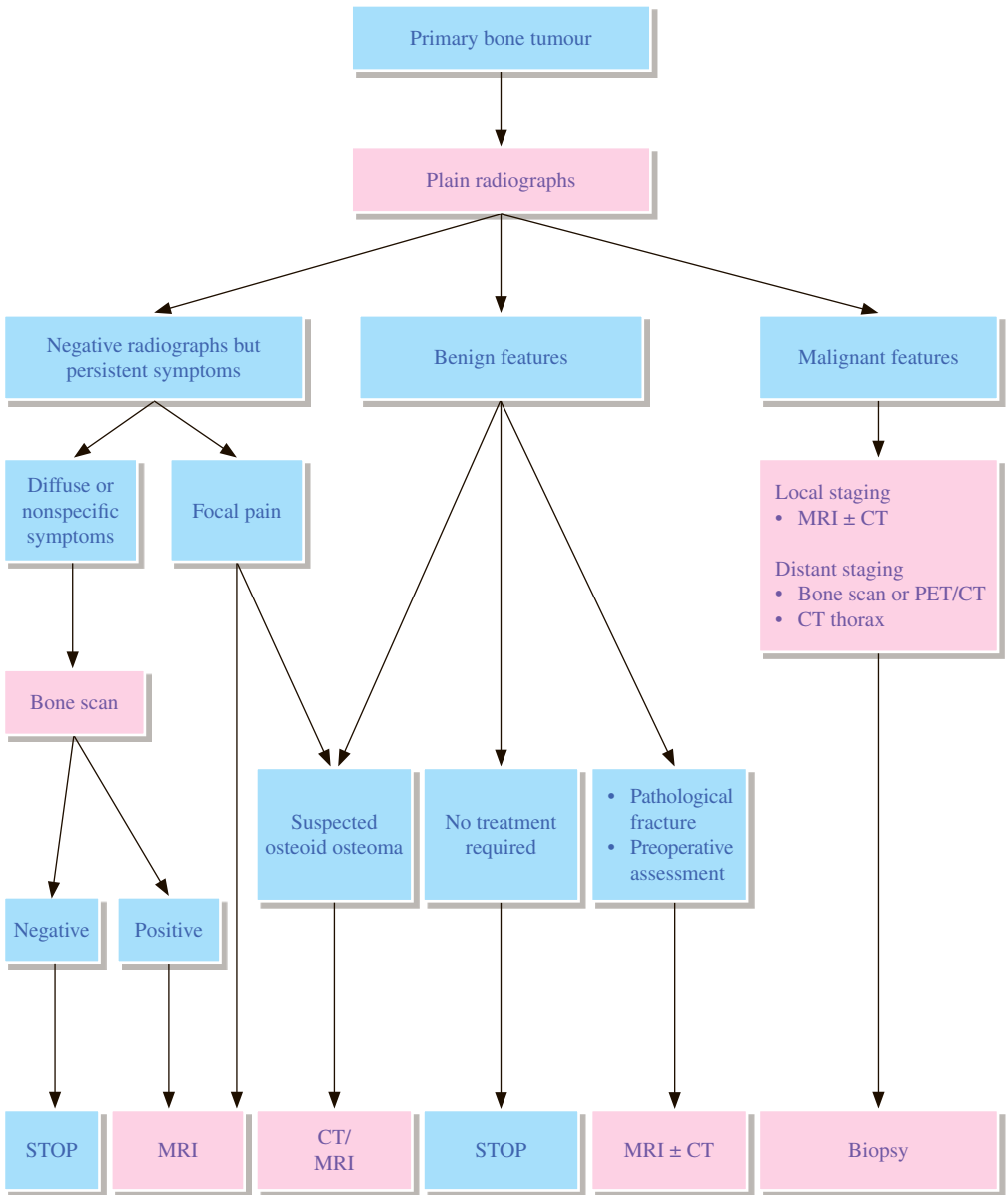
- 3.1 CT detects avascular necrosis of hip earlier than plain radiographs but it is less sensitive than both MRI and bone scan.
- 3.2 Its major role is to determine the severity of secondary degenerative changes and the extent of femoral head collapse.

4 MRI

- 4.1 MRI is the preferred method for detection of early occult avascular necrosis. It is also useful for disease staging.
- 4.2 It detects avascular necrosis in the contralateral hip.
- 4.3 It also shows other possible causes of hip pain.

REFERENCES

1. The Royal College of Radiologists. iRefer: Making the best use of clinical radiology. 7th ed. London: The Royal College of Radiologists; 2012. Section M21.
2. Murphey MD, Roberts CC, Bencardino JT, et al. ACR Appropriateness Criteria® Osteonecrosis of the Hip. Available at <https://acsearch.acr.org/docs/69420/Narrative/>. American College of Radiology. Accessed 2017 May 11.
3. Mitchell DG, Rao VM, Dalinka MK, Spritzer CE, Alavi A, Steinberg ME, et al. Femoral head avascular necrosis: correlation of MR imaging, radiographic staging, radionuclide imaging, and clinical findings. *Radiology*. 1987; 162: 709-715.
4. Murphy MD, Foreman KL, Klassen-Fischer MK, Fox MG, Chung EM, Kransdorf MF. From the Radiologic Pathology Archives Imaging of Osteonecrosis: Radiologic-Pathologic Correlation. *Radiographics*. 2014; 34: 1003-1028.



REMARKS

1 Plain radiograph

- 1.1 Regional radiographs are necessary for suspected bone tumour and remain the initial technique for the detection and characterization of tumours and tumour-like lesions.
- 1.2 For typical benign lesions, no further imaging is required unless there is a suspected complication or surgery is being considered.

2 Nuclear medicine

- 2.1 Bone scan is helpful when bony metastasis is suspected.
- 2.2 Baseline bone scan can exclude multicentricity.

3 CT

- 3.1 CT is the preferred method for assessment of cortical involvement, cortically-based tumours, flat bones with little marrow, and demonstration of tumour mineralization or calcification. It is complementary to MRI in this regard.
- 3.2 CT is indicated for confirmation and pre-surgical localization of osteoid osteoma following positive radiograph or bone scan.

4 MRI

- 4.1 MRI is the imaging modality of choice for assessment of bone marrow, soft tissue, juxta-articular and neurovascular involvement (i.e. local staging).

5 PET/CT

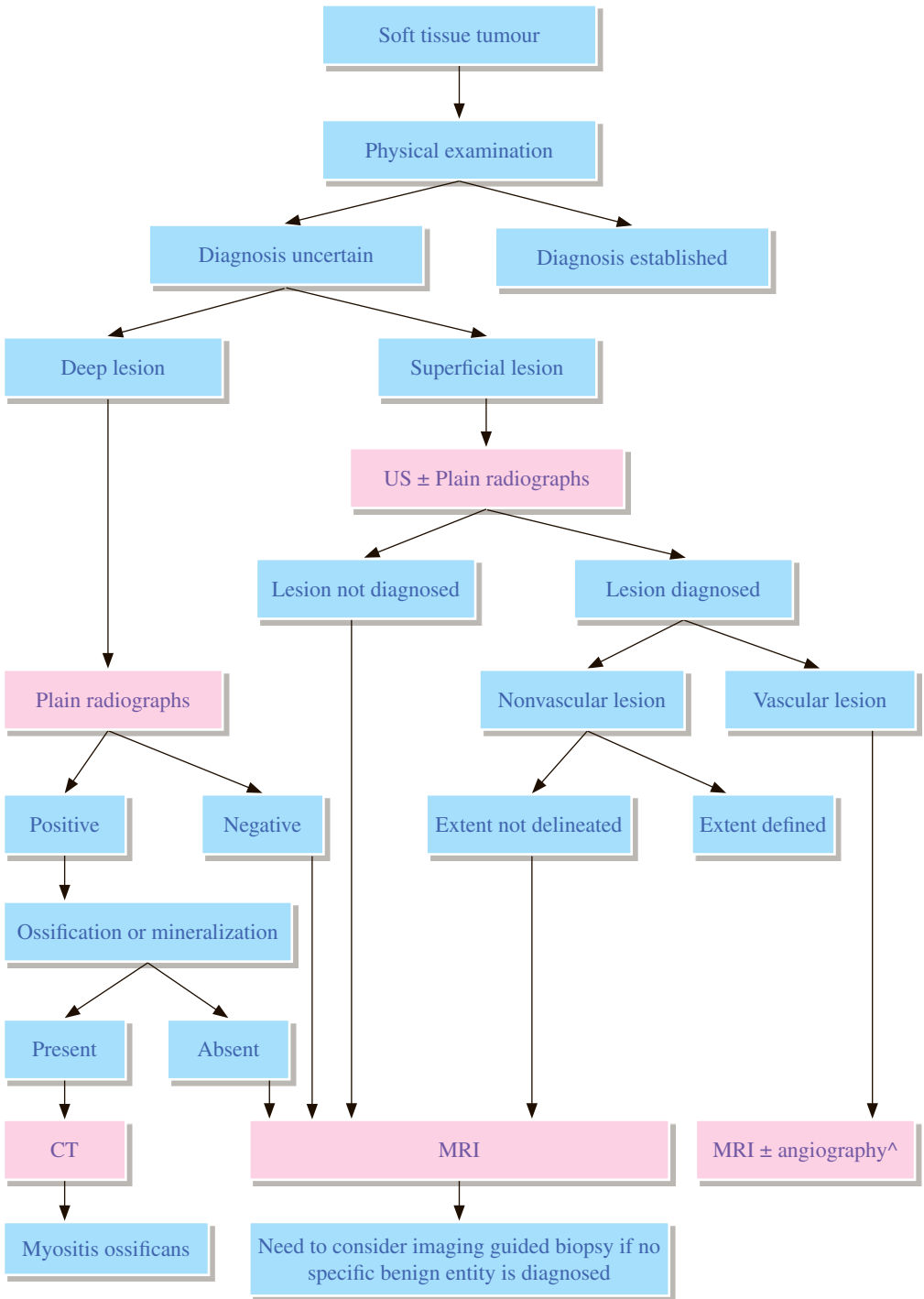
- 5.1 PET/CT has higher sensitivity and specificity than CT, MRI and bone scan for detecting distant metastases (except being less sensitive to pulmonary nodules).
- 5.2 It also has high sensitivity (90%), specificity (96%) and accuracy (95%) for differentiating primary bone tumour from osseous metastases.

6 Pathological diagnosis

- 6.1 Staging of the primary tumour should be completed first before any biopsy.
- 6.2 Biopsy should be carried out in close consultation with the orthopaedic surgeon planning the definitive treatment.

REFERENCES

1. The Royal College of Radiologists. iRefer: Making the best use of clinical radiology. 7th ed. London: The Royal College of Radiologists; 2012. Section M08.
2. Morrison WB, Weissman BN, Kransdorf MJ, et al. ACR Appropriateness Criteria® Primary Bone Tumors. Available at <https://acsearch.acr.org/docs/69421/Narrative/>. American College of Radiology. Accessed 2017 May 4.
3. Resnick D. Tumors and tumor-like lesions of bone: radiographic principles. Diagnosis of bone and joint disorders. Philadelphia, PA: Saunders, 2002: 3745-3762.
4. Von Kalle T, Langendorfer M, Fernandez FF, Winkler P. Combined dynamic contrast-enhancement and serial 3D-subtraction analysis in magnetic resonance imaging of osteoid osteomas. Eur Radiol. 2009; 19: 2508-2517.
5. Franzius C, Sciuk J, Daldrup-Link HE, Jurgens H, Schober O. FDG-PET for detection of osseous metastases from malignant primary bone tumours: comparison with bone scintigraphy. Eur J Nucl Med. 2000; 27: 1305-1311.
6. Costelloe CM, Chuang HH, Madewell JE. FDG PET/CT of primary bone tumours. AJR Am J Roentgenol. 2014; 202: W521-W531.
7. London K, Stege C, Cross S, Onikul E, Graf N, Kaspers G, et al. 18F-FDG PET/CT compared to conventional imaging modalities in pediatric primary bone tumours. Pediatr Radiol. 2012; 42: 418-430.
8. Stauss J, Hahn K, Mann M, De Palma D. Guidelines for paediatric bone scanning with 99mTc-labelled radiopharmaceuticals and 18F-fluoride. Eur J Nucl Med Mol Imaging. 2010; 37: 1621-1628.



^Remarks: Use angiography for subsequent treatment after the non-invasive diagnosis and mapping

REMARKS

1 Plain radiograph

- 1.1 Regional radiograph should be the initial imaging examination in evaluating soft tissue tumour, especially deep and nonpalpable one.
- 1.2 Radiograph helps to identify any underlying skeletal deformity (e.g. callus), exostosis (which simulates a soft tissue mass), coexisting osseous involvement (remodeling, periosteal reaction or overt destruction) and soft tissue calcification (e.g. phlebolith in haemangioma).
- 1.3 Low kV technique is preferred to enhance radiographic density of differences between soft tissue such as fat and muscle.

2 US

- 2.1 US is useful for superficial mass.
- 2.2 It can differentiate a localized mass from diffuse edema and solid from cystic lesion.
- 2.3 The role of US is to confirm the presence of a suspected lesion, identify its size, determine its internal characteristics, and guide percutaneous biopsy.

3 CT

- 3.1 CT is complementary to MRI in detecting soft tissue calcification or ossification and subtle bony abnormality.
- 3.2 Zonal pattern of mineralization of early myositis ossificans can be seen on CT allowing early diagnosis.

4 MRI

- 4.1 MRI is the examination of choice in imaging soft tissue lesion.
- 4.2 It is also useful in post-treatment follow-up.
- 4.3 It can be difficult to differentiate benignancy from malignancy with imaging alone.

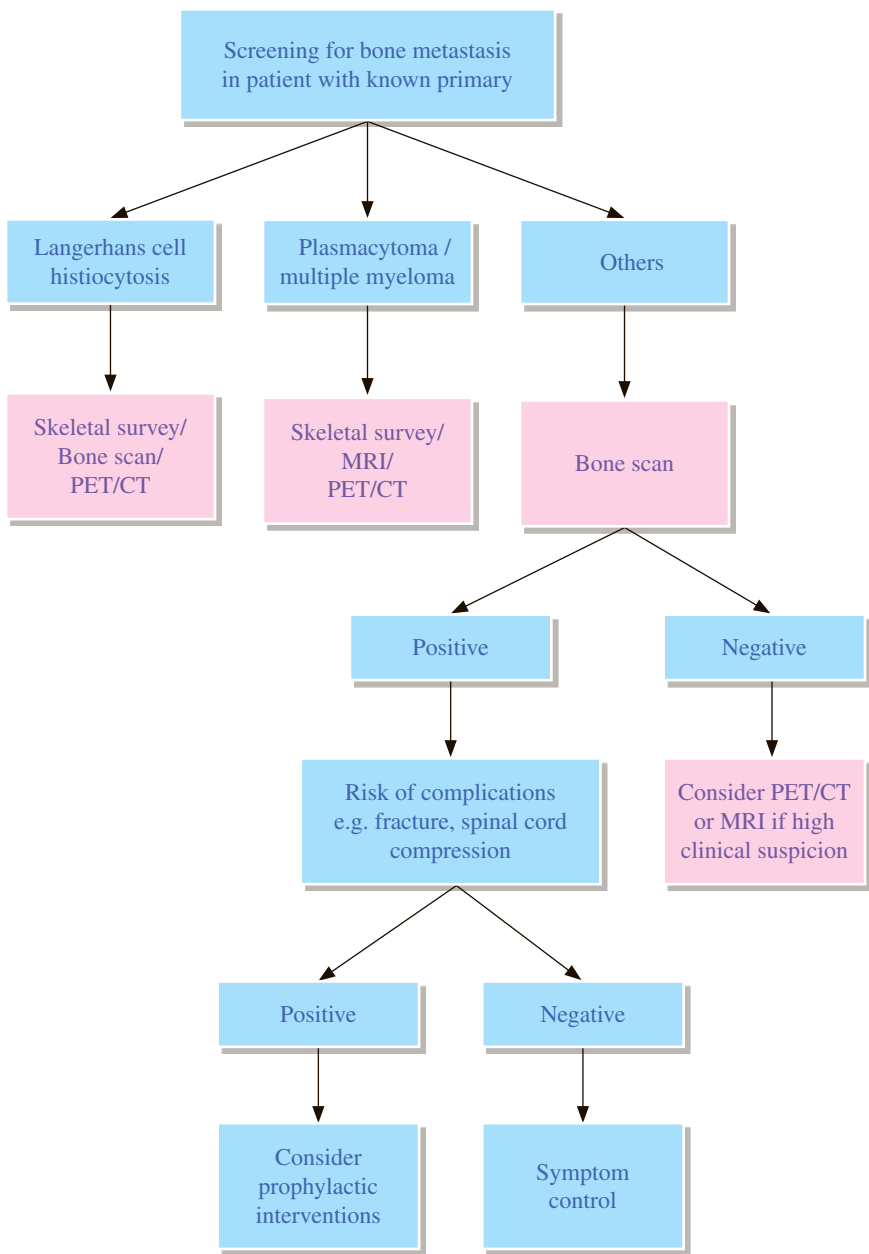
5 PET

- 5.1 PET is useful for staging and monitoring treatment response of the tumour.
- 5.2 It identifies nodal and osseous metastatic disease.
- 5.3 It may direct biopsy of those metabolically active areas in the tumour.

REFERENCES

1. The Royal College of Radiologists. iRefer: Making the best use of clinical radiology. 7th ed. London: The Royal College of Radiologists; 2012. Section M10.
2. Zoga AC, Weissman BN, Kransdorf MJ, et al. ACR Appropriateness Criteria® Soft-Tissue Masses. Available at <https://acsearch.acr.org/docs/69434/Narrative/>. American College of Radiology. Accessed 2017 May 4.
3. Kransdorf MJ, Murphey MD. Imaging of soft tissue tumors. 3rd ed. Philadelphia: W.B.Saunders; 2014. p. 39-94.
4. Wu JS, Hochman MG. Soft tissue tumors and tumorlike lesions: a systemic imaging approach. *Radiology*. 2009; 53: 297-316.

MS 6 Screening for bone metastasis with known primary malignancy



REMARKS

1 Plain radiograph

- 1.1 Plain radiograph should be taken selectively corresponding to scintigraphically positive osseous region.
- 1.2 Skeletal survey should only be performed in Langerhans cell histiocytosis, plasmacytoma and multiple myeloma.

2 Nuclear medicine

- 2.1 Bone scan is a sensitive, cheap and widely available imaging modality for detection of skeletal metastasis.
- 2.2 False negative bone scan results may occur in cases of Langerhans cell histiocytosis, plasmacytoma, multiple myeloma and renal cell carcinoma.
- 2.3 PET/CT is valuable in evaluating multiple myeloma and Langerhans cell histiocytosis.

3 CT

- 3.1 CT is useful in defining the degree of bone destruction and therefore should only be used in specific situations.

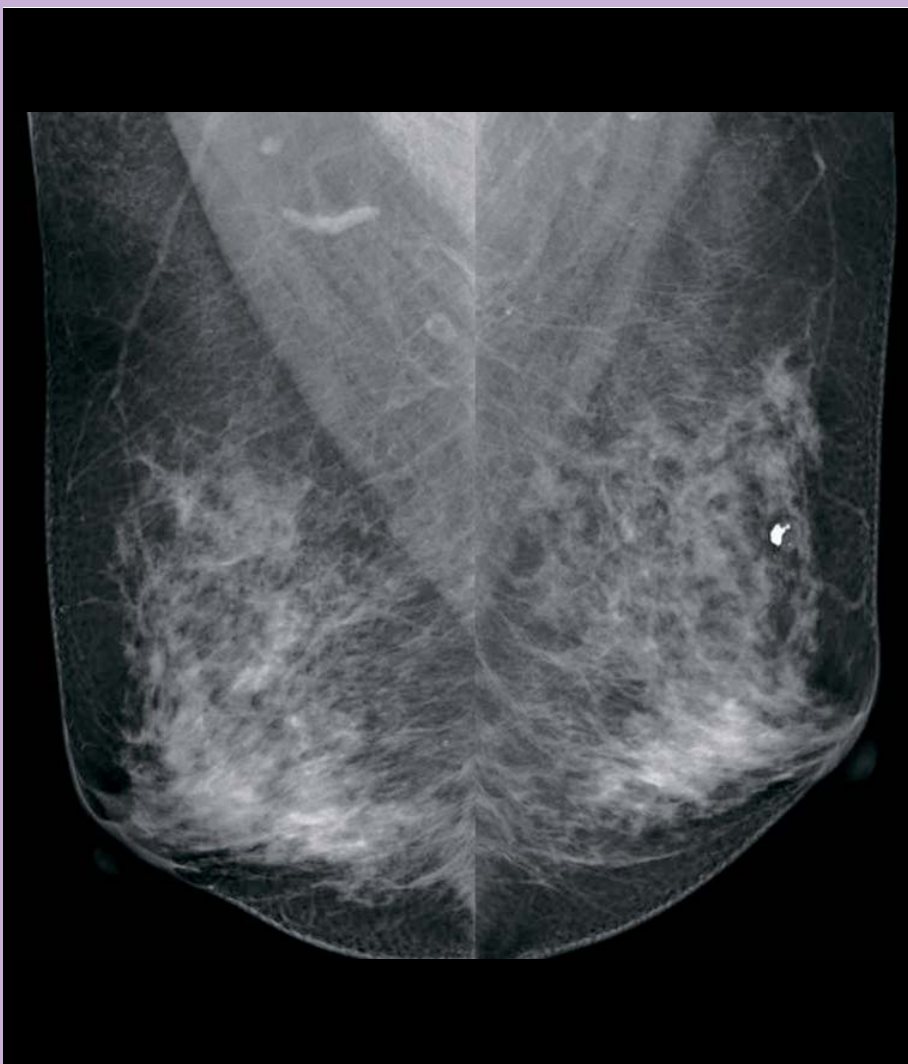4 MRI

- 4.1 MRI is useful in specific situations such as marrow based lesions.

REFERENCES

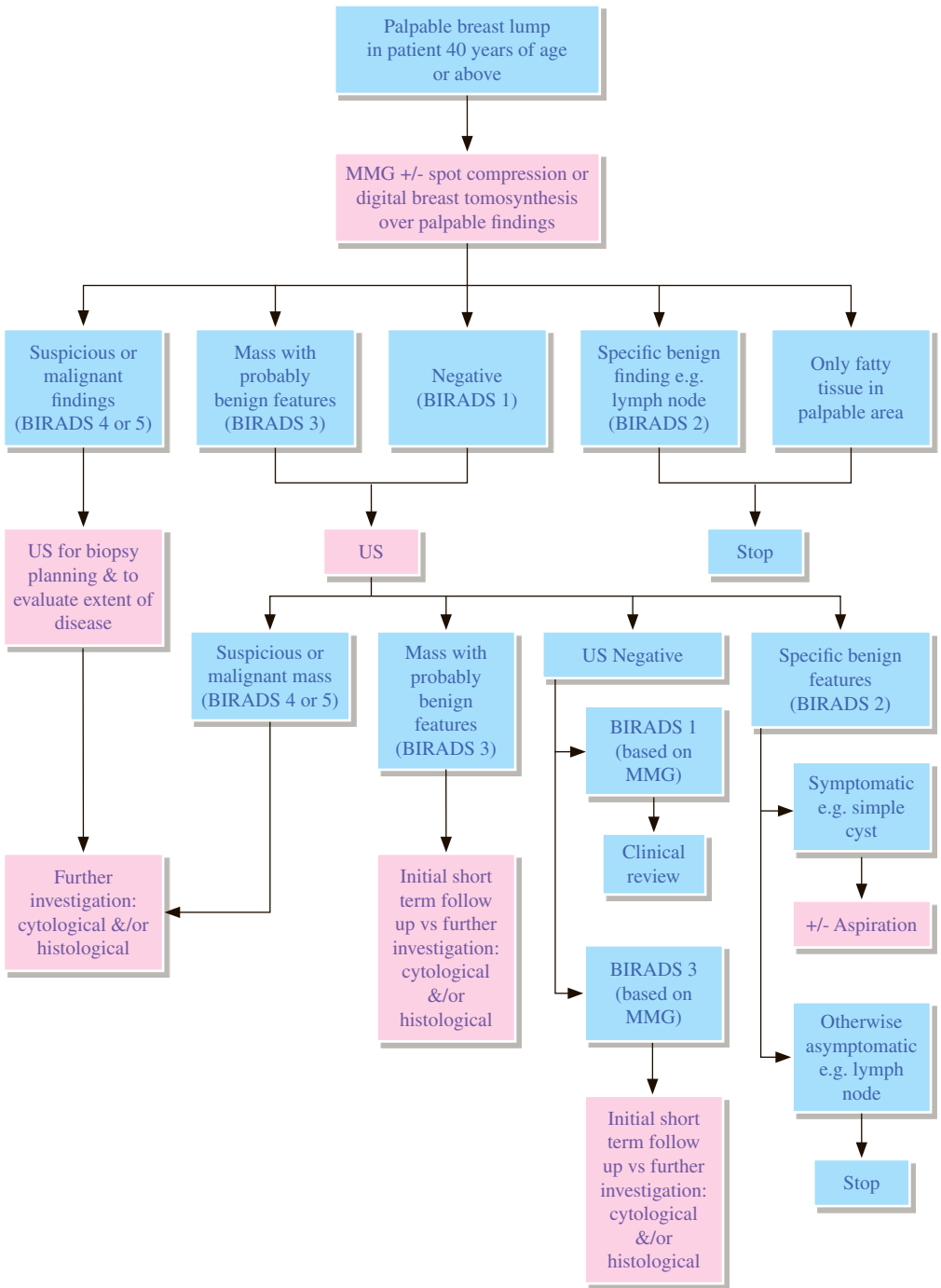
1. The Royal College of Radiologists. iRefer. Making the best use of clinical radiology. 7th ed. London: The Royal College of Radiologists; 2012. Section M09.
2. Roberts CC, Weissman BN, Appel M, et al. ACR Appropriateness Criteria® Metastatic Bone Disease. Available at <https://acsearch.acr.org/docs/69431/Narrative/>. American College of Radiology. Accessed 2017 May 10.
3. Taira AV, Herfkens RJ, Gambhir SS, Quon A. Detection of bone metastases: Assessment of integrated FDG PET/CT imaging. *Radiology*. 2007; 243: 204–211.
4. Agarwal A, Chirindel A, Shah BA, Subramaniam RM. Evolving role of FDG PET/CT in multiple myeloma imaging and management. *AJR Am J Roentgenol*. 2013; 200: 884-890.

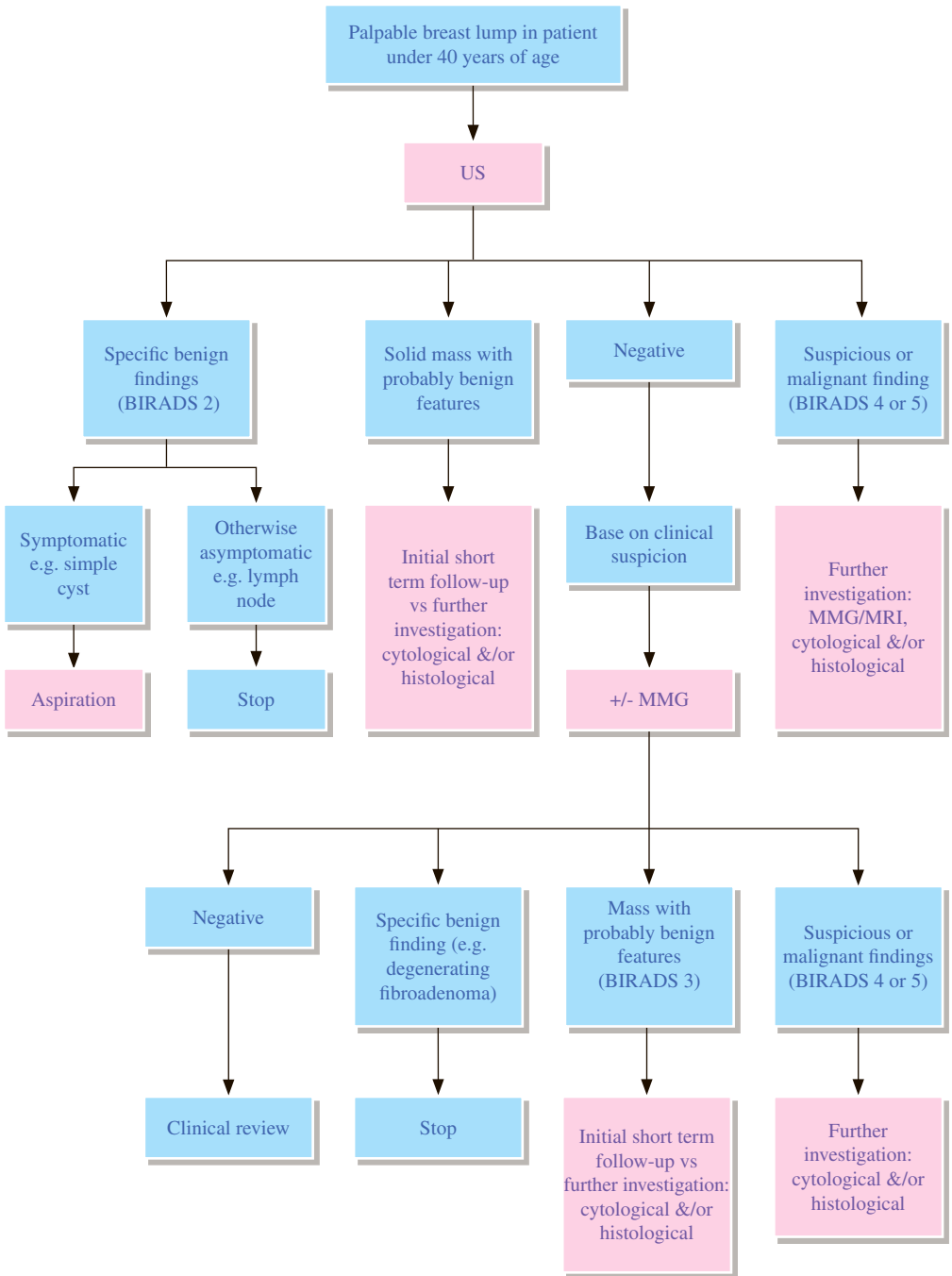
Breast Radiology



Hong Kong College of Radiologists

BR 1 Palpable breast lump





REMARKS

1. General

- 1.1 Less than 7% of breast cancers occur in women under 40 years of age.³
- 1.2 Risk factors for breast cancer are^{4,5,8}:
 - 1.2.1 Major risk factors : BRCA1 or BRCA2 mutation
first degree relative with a BRCA1 or BRCA2 mutation
history of radiation to the chest between the age of 10 and 30
certain clinical syndromes e.g. Li-Fraumeni syndrome
 - 1.2.2 Minor risk factors : history of lobular carcinoma in-situ or atypical lobular hyperplasia
history of atypical ductal hyperplasia
history of breast cancer including ductal carcinoma in-situ
very dense breasts
hormonal replacement therapy
more menstrual cycles
nulliparity or late age at first live birth
obesity
never breastfed
alcohol consumption

2. Mammography (MMG)

- 2.1 Diagnostic MMG is the initial exam for evaluating a palpable mass for women aged 40 or older. Because of increased radiation risk, lower sensitivity of MMG, and lower incidence of breast cancer in younger women, US is therefore the initial imaging modality in younger women.⁹
- 2.2 A negative MMG does not exclude breast cancer.⁶
- 2.3 Low-dose radiation increases breast cancer risk among high-risk women especially at a younger age.⁸
- 2.4 The risk of developing breast cancer from radiation exposure secondary to MMG in women under the age of 35 is estimated to be 7 excess cancers per million women per year per rad.⁷

3. US

- 3.1 US is useful in avoiding unnecessary biopsy of cysts.⁷
- 3.2 US is helpful in differentiating benign from malignant solid masses but tumours like medullary and colloid carcinoma may look benign sonographically.³
- 3.3 For evaluation of a palpable mass, US is the modality of choice for women under age of 30 and can also be used as the first line investigation for women aged 30 to 39 years.⁹

4. MRI

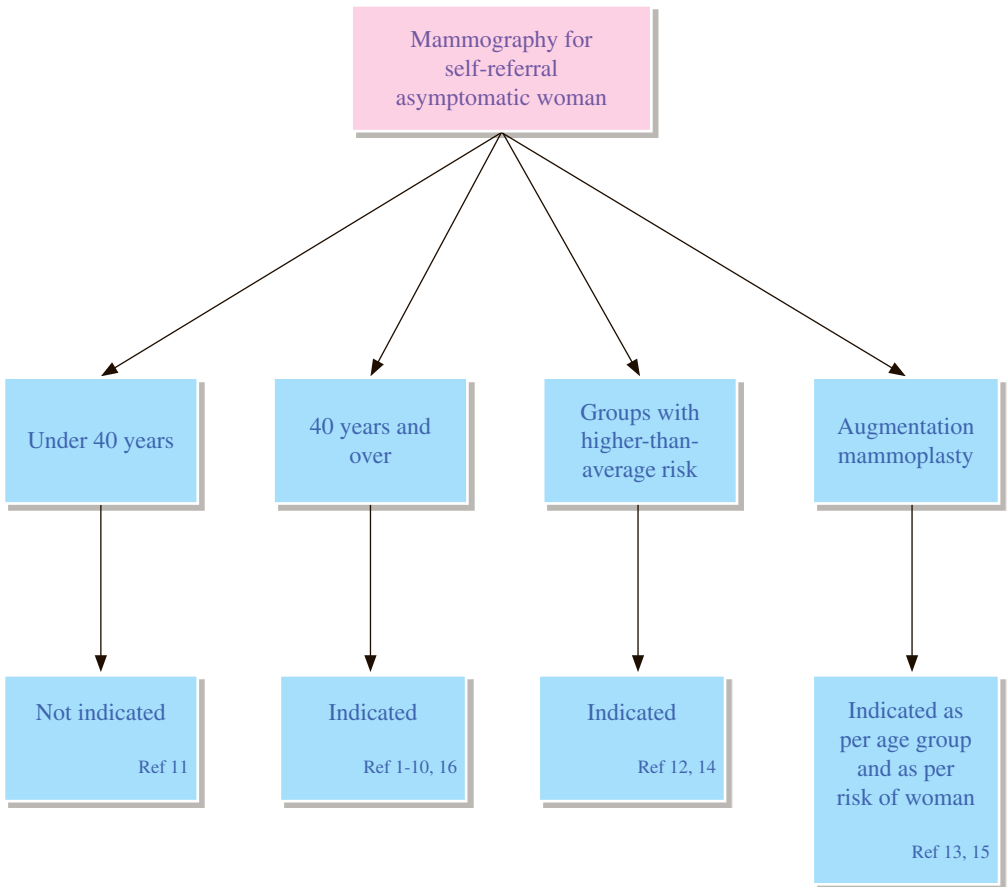
- 4.1 MRI may be useful for evaluating the extent of biopsy proven breast malignancy in glandular tissue. Otherwise it is less cost-effective than MMG and US as the initial imaging examinations for evaluating palpable mass.⁹

5. Pathological diagnosis

- 5.1 If a palpable mass is not visible by either MMG or US, the lesion should be assumed to be solid, and biopsy should be considered if the clinical findings are suspicious of malignancy.³

REFERENCES

1. Royal Australasian College of Radiologists. Imaging guidelines. 3rd ed. Melbourne: Royal Australasian College of Radiologists; 1997. p. 154-155.
2. Feig SA. Mammographic and sonographic evaluation. *Radiol Clin North Am* 1992; 30: 67-92.
3. Anders CK, Johnson R, Litton J, Phillips M, Bleyer A. Breast Cancer Before Age 40 Years. *Semin Oncol*. 2009; 36: 237-249.
4. Smith RA. Epidemiology of breast cancer. In: Haus AG, Yaffe MJ, editors. A categorical course in physics - technical aspects of breast imaging. Oak Brook: Radiological Society of North America; 1992. p. 21-30.
5. The Royal College of Radiologists. iRefer: Making the best use of clinical radiology. 7th ed. London: The Royal College of Radiologists; 2012. Sections B08-B16.
6. Fagerholm MI. Before the mammogram. In: Peters ME, Voegeli DR, Scanlan KA, editors. Handbook of breast imaging. New York: Churchill Livingstone; 1989. p. 53-55.
7. Bassett LW, Ysrael M, Gold RH, Ysrael C. Usefulness of mammography and sonography in women less than 35 years of age. *Radiology*. 1991; 180: 831-835.
8. Afonso N. Women at High Risk for Breast Cancer – What the Primary Care Provider Needs to Know. *J Am Board Fam Med*. 2009; 22: 43-50.
9. Harvey JA, Mahoney MC, Newell MS, et al. ACR Appropriateness Criteria Palpable Breast Masses. *J Am Coll Radiol*. 2016; 13(11S): e31-e42.
10. Breast Cancer Working Group of Department of Health. Best practice diagnostic guidelines for patients presenting with breast symptoms. London: Department of Health; 2010. p. 15-16.



REMARKS

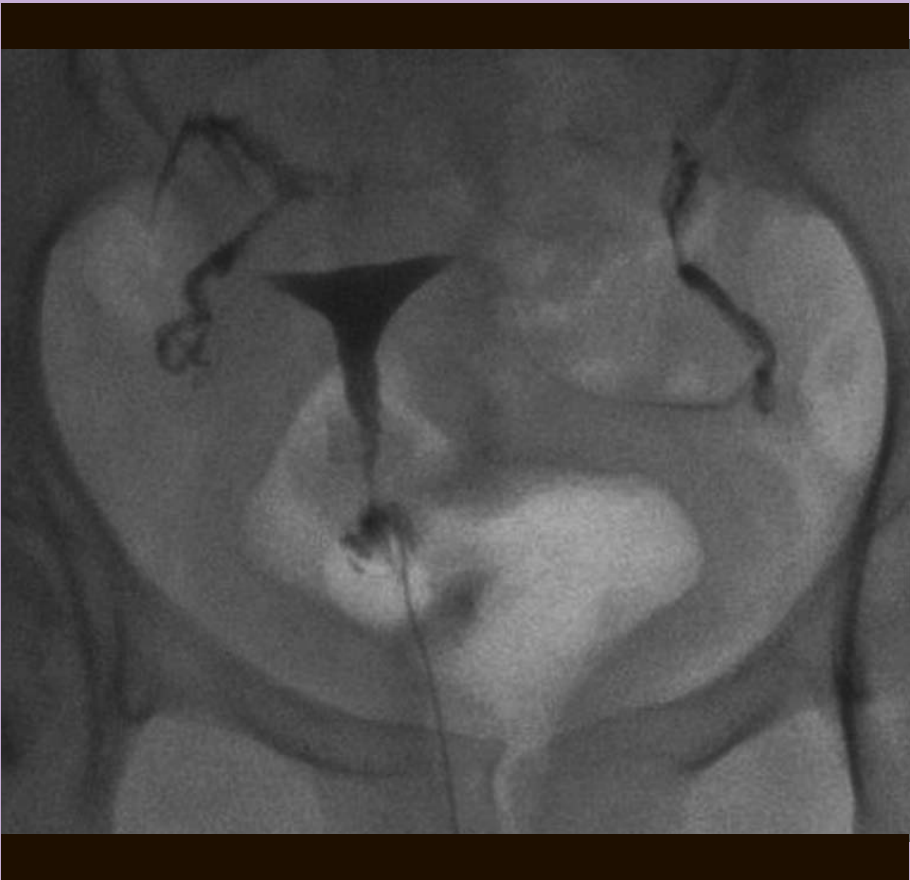Woman categories	Mammography	Comment
Aged 40 years and over	Indicated	<p>Randomized controlled trials, population studies and meta-analyses have shown that screening by mammography (MMG) can reduce mortality in breast cancer in women aged 40 years or above.¹⁻⁸ The American Cancer Society recommends starting annual MMG screening at the age of 40 and continuing it though the women are in good health.⁹ The American College of Radiology and the Society of Breast Imaging also recommend women with average risk for breast cancer to start annual screening from age 40.¹⁰ In Sweden, the breast cancer screening programme covers women between 40 and 74 years of age with MMG every two years.</p> <p>Whilst there is evidence of a mortality reduction from MMG screening in women between the ages of 40-50 years, it should be acknowledged that there is no good quality evidence of a mortality reduction from screening women over the age of 70 and the risk of over diagnosis is substantially greater.</p> <p>Advice from clinicians and shared decision making with the women are important. Benefits and risks of screening should be discussed between the women and the clinician. The decision whether “to screen or not” should be taken together according to the woman's values and the clinician’s advice, after the consideration of the presence or absence of known risk factors.¹⁶</p>
Aged under 40 years	Not indicated, except in groups with high-risk or intermediate-risk	<p>There is no evidence of a mortality benefit from MMG screening of women under the age of 35 years. There is also a greater risk of radiation-induced breast cancer from the use of diagnostic X-ray MMG in young women. For these reasons, routine screening of women in this age group in the absence of significant breast cancer risk factors is not recommended unless as part of a formal trial.¹¹</p>

<p>Groups with high-risk or intermediate-risk</p>	<p>Indicated</p>	<p>Women who are at higher-than-average risk of breast cancer should seek medical advice about whether they should receive screening, age to start and the frequency of screening because the risk of developing breast cancer may be sufficiently high to justify MMG screening.¹²</p> <p>Groups with high-risk or intermediate-risk include:</p> <ol style="list-style-type: none"> a. women with a BRCA gene mutation and their untested first- degree relatives¹⁴; b. women with a history of chest irradiation between the ages of 10-30¹⁴; c. women with personal history of breast cancer, lobular neoplasia, atypical ductal hyperplasia¹⁴; d. women with 15% or greater lifetime risk of breast cancer.¹⁴
<p>Augmentation mammoplasty</p>	<p>Indication as per age group and as per risk of woman.</p>	<p>There is no evidence that breast augmentation is associated with an increased incidence of carcinoma. The risk of prosthesis rupture as a result of compression during MMG is extremely small and in practical terms can be discounted.¹³</p> <p>However, sensitivity for cancer detection is lower than in the non-augmented breast. Digital MMG may help.¹⁵</p>

REFERENCES

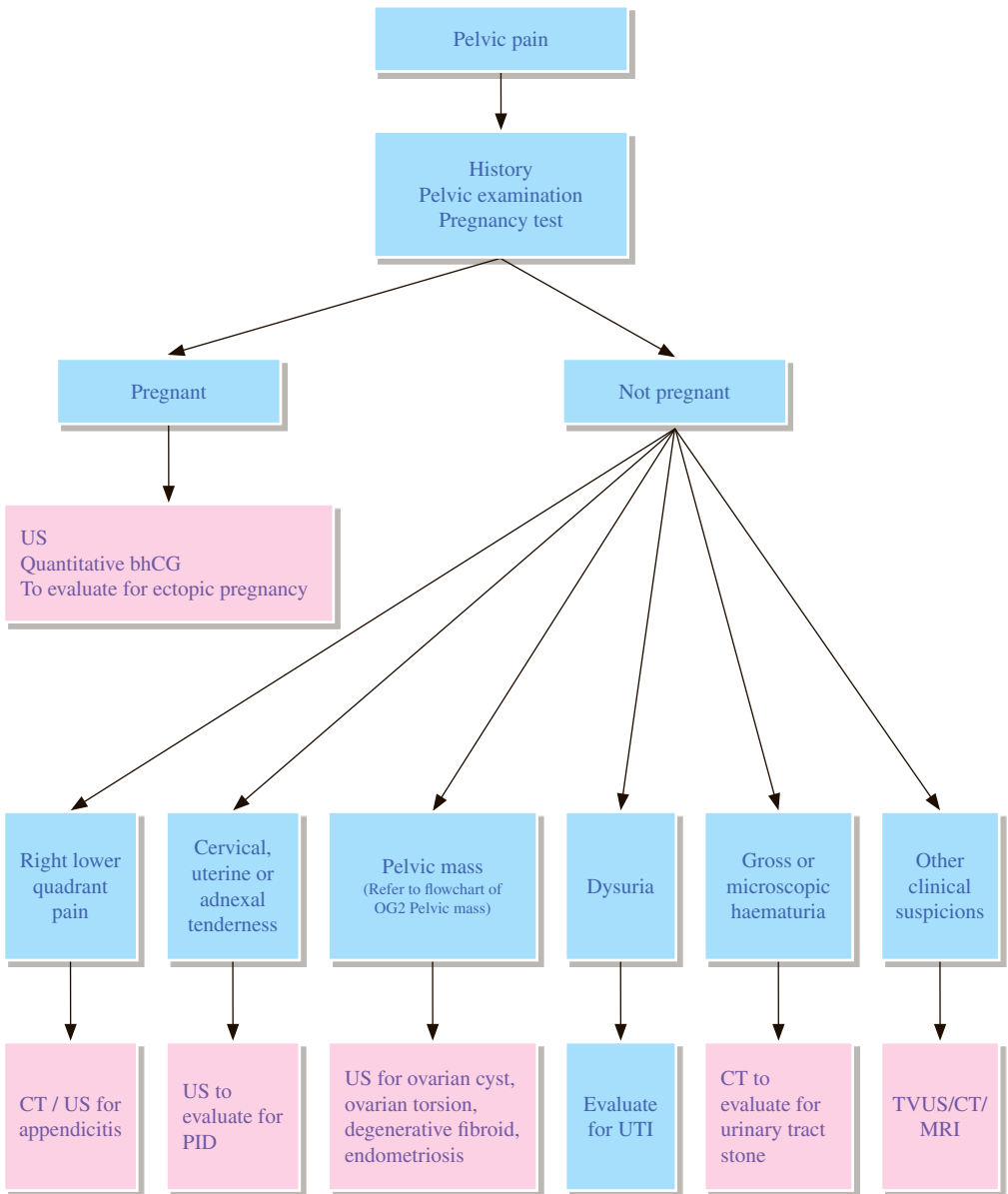
1. Kerlikowske K, Grady D, Barclay J, Sickles EA, Eaton A, Ernster V. Positive predictive value of screening mammography by age and family history of breast cancer. *JAMA*. 1993; 270: 2444-2450.
2. Evans AJ, Kutt E, Record C, Waller M, Moss S. Radiological findings of screen-detected cancers in a multi-centre randomized, controlled trial of mammographic screening in women from age 40 to 48 years. *Clin Radiol*. 2006; 61: 784-788.
3. de Koning HJ, Boer R, Warmerdam PG, Beemsterboer PMM, van der Maas PJ. Quantitative interpretation of age-specific mortality reductions from the Swedish breast cancer-screening trials. *J Natl Cancer Inst*. 1995; 87: 1217-1223.
4. Hendrick RE, Smith RA, Rutledge JH, Smart CR. Benefit of screening mammography in women ages 40-49: a new meta-analysis of randomized controlled trials. *J Natl Cancer Inst Monogr*. 1997; 22: 87-92.
5. Moss SM, Cuckle H, Evans A, Johns L, Waller M, Bobrow L. Effect of mammographic screening from age 40 years on breast cancer mortality at 10 years' follow-up: a randomised controlled trial. *Lancet*. 2006; 368: 2053-2060.
6. Bjurstam N, Bjorneld L, Duffy SW, Smith TC, Cahlin E, Erikson O, et al. The Gothenberg Breast Cancer Screening Trial: preliminary results on breast cancer mortality for women ages 39-49. *J Natl Cancer Inst Monogr*. 1997; 22: 53-55.
7. Andersson I, Janzon L. Reduced breast cancer mortality in women under 50: update from the Malmö mammographic screening program. *J Natl Cancer Inst Monogr*. 1997; 22: 63-67.
8. Kopans DB, Monsees B, Feig SA. Screening for cancer: when is it valid? Lessons from the mammography experience. *Radiology*. 2003; 229: 319-327.
9. American Cancer Society. Breast Cancer: Early Detection. Available at <http://www.cancer.org/acs/groups/cid/documents/webcontent/003165-pdf.pdf>. American Cancer Society. Accessed 2014 Mar 5.
10. Lee CH, Dershaw DD, Kopans D, Evans P, Monsees B, Monticciolo D, et al. Breast Cancer Screening with Imaging: Recommendations From the Society of Breast Imaging and the ACR on the Use of Mammography, Breast MRI, Breast Ultrasound, and Other Technologies for the Detection of Clinically Occult Breast Cancer. *J Am Coll Radiol*. 2010; 7: 18-27.
11. The Royal College of Radiologists. Guidance on Screening and Symptomatic Breast Imaging, Third Edition. London: The Royal College of Radiologists; 2013. p. 5-6.
12. Ying ACH. Guidelines for Cancer Prevention, Early Detection and Screening, Breast Cancer. Hong Kong: The Hong Kong Anti-Cancer Society; 2009 Feb.
13. The Royal College of Radiologists. Making the best use of a department of clinical radiology. 4th ed. London: The Royal College of Radiologists; 1998. p. 68-70.
14. Mainiero MB, Bailey L, D'Orsi C, et al. ACR Appropriateness Criteria® Breast Cancer Screening. Available at <https://acsearch.acr.org/docs/70910/Narrative/>. American College of Radiology. Accessed 2017 May 17.
15. The Royal College of Radiologists. iRefer: Making the best use of clinical radiology. 7th ed. London: The Royal College of Radiologists; 2012. Section B07.
16. Hong Kong College of Radiologists. HKCR Mammography Statement, Revised Version. Hong Kong: Hong Kong College of Radiologists; 2015.

Obstetric and Gynaecological Radiology



Hong Kong College of Radiologists

OG 1 Pelvic pain



REMARKS

1 General

- 1.1 Caution should be taken to avoid taking abdominal and pelvic radiographs during pregnancy.
- 1.2 With careful history taking, physical examination and simple laboratory tests, some of the causes of pelvic pain such as cystitis can be diagnosed without further radiological examinations.
- 1.3 Urgent life threatening conditions (e.g. ectopic pregnancy, appendicitis, ruptured ovarian cyst) and fertility-threatening conditions (e.g. pelvic inflammatory disease, ovarian torsion) must be considered.

2 Plain radiograph

- 2.1 Pelvic radiograph is useful to diagnose musculoskeletal causes of pelvic pain such as sacroiliac joint disease.

3 US

- 3.1 US should be initial imaging test due to its ability to narrow the differential diagnosis and lack of radiation exposure.
- 3.2 Transvaginal ultrasound (TVUS) has better resolution and is particularly useful for detailed pelvic assessment. However, owing to its limited penetrating power, large pelvic lesion may necessitate transabdominal ultrasound for complete visualisation.
- 3.3 For pelvic inflammatory disease (PID), a negative US examination does not rule out infection.
- 3.4 Colour Doppler is useful in detection of vascular lesion and determination of perfusion status in ovarian torsion.

4 CT

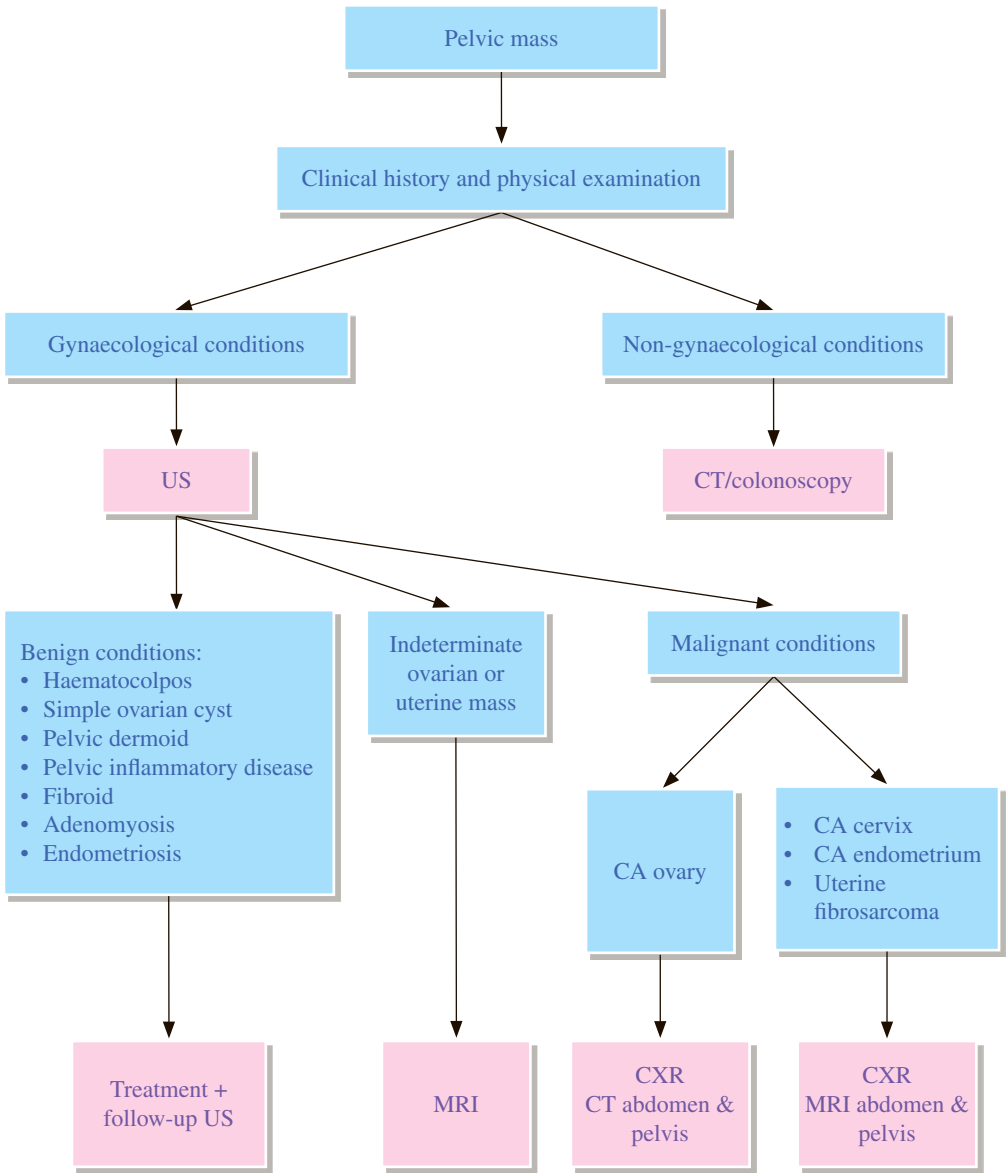
- 4.1 CT is more useful when gastrointestinal or urinary tract pathology is suspected.

5 MRI

- 5.1 With its high soft tissue contrast sensitivity, MRI is useful for further evaluation as a problem solving tool and assessment of the disease extent.
- 5.2 With its lack of ionizing radiation, MRI is preferred over CT for assessing pregnant patients; however, it is hampered by lack of widespread availability, especially in the acute setting.

REFERENCES

1. The Royal College of Radiologists. iRefer: Making the best use of clinical radiology. 7th ed. London: The Royal College of Radiologists, 2012.
2. Kruszka PS, Kruszka SJ. Evaluation of Acute Pelvic Pain in Women. *Am Fam Physician*. 2010; 82: 141-147.
3. Bazot M, Lafont C, Rouzier R, Roseau G, Thomassin-Naggara I, Darai E. Diagnostic accuracy of physical examination, transvaginal sonography, rectal endoscopic sonography, and magnetic resonance imaging to diagnose deep infiltrating endometriosis. *Fertil Steril*. 2009; 92: 1825-1833.
4. Timor-Tritsch IE, Lerner JP, Monteagudo A, Murphy KE, Heller DS. Transvaginal sonographic markers of tubal inflammatory disease. *Ultrasound Obstet Gynecol*. 1998; 12: 56-66.
5. Potter AW, Chandrasekhar CA. US and CT evaluation of acute pelvic pain of gynecologic origin in nonpregnant premenopausal patients. *Radiographics*. 2008; 28: 1645-1659.



REMARKS

1 US

- 1.1 A pelvic US is the single most effective way of evaluating an ovarian mass with transvaginal US preferred due to its increased sensitivity over transabdominal US.
- 1.2 A combination of the transvaginal and transabdominal routes may be appropriate for the assessment of larger masses and extra-ovarian disease.
- 1.3 There is not yet a clearly established role for colour-flow Doppler in assessing ovarian cysts.
- 1.4 Ovarian cysts that persist or increase in size after several cycles are unlikely to be functional.
- 1.5 In large pelvic mass or suspected pelvic malignancy, renal areas should be examined to exclude hydronephrosis.
- 1.6 The routine use of CT and MRI for assessment of ovarian masses does not improve the sensitivity or specificity obtained by transvaginal US in the detection of ovarian malignancy.

2 CT

- 2.1 CT is useful to delineate high pelvic or iliac fossa lesion, the tumour extent, and to assess metastasis.

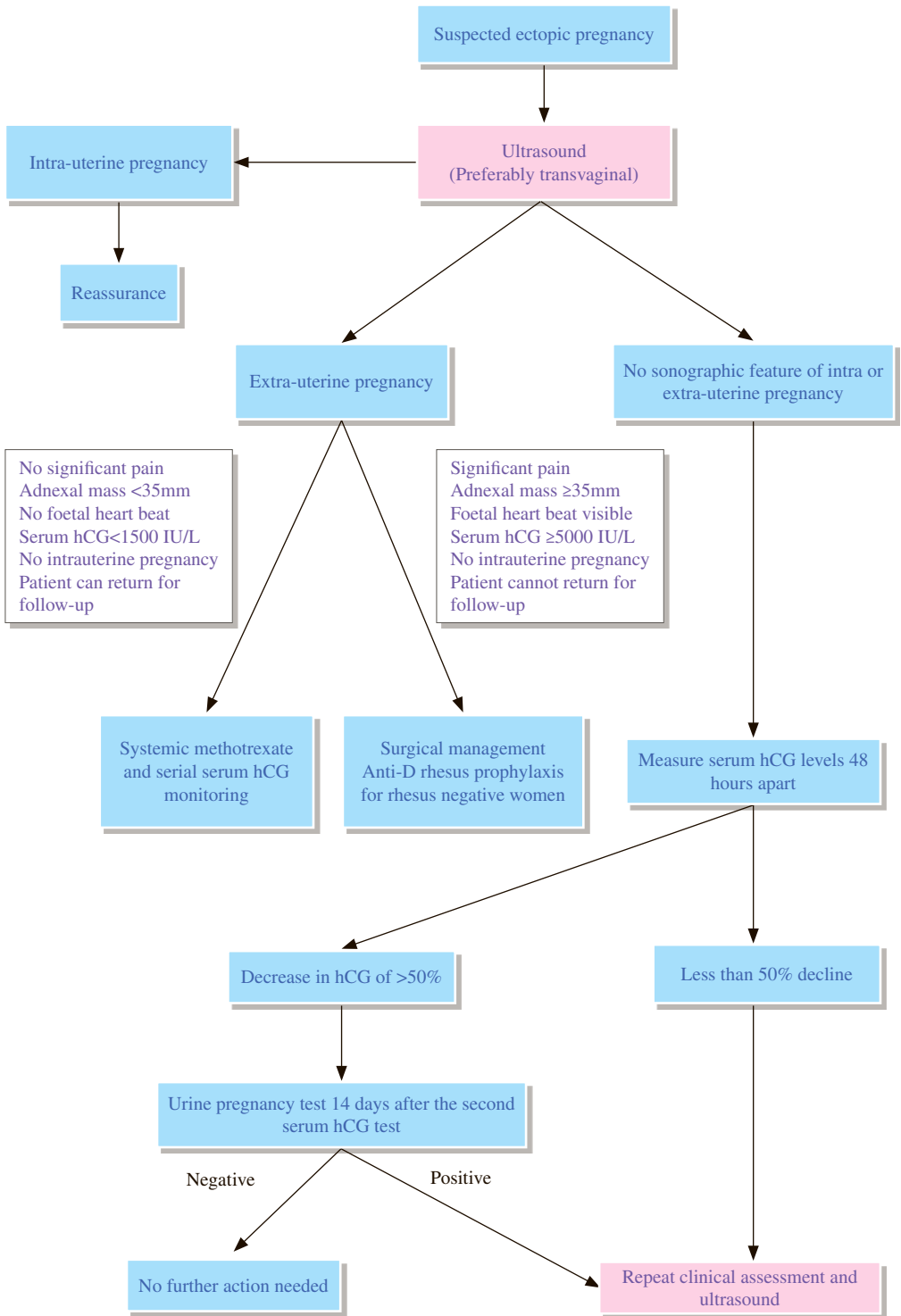
3 MRI

- 3.1 With its high soft tissue contrast sensitivity, MRI is useful for further characterization of indeterminate ovarian or uterine mass and for local staging of uterine/cervical malignancy.
- 3.2 For workup of CA ovary, MRI is recommended for patients with a contraindication to the use of iodinated contrast agents (e.g. allergy, mild-to-moderate renal insufficiency), patients who are pregnant, patients of childbearing age with borderline tumours (to minimize ionizing radiation exposure).

REFERENCES

1. Royal Australian College of Radiologists. Imaging guidelines. 3rd ed. Melbourne: Royal Australian College of Radiologists; 1997. p.152-153.
2. Royal College of Obstetricians and Gynaecologists. Management of Suspected Ovarian Masses in Premenopausal Women. Green-top Guideline No.62. London: Royal College of Obstetricians and Gynaecologists; 2011.
3. Royal College of Obstetricians and Gynaecologists. Ovarian Cysts in Postmenopausal Women. Green-top Guideline No. 34. London: Royal College of Obstetricians and Gynaecologists; 2010.
4. Mitchell DG, Javitt MC, Glanc P, et al. ACR Appropriateness Criteria® Staging and Follow-up of Ovarian Cancer. Available at <https://acsearch.acr.org/docs/69378/Narrative/>. American College of Radiology. Accessed 2017 April 4.
5. Lalwani N, Dubinsky T, Javitt MC, et al. ACR Appropriateness Criteria® Pretreatment Evaluation and Follow-Up of Endometrial Cancer. Available at <https://acsearch.acr.org/docs/69459/Narrative/>. American College of Radiology. Accessed 2017 April 4.

OG 3 Suspected ectopic pregnancy



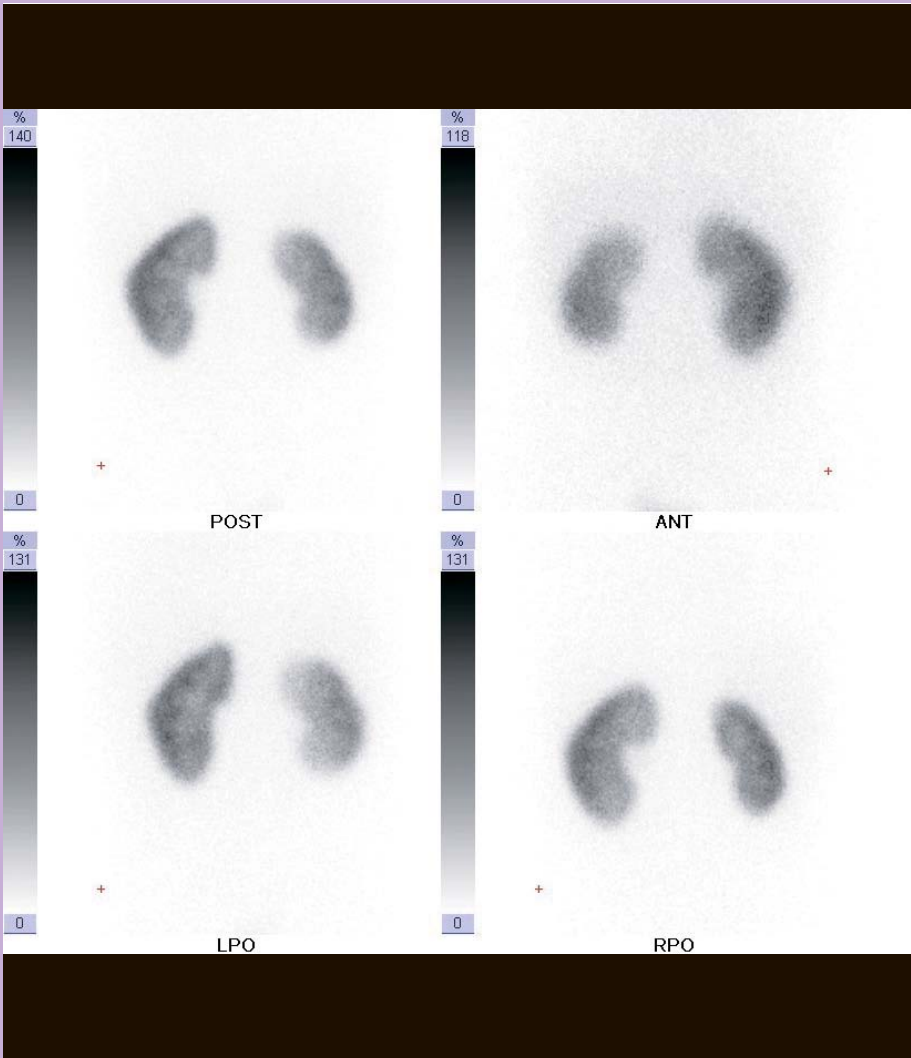
REMARKS

- 1 Heterotopic pregnancy occurs in only 1:7000 to 1:30000 of spontaneously conceived pregnancies. The chance is up to 1% in pregnancies after assisted reproduction techniques.
- 2 Apart from ectopic pregnancy, absence of intrauterine pregnancy can be due to wrong dates or complete miscarriage.
- 3 Failure to detect an intrauterine gestational sac by transvaginal ultrasound when serum hCG level is >1500 IU/L indicates an increased risk for ectopic pregnancy.

REFERENCES

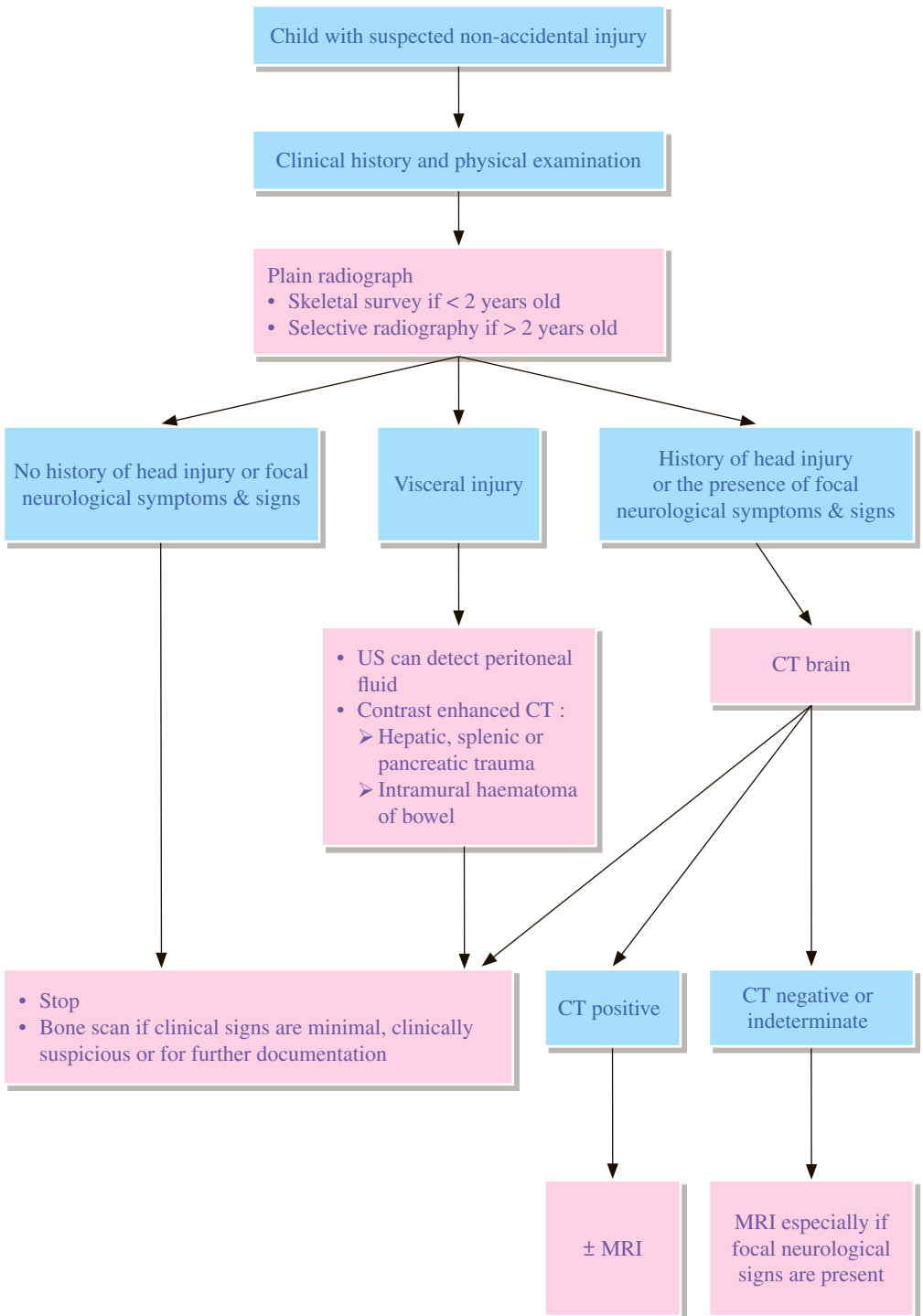
1. National Institute for Health and Clinical Excellence (2012). Ectopic pregnancy and miscarriage: diagnosis and initial management. NICE guideline (CG154).
2. National Institute for Health and Care Excellence 2015. Management of pregnancy of unknown location. NICE Pathways.
3. Morin L, Van den Hof MC. Ultrasound Evaluation of First Trimester Pregnancy Complications. SOGC Clinical Practice Guideline 161. J Obstet Gynaecol Can. 2005; 27: 581-585.

Paediatric Radiology



Hong Kong College of Radiologists

PD 1 Suspected non-accidental injury



REMARKS

1 General

- 1.1 Child abuse is not an imaging diagnosis. The role of imaging is to support the clinical diagnosis of child abuse in the proper clinical and social context and also to assist the evaluation of the severity and extent of injury.

2 Musculoskeletal trauma

- 2.1 Skeletal survey includes skull (frontal and lateral), spine (lateral cervical, thoracic and lumbar), chest (frontal including clavicles, and oblique views of bilateral ribs), abdomen (frontal, including pelvis and both hips), upper extremities (frontal humeri, forearms, and hands), and lower extremities (frontal femora, lower legs, and feet).
- 2.2 Conventional radiography is the primary imaging examination for musculoskeletal trauma.
- 2.3 Avoid 'babygram' as it is diagnostically inadequate.
- 2.4 Complete skeletal survey is normally indicated in children less than 2 years of age who have clinical evidence of child abuse, or in infants less than 1 year of age who show evidence of significant neglect and deprivation. In children between 2 years and 5 years of age, the skeletal survey may be tailored according to history and physical examination findings.
- 2.5 **For children more than 5 years old, skeletal survey is rarely indicated.**
- 2.6 Bone scans may be considered for children in whom skeletal survey is negative but clinical suspicion of non-accidental injury (NAI) is high. Bone scan is sensitive for the extent of bone injury, acute non-displaced and subtle healing fractures. Its pitfalls include normal uptake around the growth plates leading to difficult identification of metaphyseal-epiphyseal injuries, missed symmetrical fractures, inability to determine the age and type of fracture and relative insensitivity in detecting skull and vertebral body fractures. It should be used as a problem-solving study rather than first line.
- 2.7 Role of MRI and US for evaluating skeletal injury in NAI has not been established with reference to prevailing international guidelines and recommendations.

3 Skull trauma

- 3.1 Skull radiographs form part of the full skeletal survey for non-accidental injury.
- 3.2 In children with head trauma who are at increased risk of intracranial injury, CT is the preferred initial imaging modality and also improves definition of depressed and other complex fractures.
- 3.3 Bone scan is unreliable in identifying skull fractures.

4 Intracranial trauma

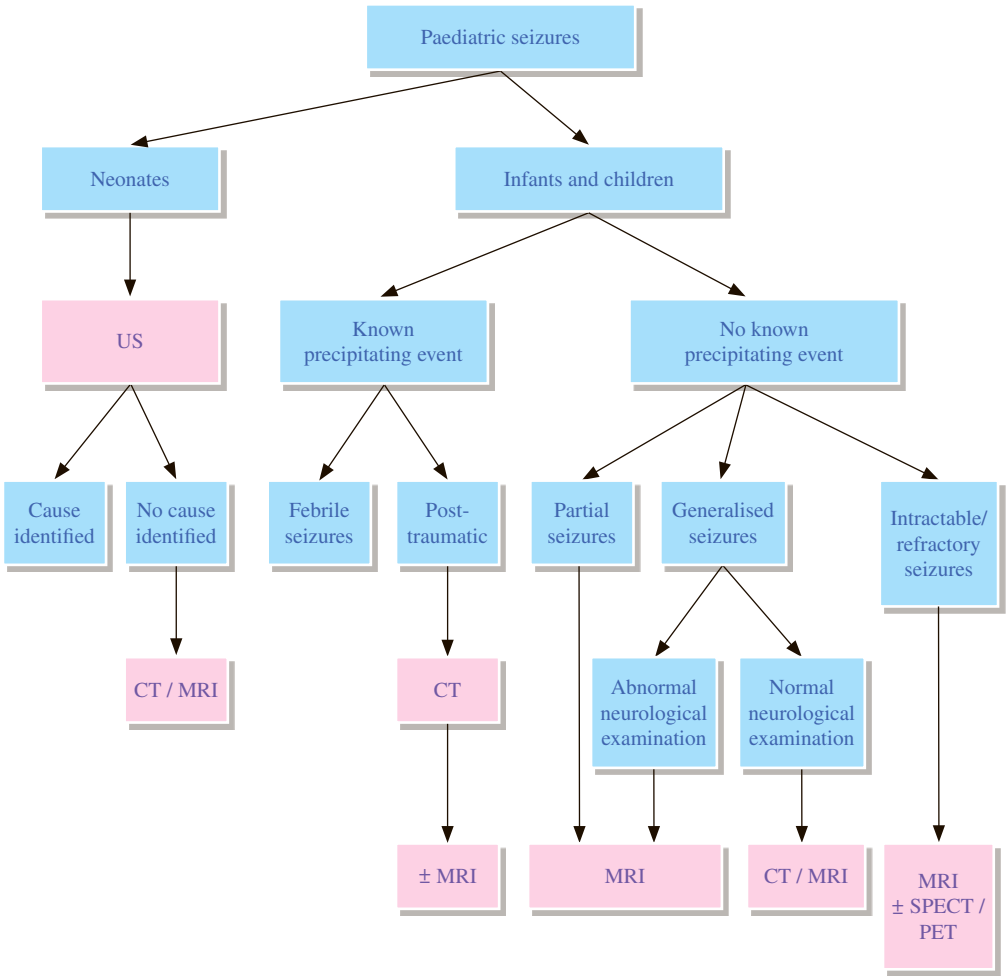
- 4.1 CT is both sensitive and specific in defining acute intra- and extra-cerebral injuries, especially subarachnoid haemorrhage.
- 4.2 MRI is useful in the subacute and chronic settings and is superior in detecting subdural haematomas, cortical contusions and shearing injuries. It can determine the age of extra-cerebral fluid collections and timing of intracranial haemorrhage.
- 4.3 MRI should be performed in patients whose clinical symptoms are disproportionate to the CT findings.

5 Visceral trauma

- 5.1 Imaging examinations should be tailored to specific clinical concern.
- 5.2 Abdominal US is useful to detect peritoneal fluid but is less sensitive than CT to detect solid organ injury.

REFERENCES

1. The Royal College of Radiologists, Royal College of Paediatrics and Child Health. Standards for Radiological Investigations of Suspected Non-Accidental Injury. London: The Royal College of Radiologists; 2008.
2. Wootton-Gorges SL, Soares BP, Alazraki AL. ACR Appropriateness Criteria® Suspected Physical Abuse – Child. Available at <https://acsearch.acr.org/docs/69443/Narrative/>. American College of Radiology. Accessed 2017 May 17.
3. American College of Radiology. ACR–SPR Practice Parameter For The Performance And Interpretation of Skeletal Survey in Children. Revised 2016 (Resolution 10). Reston: American College of Radiology; 2016.
4. Caviness AC. Skull fractures in children. In: UpToDate, Post TW (Ed), UpToDate, Waltham, MA; 2014.
5. Merten DF, Radkowski MA, Leonidas JC. The abused child - a radiological reappraisal. *Radiology*. 1983; 146: 377-381.
6. Merten DF, Carpenter BLM. Radiologic imaging of inflicted injury in the child abuse syndrome. *Pediatr Clin North Am*. 1990; 37: 815-837.
7. Mandelstam SA, Cook D, Fitzgerald M, Ditchfield MR. Complementary use of radiological skeletal survey and bone scintigraphy in detection of bony injuries in suspected child abuse. *Arch Dis Child*. 2003; 88: 387-390.
8. Conway JJ, Collins M, Tanz RR, Radkowski MA, Anandappa E, Hernandez R, et al. The role of bone scintigraphy in detecting child abuse. *Semin Nucl Med*. 1993; 23: 321-333.
9. Sato Y, Yuh WTC, Smith WL, Alexander RC, Kao SCS, Ellerbroek CJ. Head injury in child abuse - evaluation with MR imaging. *Radiology*. 1989; 173: 653-657.
10. Kleinman PK. Diagnostic imaging in infant abuse. *AJR Am J Roentgenol*. 1990; 155: 703-712.
11. Hardt N, Kuttenger J. Chapter 2: Radiology of Craniofacial fractures. *Craniofacial Trauma Diagnosis and Management*. Berlin Heidelberg: Springer-Verlag; 2010. p. 15-28.
12. Stauss J, Hahn K, Mann M, De Palma D. Guidelines for paediatric bone scanning with 99mTc-labelled radiopharmaceuticals and 18F-fluoride. *Eur J Nucl Med Mol Imaging*. 2010; 37: 1621-1628.
13. Conway JJ, Collins M, Tanz RR, Radkowski MA, Anandappa E, Hernandez R, Freeman EL. The Role of Bone Scintigraphy in Detecting Child Abuse. *Semin Nucl Med*. 1993; 23: 321-333.



REMARKS

1 Indications

- 1.1 Structural neuroimaging is recommended for all children with recently diagnosed localization-related or generalized epilepsy who do not have the clinical and electroencephalogram (EEG) features characteristic of classical idiopathic focal or generalized epilepsy (benign epilepsy with centrotemporal spikes (BECTS), childhood absence epilepsy (CAE), juvenile absence epilepsy (JAE), or juvenile myoclonic epilepsy (JME)) and for any child younger than 2 years of age.
- 1.2 Imaging early in the course of epilepsy is directed at identifying an etiology for seizure that requires other medical or surgical attention¹:
 - 1.2.1 If there is any evidence to suggest the epilepsy is localization-related (e.g. focal), with the exception of typical benign idiopathic partial epilepsy.
 - 1.2.2 Abnormal neurologic examination, including focal deficits, stigmata of neurocutaneous syndrome, cerebral malformation syndrome, or a history of significant developmental delay, arrest, or regression.
 - 1.2.3 Children younger than 2 years, excluding those with simple febrile seizures.
 - 1.2.4 Children with characteristics of a symptomatic generalized epilepsy syndrome, including infantile spasms or early Lennox-Gastaut syndrome.
 - 1.2.5 Failure to control seizures, worsening seizures, changes in seizure manifestations, or developmental regression also merit neuroimaging if not previously performed.
 - 1.2.6 New-onset seizure/epilepsy presenting with evidence for a medical emergency such as increased intracranial pressure or status epilepticus always merit emergency imaging.
- 1.3 Imaging studies in CAE, JAE, JME, and BECTS do not identify significant structural abnormalities¹.

2 Plain radiograph

- 2.1 Skull radiographs are not routinely indicated in evaluation of seizures in children as it lacks both sensitivity and specificity.²

3. US

- 3.1 US is effective in evaluation of seizures in neonatal period and may adequately define treatable pathology to allow management in some cases.
- 3.2 An open fontanelle is necessary for US.
- 3.3 US Doppler evaluation of intracranial arteries is effective in assessing regional cerebral blood flow but its clinical value remains unclear.

4. Nuclear medicine

- 4.1 Single photon emission computed tomography (SPECT).
 - 4.1.1 Ictal SPECT has been useful in differentiating temporal lobe epilepsy from extra-temporal lobe foci and provides non-invasive imaging information used in planning treatment strategies.³
 - 4.1.2 Ictal SPECT optimization requires radiopharmaceutical injection (Tc-99m hexamethylpropyleneamine oxime [HMPAO] or Tc-99m ethyl cysteinate dimer [ECD]) within seconds of a seizure.

4.2 PET

- 4.2.1 PET offers a direct quantitative correlation with metabolic activities and therefore it is potentially more specific than SPECT.
- 4.2.2 Both SPECT and Fluorodeoxyglucose (FDG) PET have been used as a part of pre-surgical evaluation and planning.

5. CT

- 5.1 Non-contrast CT is effective in identifying some treatable causes of seizures or emergencies causing seizures.
- 5.2 CT confers some advantages with regard to identifying blood and calcification (as found in congenital infection).¹
- 5.3 Contrast enhancement in general does not improve the sensitivity in detecting focal intracranial lesions with the exception of brain metastases, which are rare causes of seizures in the paediatric population.
- 5.4 CT is more widely available than MRI, less expensive, and less likely to require sedation for younger children.
- 5.5 CT can detect all treatable lesions in the setting of acute mild trauma.³

6. MRI

- 6.1 MRI has the highest sensitivity in detecting focal intracranial lesions. It is considered the imaging modality of choice because of superior anatomic resolution and characterization of pathologic processes.¹
- 6.2 Routine administration of gadolinium contrast provides little advantage in children with epilepsy. Administration of gadolinium is of limited value in increasing the sensitivity of MRI examination of brain, although the specificity can be improved.⁴ It is reserved for circumstances where tumor, vascular malformations, inflammation, and infectious concerns arise or are suspected based on review of non-contrast studies.
- 6.3 There is no agreement on specific imaging protocols or MRI sequences, but there is general agreement that the following should be performed¹:
 - 6.3.1 Anatomic, thin-slice volumetric T1-weighted gradient-recalled-echo sequence,
 - 6.3.2 Axial and coronal T2-weighted sequence,
 - 6.3.3 Fluid attenuated inversion recovery (FLAIR) sequence (axial, and coronal if possible),
 - 6.3.4 High resolution oblique coronal T2-weighted imaging of the hippocampus (fast or turbo spin echo weighted sequence),
 - 6.3.5 There is debate, and there are limited data, about the utility of newer sequences such as magnetization transfer imaging and diffusion tensor imaging,
 - 6.3.6 When metabolic disorders are suspected, magnetic resonance spectroscopy (MRS) may be helpful,
 - 6.3.7 Functional MRI has been used as a part of pre-surgical evaluation and planning.

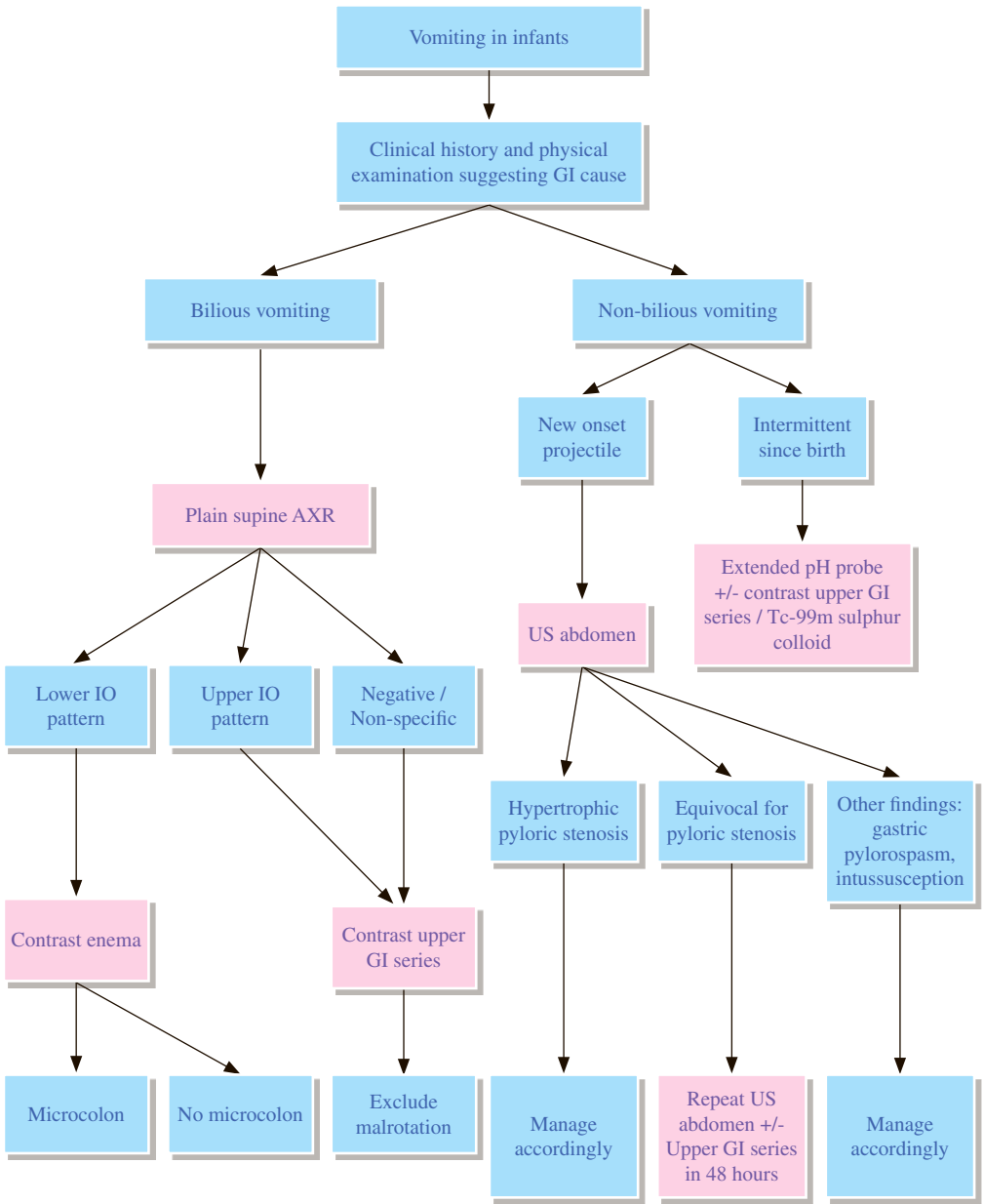
- 6.4 Children younger than 2 years require special sequences, as immature myelination affects the ability to identify common causes of epilepsy¹:
- 6.4.1 In addition to a 3D dataset, imaging in children younger than 2 years should include sagittal, axial, and coronal T1-weighted sequences.
 - 6.4.2 Volumetric T1-weighted sequences are less useful before one year of age due to incomplete myelination on T1 sequences.
 - 6.4.3 MR imaging (especially high-resolution T2 images) performed early in the first year of life in infants with epilepsy is important to identify areas of cortical or subcortical dysplasia, which can become difficult to identify after myelination.
 - 6.4.4 If MR imaging before the age of 2 years is normal, and seizures persist, then MRI may be repeated at 6-month intervals, and after age 24–30 months when more mature myelination can reveal otherwise unsuspected cortical dysplasia.

7. Angiography

- 7.1 Angiography should only be performed with prior imaging suggesting a vascular lesion.

REFERENCES

1. Gaillard WD, Chiron C, Cross JH, Harvey AS, Kuzniecky R, Hertz-Pannier, Vezina LG; ILAE, Committee for Neuroimaging, Subcommittee for Pediatric Neuroimaging. Guidelines for imaging infants and children with recent-onset epilepsy. *Epilepsia*. 2009; 50: 2147–2153.
2. The Royal College of Radiologists. iRefer: Making the best use of clinical radiology. 8th ed. London: The Royal College of Radiologists; 2017. Section P10.
3. Dory CE, Coley BD, Karmazyn B, et al. ACR Appropriateness Criteria® Seizures - Child. Available at <https://acsearch.acr.org/docs/69441/Narrative/>. American College of Radiology. Accessed 2017 Jun 2.
4. Lee ST, Lui TN. Early seizures after mild closed head injury. *J Neurosurg* 1992; 76: 435-439.



REMARKS

1 Malrotation / midgut volvulus

- 1.1 Midgut volvulus is an emergency situation. It should be considered in patients with bilious vomiting.
- 1.2 Contrast upper GI series is the preferred examination. Barium is usually used, except in suspected perforation or high risk of aspiration. Low-osmolarity contrast media are used in extremely ill or premature neonates.
- 1.3 US is limited by operator experience and incomplete examination due to overlying gas.

2 Gastroesophageal reflux (GER)

- 2.1 Extended pH probe is currently the gold standard for diagnosis. Preference for the other methods in the diagnostic work-up of GER varies among different centres depending on expertise and availability.
- 2.2 GER is the commonest cause of recurrent non-bilious vomiting. Abdominal X-ray (AXR) does not have a role in diagnosis of GER, and is indicated for additional clinical conditions, e.g. obstruction.
- 2.3 Contrast upper GI series or nuclear medicine examination are advocated only when failure of conservative treatment, development of complications or life threatening symptoms occur.
- 2.4 Upper GI series and nuclear medicine examination (Tc-99m-labelled sulphur colloid scan) show similar sensitivity, and upper GI series allows anatomical evaluation e.g. obstruction and structural abnormalities.
- 2.5 US can provide functional and morphologic information. However, its diagnostic performance on GER is variable.

3 Hypertrophic pyloric stenosis

- 3.1 AXR should not be routinely obtained when the diagnosis is strongly suspected.
- 3.2 US is the preferred method for diagnosis but it requires considerable experience. Repeat US in 48 hours is recommended in case of doubt. Contrast upper GI series is limited by its ionizing radiation, and should be used when other causes are suspected.

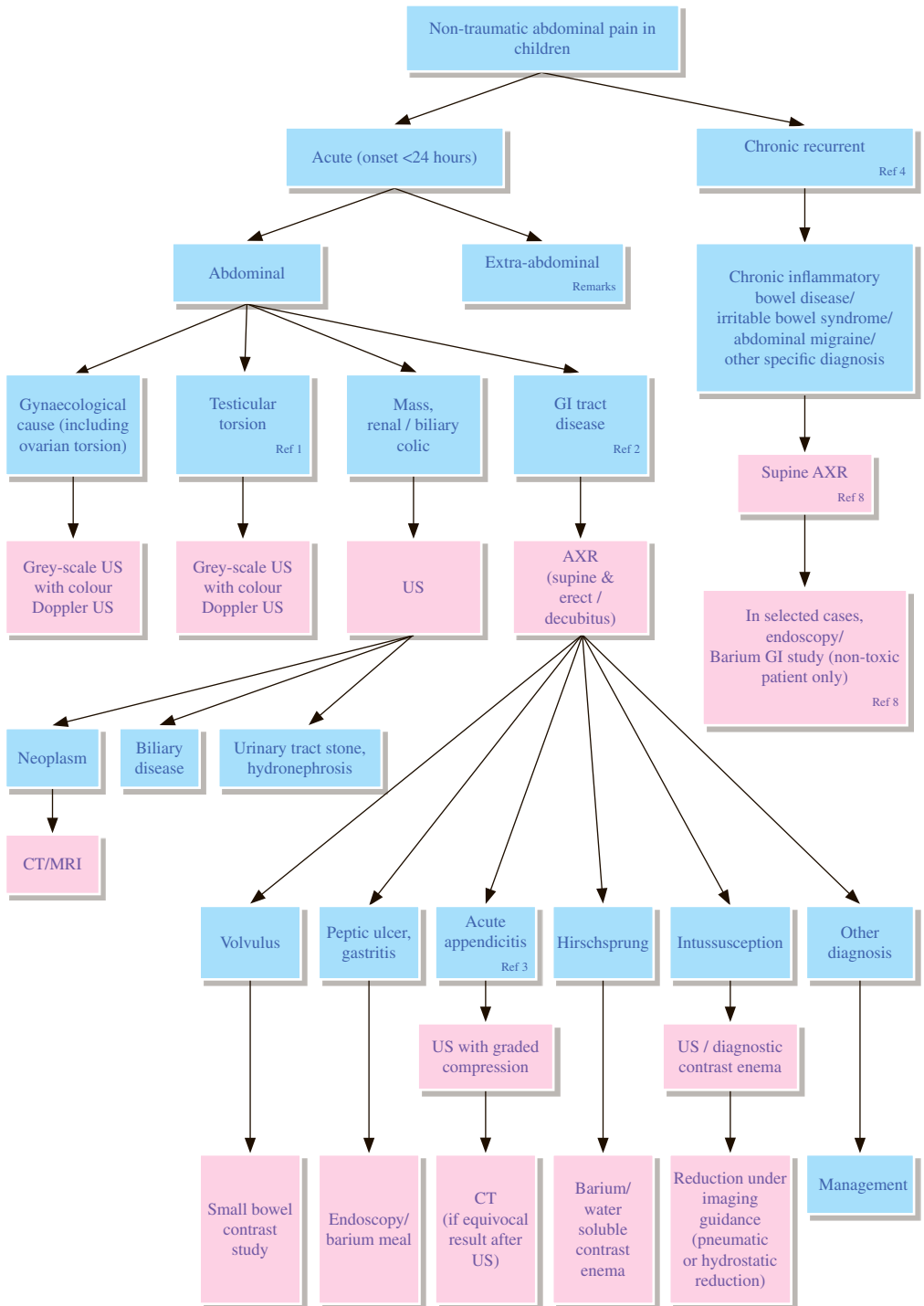
4 Intussusception

- 4.1 Intussusception is a frequent cause of crampy abdominal pain, which can be accompanied by vomiting in children.
- 4.2 The main reason for obtaining plain radiographs is to look for the presence of free intraperitoneal air and degree of small bowel obstruction. US is a sensitive diagnostic method.
- 4.3 Pneumatic reduction under fluoroscopic guidance is used to reduce intussusception, only where specialist equipment and expertise is available.

REFERENCES

1. American College of Radiology. ACR Appropriate Criteria – Vomiting in Infants up to 3 Months of Age. Reston: American College of Radiology, 2014
2. The Royal College of Radiologists. iRefer: Making the best use of clinical radiology. 8th ed. London: The Royal College of Radiologists; 2017. Section P24.
3. The Royal College of Radiologists. iRefer: Making the best use of clinical radiology. 8th ed. London: The Royal College of Radiologists; 2017. Section P25.
4. The Royal College of Radiologists. iRefer: Making the best use of clinical radiology. 8th ed. London: The Royal College of Radiologists; 2017. Section P21.
5. Vandenplas Y, Rudolph CD, Di Lorenzo C, Hassall E, Liptak G, Mazur L, et al. Pediatric Gastroesophageal Reflux Clinical Practice Guidelines: Joint Recommendations of the North American Society for Pediatric Gastroenterology, Hepatology, and Nutrition (NASPGHAN) and the European Society for Pediatric Gastroenterology, Hepatology, and Nutrition (ESPGHAN). *J Pediatr Gastroenterol Nutr.* 2009; 49: 498-547.
6. Vinocur DN, Lee EY, Eisenberg RL. Neonatal Intestinal Obstruction. *AJR Am J Roentgenol.* 2012; 198: W1-10.
7. Cohen HL, Greene EB, Boulden TP. The Vomiting Neonate or Young Infant. *Ultrasound Clin.* 2010; 5: 97-112.

PD 4 Non-traumatic abdominal pain



REMARKS

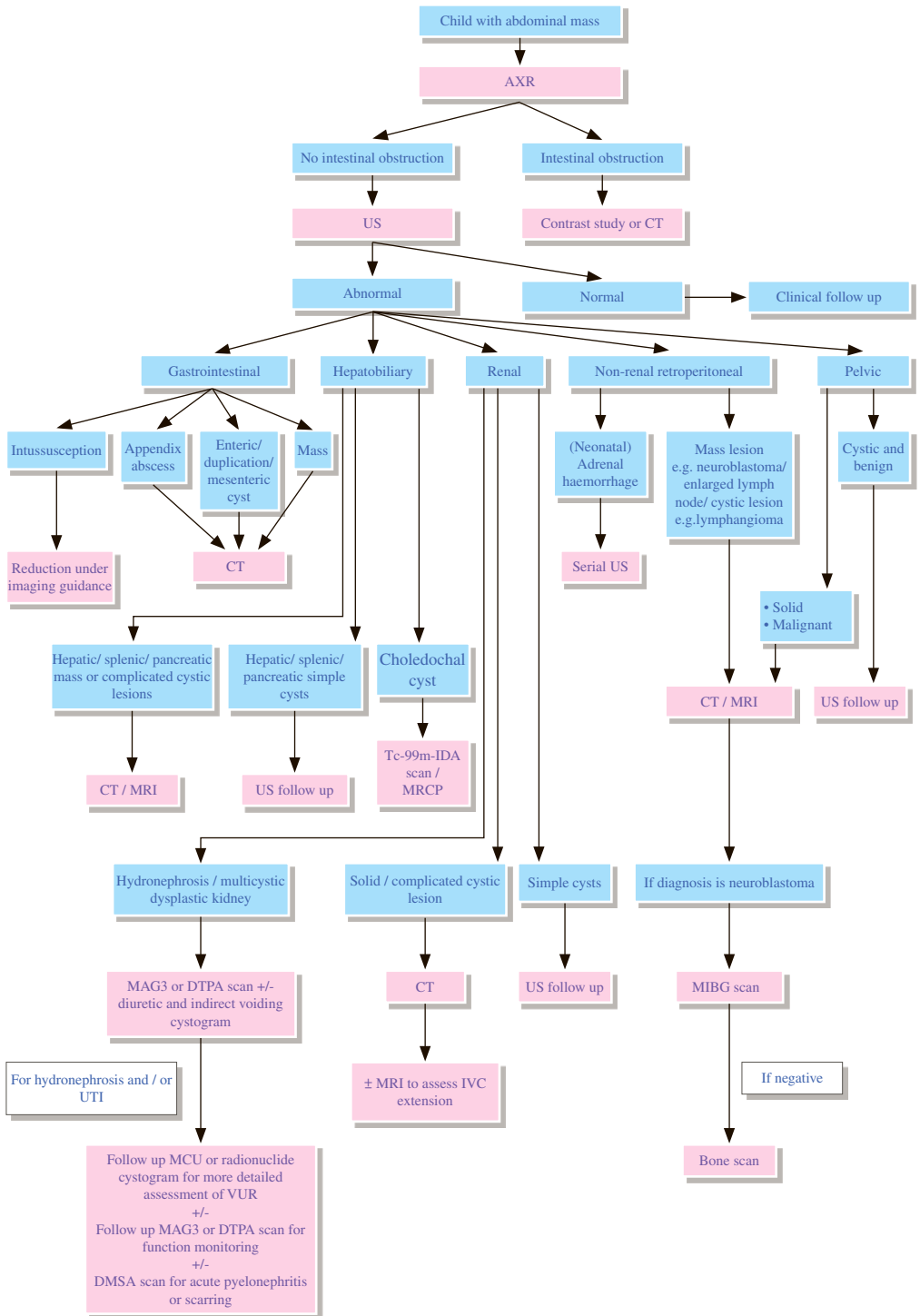
- 1 In all children presented with abdominal pain, history and physical examination should be carefully assessed for evidence of significant trauma (both accidental and non-accidental).
- 2 In significant abdominal trauma, further investigations with radiograph, US and sometimes CT are necessary to exclude pneumothorax, perforation of hollow viscus or contusion / laceration of solid organs.
- 3 In pre-school children, abdominal pain is rarely of psychogenic origin and an organic source should be carefully sought.⁷
- 4 A period of observation is important in those with non-specific symptoms and absent physical signs. Subsequent change in symptoms or development of specific signs may point to the diagnosis.
- 5 **Gynaecological causes**
 - 5.1 Recurrent pain related to menstruation can be due to endometriosis, while chronic pain and vaginal discharge are suggestive of chronic pelvic inflammatory disease. For acute onset of abdominal pain in sexually active females, the possibility of ectopic pregnancy or other pregnancy-related complications as well as acute pelvic inflammation should be considered. All these conditions warrant further investigation by US.^{5,6}
 - 5.2 Gastroenteritis and constipation are clinical diagnoses. Radiographs are usually unnecessary.⁵
 - 5.3 For suspected non-accidental injury, please refer to the guideline PD1.
- 6 **Extra-abdominal causes**
 - 6.1 Diabetic ketoacidosis, porphyria, lead poisoning, in which biochemical tests are needed for diagnosis.
 - 6.2 Pneumonia, bronchiolitis, asthma, in which chest X-ray (CXR) will be useful for diagnosis.⁵
- 7 **Acute appendicitis**³
 - 7.1 Meta-analysis showed US is nearly as good as CT in experienced hands, with a pooled sensitivity of 88% and specificity of 94%, as compared with CT, with a pooled sensitivity of 94% and specificity of 95%. Given the lack of ionizing radiation, US is the preferred examination in children, particularly if equivocal results are followed up by CT.
 - 7.2 CT-after-US approach has excellent accuracy, with reported sensitivity and specificity of 94%.
 - 7.3 If CT is performed, use of intravenous (IV) contrast is recommended; however, the use of enteric contrast, such as oral or rectal contrast, has not been shown to significantly increase sensitivity in children and should be left to the discretion of individual department and hospital policy.
 - 7.4 Non-visualization of the appendix on normal CT has been shown to have a high negative predictive value of 98.7%.⁹

8 Hirschsprung Disease²

- 8.1 Barium or water-soluble contrasts are the routine contrast media used for evaluating childhood Hirschsprung disease.
- 8.2 In the neonate or infant, water-soluble media diluted to near-isotonic or iso-osmolar concentration is preferred, as there may be potential for bowel perforation.

REFERENCES

1. Hartman MS, Leyendecker JR, Friedman B, et al. ACR Appropriateness Criteria@Acute Onset of Scrotal Pain – Without Trauma, Without Antecedent Mass. Available at <https://acsearch.acr.org/docs/69363/Narrative/>. American College of Radiology. Accessed 2017 April 10.
2. American College of Radiology. ACR–SPR practice parameter for the performance of pediatric fluoroscopic contrast enema examinations. Revised 2016 (Resolution 9). Reston: American College of Radiology; 2016.
3. Smith MP, Katz DS, Rosen MP, et al. ACR Appropriateness Criteria@Right Lower Quadrant Pain – Suspected Appendicitis. Available at <https://acsearch.acr.org/docs/69357/Narrative/>. American College of Radiology. Accessed 2017 April 10.
4. Ralph Pinnock. Abdominal Pain, Chronic. Raewyn Gavin, editor. Starship Children’s Health Clinical Guideline; 2012 April.
5. Grisanti KA. Gastrointestinal disorders: abdominal pain. In: Barkin RM, Asch SM, Caputo GL, Jaffe DM, Knapp J, Schafermeyer RW, Seidel JS, editors. Paediatric emergency medicine - concepts and clinical practice. St.Louis: Mosby; 1992. p. 726-795.
6. Ruddy RM. Abdominal pain. In: Fleisher GR, Ludwig S, editors. Textbook of pediatric emergency medicine. 2nd edition. Baltimore: Williams & Wilkins; 1988. p. 70-77.
7. First LR, Snyder J. Gastroenterology - approach to abdominal pain. In: Avery ME, First LW, editors. Paediatric medicine. Baltimore: Williams & Wilkins; 1989. p. 401-413.
8. de Bruyn R, Milla P. Gastrointestinal tract. In: Gordon I, editor. Diagnostic imaging in paediatrics. London: Chapman & Hall; 1987. p. 217-244.
9. Garcia K, Hernanz-Schulman M, Bennett DL, Morrow SE, Yu C, Kan JH. Suspected appendicitis in children: diagnostic importance of normal abdominopelvic CT findings with nonvisualized appendix. Radiology. 2009; 250: 531-537.



REMARKS

1 Plain radiograph

- 1.1 Plain abdominal X-ray (AXR) is useful to exclude intestinal obstruction in children with constipation or abdominal distension, to locate mass, to detect any calcification, and to look for any skeletal involvement.

2 US

- 2.1 US helps to determine the organ of origin, to define the mass, to look for any metastases and to assess the vascularity of the mass with colour Doppler. A likely diagnosis can usually be made.

3 Nuclear medicine

- 3.1 Technetium 99m - Mercaptoacetyltriglycine (Tc-99m-MAG3) is the preferred radiotracer for renal scan.¹
- 3.2 Tc-99m-MAG3 renography is able to provide information on renal position, perfusion, differential function and transit times. If hydronephrosis is seen, diuretics can be administered to evaluate functional significance of hydronephrosis.¹
- 3.3 Indirect radionuclide cystography can be performed in the same setting as renography, although its sensitivity is lower than direct radionuclide cystography (DRC),² therefore follow up DRC or micturating cystourethrography (MCU) is required for patients with hydronephrosis, whether or not vesicoureteric reflux (VUR) was detected on indirect radionuclide cystography.
- 3.4 Nuclear medicine cystography carries a lower radiation dose than MCU.³
- 3.5 Metaiodobenzylguanidine (MIBG) scan is used in diagnosis, staging and follow up of neuroblastoma.
- 3.6 MIBG has higher sensitivity than bone scan for skeletal metastases. However, bone scan is needed for patient whose tumour is MIBG negative.⁴
- 3.7 Dynamic Tc-99m - iminodiacetic acid (IDA) scan may be used to diagnose choledochal cyst.

4 CT

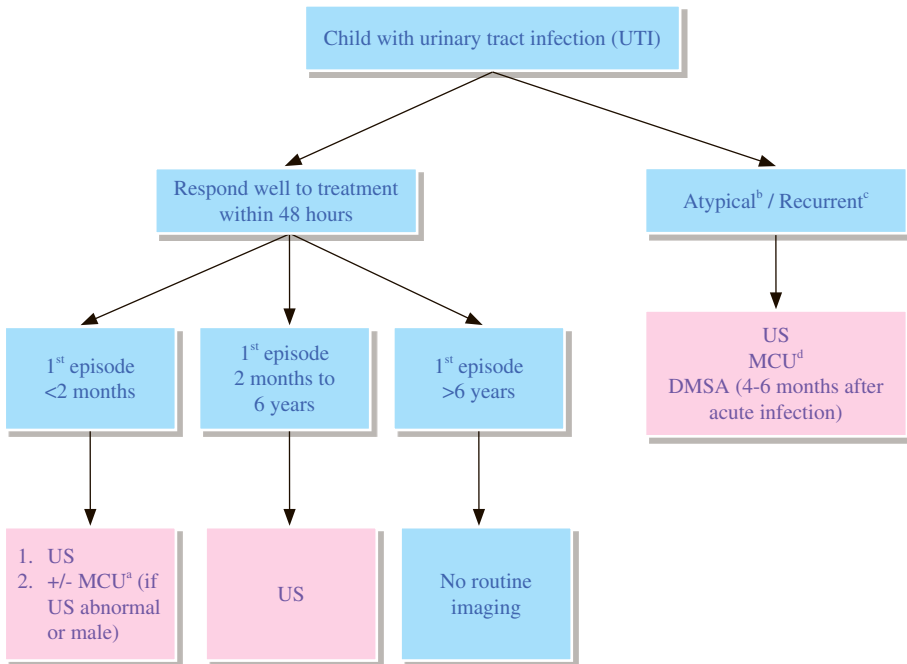
- 4.1 CT is used for anatomical and morphological characterization of mass and in assessing the involvement of adjacent structures and distant metastases.
- 4.2 Sedation is often required to reduce movement artefacts.

5 MRI

- 5.1 MRI provides excellent contrast resolution of soft tissues and is the best study to exclude intradural extension of mass. Status of vasculature can also be evaluated.
- 5.2 MRI is nonionizing but expensive. Sedation of the children is required.
- 5.3 Magnetic resonance cholangiopancreatography (MRCP) is a non-invasive biliary study.

REFERENCES

1. Shulkin BL, Mandell GA, Cooper JA, Leonard JC, Majd M, Parisi MT, et al. Procedure Guideline for Diuretic Renography in Children. *Journal of Nuclear Medicine Technology*. 2008; 36: 162-168.
2. Lim R. Vesicoureteral Reflux and Urinary Tract Infection: Evolving Practices and Current Controversies in Pediatric Imaging. *AJR Am J Roentgenol*. 2009; 192: 1197-1208.
3. The Royal College of Radiologists. iRefer: Making the best use of clinical radiology. 7th ed. London: The Royal College of Radiologists; 2012. Section P21-P30.
4. Matthey KK, Shulkin B, Ladenstine R, Michon J, Giammarile F, Lewington V, et al. Criteria for evaluation of disease extent by 123I-metaiodobenzylguanidine scans in neuroblastoma: a report for the International Neuroblastoma Risk Group (INRG) Task Force. *Br J Cancer*. 2010; 102: 1319-1326.
5. Stein R, Doğan HS, Hoebcke P, KocVara R, Nijman RJ, Radmayr C, et al. Urinary tract infections in children: EAU/ESPU guidelines. *Eur Urol*. 2015; 67: 546-558.
6. Gordon I, Piepsz A, Rune S. Guidelines for standard and diuretic renogram in children. *Eur J Nucl Med Moll Imaging*. 2011; 38: 1175-1188.



- a. Radionuclide cystography or contrast-enhanced voiding urosonography may be alternative to MCU in initial assessment of girls or follow up studies (see Remarks)
- b. Definition of atypical UTI: poor response to antibiotics within 48 hours, poor urine stream, sepsis, raised creatinine, non E-coli UTI
- c. Definition of recurrent UTI: two or more acute pyelonephritis / upper urinary tract infection, OR one acute pyelonephritis / upper urinary tract infection plus one or more cystitis / lower urinary tract infection, OR three or more cystitis / lower urinary tract infection
- d. In atypical / recurrent UTI, NICE guideline 2016 reserves MCU in child < 6months or child between 6 months to 3 years with the following:
 - Dilatation on US
 - Poor urine flow
 - Non E-coli infection
 - Family history of VUR

REMARKS

Imaging protocol of febrile urinary tract infection (UTI) in children

UTI is a frequent indication for imaging evaluation of paediatric urinary tract. The goal of all imaging has been to improve outcome and prevent end-stage renal failure due to scarring from late diagnosis and inadequate treatment.¹

Imaging approach of UTI in children younger than 2 months may need to be more aggressive, as there is limited research on this age group and neonates with UTI have a high incidence of renal anomalies and are more likely to be complicated with sepsis.²

US of kidneys and bladder is usually appropriate² and it is recommended in National Institute for Health and Care Excellence (NICE) guideline.³ Micturating cystourethrography (MCU) may be appropriate and can be considered in boys and in presence of sonographic abnormality. Radionuclide cystography may be appropriate and can be considered in girls.² Contrast-enhanced Voiding Urosonography (ceVUS) is a valid and radiation-free alternative examination for MCU and radionuclide cystography.^{1,4}

American Academy of Pediatrics (AAP) 2011 guidelines recommends US for all children between ages of 2 months and 2 years after first episode of UTI.^{3,5} AAP 2011 recommends that MCU is indicated if US reveals hydronephrosis, scarring or other findings that would suggest high grade vesicoureteric reflux (VUR) or obstructive uropathy or in other atypical and complex clinical circumstances. It should also be performed for recurrent UTI.⁵ NICE 2007 recommends that MCU should be considered if several clinical and imaging features are present. Guideline from Italian group recommends MCU for patients with abnormal US findings, risk factors or recurrent UTI.⁶

Risk factors are derived from NICE 2016, American College of Radiology (ACR) Appropriateness Guideline and Italian Guideline^{2,3,6}:

- First degree relative with VUR
- Septicemia
- Urinary retention
- Poor urine stream
- Raised creatinine
- No or poor response to antibiotics treatment within 48 hours
- Bacteria other than E. Coli

NICE 2016 defined Recurrent UTI as follows:³

- 2 or more episodes of UTI with acute pyelonephritis / upper urinary tract infection, or
- 1 episode of UTI with acute pyelonephritis / upper urinary tract infection plus one or more episode of UTI with cystitis / lower urinary tract infection, or
- 3 or more episodes of UTI with cystitis / lower urinary tract infection

Renal cortical scintigraphy (with dimercaptosuccinic acid [DMSA]) in six months is recommended in patient with high risk factors, recurrent UTI, abnormal US or VUR shown to evaluate for renal parenchymal defects and relative renal function.^{3,6}

1 MCU

The main role of MCU is to detect VUR. Patient with high grade VUR (grade 3-5) are more likely to have recurrent UTI and scarring.² It can also detect obstructive anomalies, such as posterior urethral valves or ectopic ureterocele.

2 US

US can detect urinary tract anomalies such as hydronephrosis, duplex renal system, hydroureter and ureterocele. Sensitivity of US for detecting VUR and renal scarring is low.²

3 Nuclear medicine

3.1 Renal cortical scintigraphy

Renal cortical scintigraphy with DMSA has greater sensitivity for detection of acute pyelonephritis and renal scarring than does either US or MCU. The findings on nuclear scans rarely affect acute clinical management. Hence, it is not recommended as part of routine evaluation of infants with their first febrile UTI.⁵ It is recommended 6 months after the febrile UTI to obtain a morphological and functional evaluation of the renal parenchyma.⁶

3.2 Radionuclide cystography (RNC)

Direct RNC is comparable in sensitivity to MCU in detecting VUR. RNC has a lower absorbed radiation dose than MCU but it does not have the spatial resolution needed to identify anatomical abnormalities of urethra, bladder and ureters. Initial evaluation of VUR in girls and follow-up studies may be done by RNC.²

4 Contrast-enhanced voiding urosonography (ceVUS)

ceVUS is an ultrasound-based reflux examination, involving intravesical instillation of ultrasound contrast and continuous alternative sonographic examination of the kidneys, bladder and urethra. It has been applied in Europe for two decades. The procedure is similar to MCU except the replacement with ultrasound contrast and sonographic examination.⁴ ceVUS has been considered as a safe, reliable, radiation-free and valid alternative to MCU or RNC, and has a higher reflux detection rate than MCU due to stability of ultrasound contrast microbubbles, advances in ultrasound technology, and longer examination time.^{1,7} The currently used stabilized ultrasound contrast agent has been approved in paediatric use by the U.S. Food and Drug Administration in 2016, though the intravesical application in ceVUS is still off-label.⁸

ceVUS can be considered as an alternative to MCU in the following conditions:

4.1 First examination for vesicoureteric reflux in girls

4.2 Follow up examination for vesicoureteric reflux in boys and girls after conservative or surgical treatment

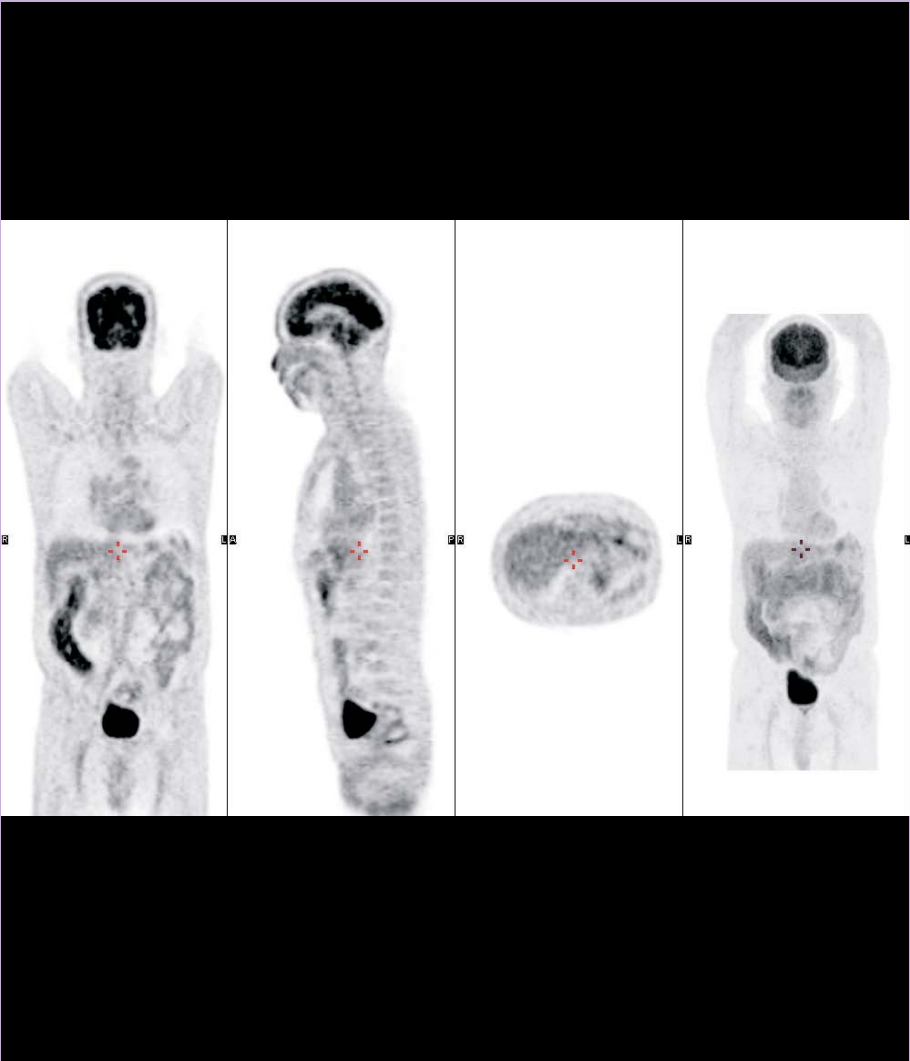
4.3 Screening high-risk patients for vesicoureteric reflux

Application of ceVUS in male urethral assessment is feasible and accurate,⁸⁻⁹ and expanded use of ceVUS in first examination in boys will be further validated.

REFERENCES

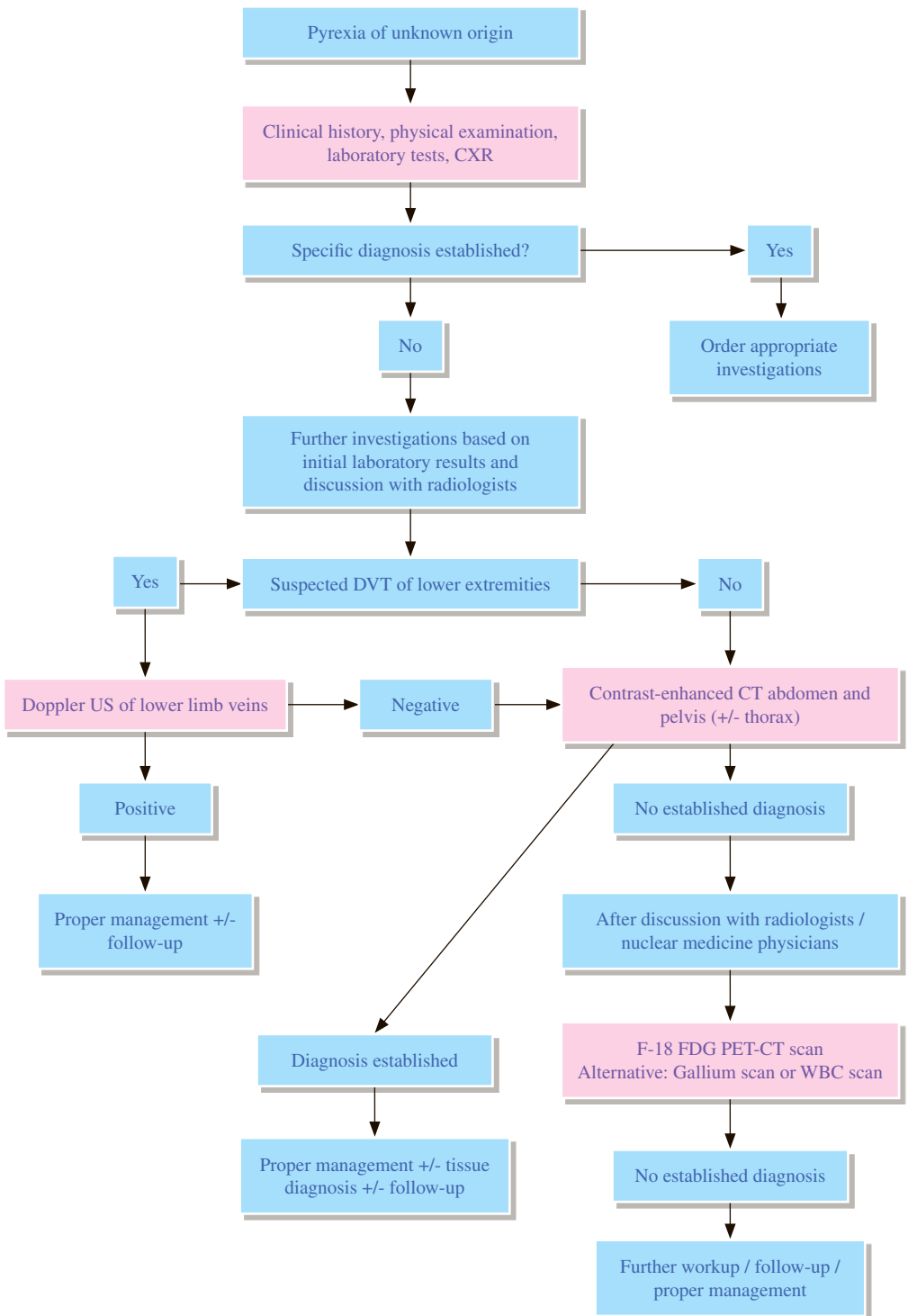
1. Riccabona M, Avni FE, Blickman JG, Dacher JN, Darge K, Lobo ML, et al. Imaging recommendations in paediatric uro-radiology: minutes of the ESPR workgroup session on urinary tract infection, fetal hydronephrosis, urinary tract ultrasonography and voiding cystourethrography, Barcelona, Spain, June 2007. *Pediatr Radiol.* 2008; 38:138-145.
2. Karmazyn BK, Alazraki AL, Anupindi SA, et al. ACR Appropriateness Criteria® Urinary Tract Infection – Child. Available at <https://acsearch.acr.org/docs/69444/Narrative/>. American College of Radiology. Accessed 2017 May 17.
3. National Institute for Health and Care Excellence (2016). Urinary tract infection in under 16s: diagnosis and management. NICE guideline (CG54).
4. Darge K. Voiding Urosonography with ultrasound contrast agents for the diagnosis of vesicoureteric reflux in children. I. Procedure. *Pediatr Radiol.* 2008; 38: 40-53.
5. Subcommittee on Urinary Tract Infection, Steering Committee on Quality Improvement and Management. Urinary Tract Infection: Clinical Practice Guideline for the Diagnosis and Management of the Initial UTI in Febrile Infants and Children 2 to 24 Months. *Pediatrics.* 2011; 128: 595-610.
6. Ammenti A, Cataldi L, Chemenz R, Fanos V, La Manna A, Marra G, et al. Febrile urinary tract infections in young children: recommendations for the diagnosis, treatment and follow-up. *Acta Paediatr.* 2012; 101: 451-457.
7. Piscaglia F, Nolsoe C, Dietrich CF, Cosgrove DO, Gilja OH, Bachmann Nielsen M, et al. The EFSUMB guidelines and recommendations on the clinical practice of contrast enhanced ultrasound (CEUS): Update 2011 on non-hepatic applications. *Ultraschall Med.* 2012; 33: 33-59.
8. Seitz K, Strobel D. A milestone: Approval of CEUS for diagnostic liver imaging in adults and children in the USA. *Ultraschall Med.* 2016; 37: 229-232.
9. Duran C, Valera A, Alquersuari A, Ballesteros E, Riera L, Martin C, et al. Voiding Urosonography: The study of the urethra is no longer a limitation of the technique. *Pediatr Radiol.* 2009; 39: 124-131.

Miscellaneous



Hong Kong College of Radiologists

MC 1 Pyrexia of unknown origin



REMARKS

1 General

- 1.1 Definition of pyrexia of unknown origin¹
 - 1.1.1 Pyrexia of unknown origin was first defined as an illness of greater than 3 weeks' duration with a temperature higher than 101°F (38.3°C) on several occasions and an uncertain diagnosis after 1 week of study in the hospital.
 - 1.1.2 The requirement of 1 week in-patient evaluation has been recently modified and only evaluation of 3 out-patient visits or 3 days of in-hospital evaluation are stated in some articles.²⁻⁴
- 1.2 Classifications based on patient's subtypes include: classic, nosocomial, immune deficient and human immunodeficiency virus (HIV) associated, which may require different investigations pathway.^{2,3}
 - 1.2.1 The classic pyrexia of unknown origin excludes patients with known immunodeficiency or HIV infection.²
- 1.3 Causes of pyrexia of unknown origin³⁻⁵
 - 1.3.1 Infectious, oncologic, inflammatory and miscellaneous/unknown are the four main categories.
 - 1.3.2 There is an increasing trend of pyrexia of unknown origin in which the cause remains unknown.^{4,6,7}
 - 1.3.3 Infection is the most common cause. However, many factors may affect the implementation of study results to clinical practice due to different geographic locations, different subgroups of patients and different types of institutions.³

2 Radiography

- 2.1 Some articles have listed out the minimum diagnostic evaluation to qualify as pyrexia of unknown origin. Chest X-ray (CXR) is among one of the first investigations.^{6,8}
- 3 The decision to obtain any further diagnostic studies should be based on abnormalities found in the initial laboratory work-up.³ Further diagnostic studies should be performed after discussion with radiologists/nuclear medicine physicians.

4 CT

- 4.1 For further diagnostic workup, CT of the abdomen should be one of the first investigations since it has a high diagnostic yield, with reported yield rate being 19%.^{6,9}
- 4.2 No definite evidence to support CT thorax for evaluation of pyrexia of unknown origin. Consideration of the investigation should be based on patient's clinical history, physical examination, laboratory test and initial chest radiographic findings.

5 Nuclear Medicine

- 5.1 Gallium scan and white blood cell (WBC) scan
 - 5.1.1 Conventional scintigraphic methods are Ga-67 citrate scintigraphy, In-111 labeled or Tc-99m labeled WBC scintigraphy. These techniques have their disadvantages and limitations, such as handling of potentially infected blood products (labeled WBC scintigraphy), and the relatively long time span between injection and diagnosis.¹⁴

5.2 F-18 FDG PET-CT

- 5.2.1 Compared with conventional scintigraphy, advantages of FDG PET-CT include higher resolution, higher sensitivity in chronic low-grade infections, higher accuracy in the central skeleton, as well as shorter time period between injection of the radiopharmaceutical and the imaging procedure. Furthermore, FDG shows an increased vascular uptake in patients with vasculitis.¹⁴
- 5.2.2 Beside, FDG is accumulated in various types of malignancy, which can be a cause of pyrexia of unknown origin.

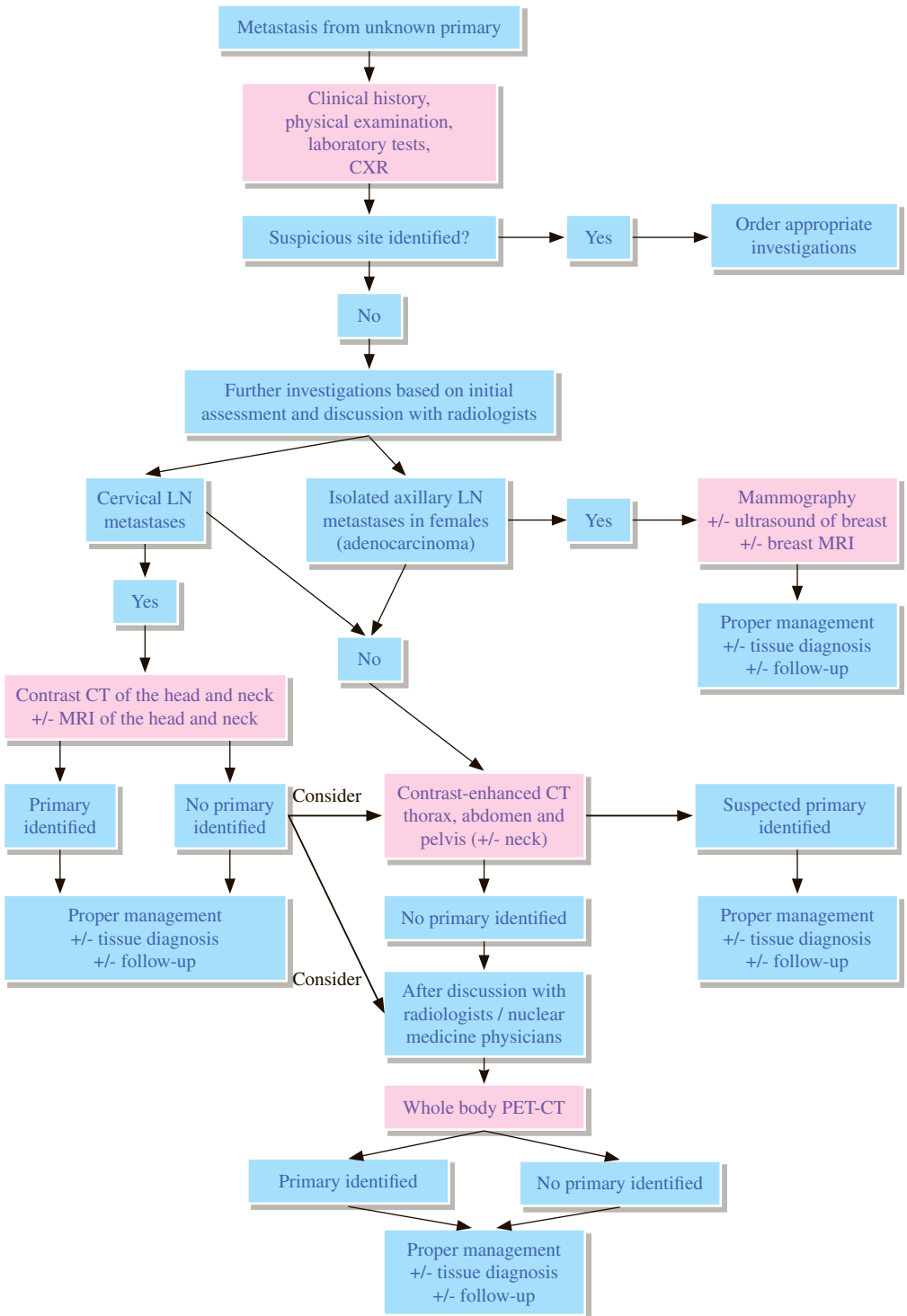
6 US

- 6.1 Venous thrombosis is a cause of prolonged fever. Studies revealed that it is a cause of pyrexia of unknown origin in 2-6%.^{6,13} Although deep vein thrombosis (DVT) accounts for a small percentage of pyrexia of unknown origin, Doppler US is a safe method to identify the treatable cause.⁶

REFERENCES

1. Petersdorf RG, Beeson PB. Fever of unexplained origin: report on 100 cases. *Medicine*. 1961; 40: 1-30.
2. Durack DT, Street AC. Fever of unknown origin—reexamined and redefined. *Curr Clin Top Infect Dis*. 1991; 11: 35-51.
3. Roth AR, Basello GM. Approach to the adult patient with fever of unknown origin. *Am Fam Physician*. 2003; 68: 2223-2228.
4. Naito T, Mizooka M, Mitsumoto F, Kanazawa K, Torikai K, Ohno S, et al. Diagnostic workup for fever of unknown origin: a multicenter collaborative retrospective study. *BMJ Open*. 2013; 3(12): e003971.
5. Qiu L, Chen Y. The role of 18F-FDG PET or PET/CT in the detection of fever of unknown origin. *Eur J Radiol*. 2012; 81: 3524-3529.
6. Mourad O, Palda V, Detsky AS. A comprehensive evidence-based approach to fever of unknown origin. *Arch Intern Med*. 2003; 163: 545-551.
7. Horowitz HW. Fever of unknown origin or fever of too many origins? *N Eng J Med*. 2013; 368: 197-199.
8. Arnow PM, Flaherty JP. Fever of unknown origin. *Lancet*. 1997; 350: 575-580.
9. Quinn MJ, Sheedy PF, Stephens DH, Haltery RR. Computed tomography of the abdomen in evaluation of patients with fever of unknown origin. *Radiology*. 1980; 136: 407-411.
10. Dong MJ, Zhao K, Liu ZF, Wan GL, Yang SY, Zhou GJ. A meta-analysis of the value of fluoro-deoxyglucose-PET/CT in the evaluation of fever of unknown origin. *Eur J Radiol*. 2011; 80: 834-844.
11. Kouijzer IJE, Bleeker-Rovers CP, Oyen WJG. FDG-PET in fever of unknown origin. *Semin Nucl Med*. 2013; 43: 333-339.
12. Bleeker-Rovers CP, van der Meer JWM, Oyen WJG. Fever of unknown origin. *Semin Nucl Med*. 2009; 39: 81-87.
13. AbuRahma AF, Saiedy S, Robinson PA, Boland JP, Cottrell DJ, Stuart C. Role of venous duplex imaging of the lower extremities in patients with fever of unknown origin. *Surgery*. 1997; 121: 366-371.
14. Kouijzer, IJ, Bleeker-Rovers CP, Oyen WJ. FDG-PET in fever of unknown origin. *Semin Nucl Med*. 2013; 43: 333-339.
15. Jamar F, Buscombe J, Chit A, Christian PE, Delbeke D, Donohoe KJ, et al. EANM/SNMMI guideline for 18F-FDG use in inflammation and infection. *J Nucl Med*. 2013; 54: 647-658.

MC 2 Metastases from unknown primary



REMARKS

1 General

- 1.1 ‘Cancer of unknown primary’ refers to a condition in which a patient has metastatic malignancy without an identified primary source, which is a very heterogeneous disease.¹
- 1.1.1 Different terms have been used to differentiate patients at different stages of investigative pathway¹
- 1.1.1.1 ‘Malignancy of undefined primary origin’—metastatic malignancy identified on the basis of a limited number of tests, without an obvious primary site, before comprehensive investigation
- 1.1.1.2 ‘Provisional carcinoma of unknown primary’—metastatic epithelial or neuroendocrine malignancy identified on the basis of histology/cytology, with no primary site detected despite a selected initial screen of investigations, before specialist review and possible further specialized investigations
- 1.1.1.3 ‘Confirmed carcinoma of unknown primary’—metastatic epithelial or neuroendocrine malignancy identified on the basis of final histology, with no primary site detected despite a selected initial screen of investigations, specialist review and further specialized investigations as appropriate
- 1.2 Incidence is about 3-5% of all cancers registered in the United Kingdom.^{1,2}
- 1.3 Chest X-ray (CXR) and CT scan of the chest, abdomen and pelvis are among the initial radiological investigations offered to patients with malignancy of undefined primary origin, depending on patient’s symptoms.^{1,3}

2 Radiography

- 2.1 Lung Cancer is the most common cause of metastasis from unknown primary.^{2,4} CXR is a cheap and very rapidly performed test to detect lung cancer.²

3 CT

- 3.1 CT of the thorax, abdomen and pelvis with the use of intravenous contrast material is a useful initial investigation.^{1,2,3,5,6}
- 3.2 The recommendation of CT thorax is also based on its better detection of lung cancer than CXR.^{5,7}
- 3.3 Contrast-enhanced CT of the head and neck is also useful for identification of primary tumour in patients with cervical lymph node metastases from unknown head and neck primary cancers.^{8,9,10}

4 Breast Imaging

- 4.1 Do not routinely offer mammography to women with metastasis from unknown primary unless clinical or pathological features are compatible with breast cancer.¹
- 4.2 Breast MRI should be considered in women presenting with isolated axillary adenopathy which is adenocarcinoma on histology and suspicious of breast primary, after negative initial mammography and ultrasonography.^{1,2,5}

5 MRI

5.1 MRI has superior soft tissue contrast for head and neck imaging.^{8,11}

6 PET scan

6.1 Whole-body Fluorodeoxyglucose (FDG) PET-CT may contribute to the management of patients with cervical adenopathies from occult primary and those with a single metastasis from occult primary. For other cases of metastases from occult primary, the role of FDG PET-CT is limited.¹³

6.2 FDG PET-CT is not recommended in routine systematic work-up for all cases of metastasis from occult primary.^{13,14}

6.3 FDG PET-CT may be warranted in cases considered for local or regional therapy.¹⁴

7 Image-guided biopsy

7.1 It is recommended that needle core biopsy or surgical biopsy should be obtained for histological assessment for evaluation of metastasis from unknown primary.^{1,2}

REFERENCES

1. National Institute for Health and Care Excellence (2010). Metastatic malignant disease of unknown primary origin in adults: diagnosis and management. NICE guideline (CG104).
2. Taylor MB, Bromham NR, Arnold SE. Carcinoma of unknown primary: key radiological issues from the recent National institute for health and clinical excellence guidelines. *BJR*. 2012; 85: 661-671.
3. Fizazi K, Greco FA, Pavlidis N, Pentheroudakis G; ESMO Guidelines working Group. Cancers of unknown primary site. ESMO Clinical Practice Guidelines for diagnosis, treatment and follow-up. *Ann Oncol*. 2011; 22 Suppl 6: vi64-vi68.
4. Moller AKH, Loft A, Berthelsen AK, Pedersen KD, Graff J, Christensen CB, et al. A prospective comparison of 18F-FDG PET/CT and CT as diagnostic tools to identify the primary tumor site in patients with extracervical carcinoma of unknown primary site. *The Oncologist*. 2012; 17: 1146-1154.
5. Varadhachary GR, Raber MN. Cancer of unknown primary site. *N Eng J Med*. 2014; 371: 757-765.
6. Losa Gaspa F, Germa JR, Albareda JM, Fernandex-Ortega A, Sanjose S, Fernandex TV. Metastatic cancer presentation. Validation of a diagnostic algorithm with 221 consecutive patients. [In Spain] *Rev Clin Esp*. 2002; 202: 313-319.
7. Latief KH, White CS, Protopapas Z, Attar S, Krasna MJ. Search for a primary lung neoplasm in patients with brain metastasis: is chest radiograph sufficient? *AJR Am J Roentgenol*. 1997; 168: 1339-1344.
8. Donta TS, Smoker WR. Head and Neck Cancer: Carcinoma of unknown primary. *Top Magn Reson Imaging*. 2007; 18: 281-292.
9. Cianchetti M, Mancuso AA, Amdur RJ, Werning JW, Kirwan J, Morris CG, et al. Diagnostic evaluation of squamous cell carcinoma metastatic to cervical lymph nodes from an unknown head and neck primary site. *Laryngoscope*. 2009; 119: 2348-2354.
10. Hermans R. Imaging in cervical nodal metastases of unknown primary. *Cancer Imaging*. 2011; 11: S9-S14.
11. Wippold II FJ. Head and Neck Imaging: the role of CT and MR. *JMIR*. 2007; 25: 453-465.
12. Wong WL, Sonoda LI, Gharpurhy A, Gollub F, Wellsted D, Goodchild K, et al. 18F-fluorodeoxyglucose positron emission tomography/computed tomography in the assessment of occult primary head and neck cancers—an audit and review of published studies. *Clin Oncology*. 2012; 24: 190-195.
13. Fizazi K, Greco FA, Pavlidis N, Daugaard G, Oien K, Pentheroudakis G. Cancers of unknown primary site: ESMO Clinical Practice Guidelines for diagnosis, treatment and follow-up. *Ann Oncol*. 2015; 26 Suppl 5: v133-v138.
14. National Comprehensive Cancer Network. NCCN Clinical Practice Guidelines in Oncology (NCCN Guidelines®) Occult Primary. Version 2.2016. Fort Washington, PA: National Comprehensive Cancer Network; 2016.

Acknowledgement



Hong Kong College of Radiologists

Contributors

Hong Kong College of Radiologists expresses gratitude to the following contributors for their hard work without which this project would not be possible:

Convenors:

Dr. LAM Hon Shing

Dr. WONG Yiu Chung

Dr. KWOK Kai Yan

Dr. CHEUNG Chi Wai Stephen

Dr. IP Jing Kun Janice

Dr. IU Po Ping

Dr. Kan Pan Shing

Dr. KAN Yee Ling Elaine

Dr. KAN Wai Kuen

Prof. Ann KING

Dr. KWOK King Ming

Dr. KWAN Chung Kong

Dr. LAM Poy Wing Tina

Dr. LAM Hiu Yin Sonia

Dr. LAI Andrew Siu Ho

Dr. LO Kit Lin Kitty

Dr. LO Sheung Ming Sherman

Dr. LUK Wing Hang

Dr. MA Ka Fai Johnny

Dr. NG Fung Him

Dr. PAN Nin Yuan

Dr. POON Wai Lun

Dr. TAM Kwok Fai Godfrey

Dr. TAN Chong Boon

Dr. TONG Mei Po Mabel

Dr. TSE Kin Sun

Dr. WONG Chun Wai

Dr. WONG Ka Tak

Dr. WONG Kwok Chun Christopher

Dr. WONG Wai Yin

Dr. YEUNG Tse Hang Jessie

Dr. YU San Ming

Acknowledgement

Hong Kong College of Radiologists acknowledges with gratitude all the College secretarial staff and the following individuals who had helped us in various ways in this project:

Dr. AU YONG Ting Kun
Dr. CHAN Tak Man
Dr. CHAN Tze Mun
Dr. CHOI Pak Tat Frankie
Dr. KUNG Boom Ting
Dr. LAI Kwok Chung
Dr. LAM Ka On
Dr. LAM Tai Chung
Dr. LAU Shun
Dr. LAW Chun Key
Dr. LEONG Fung Ling Yee Lilian
Mrs. Mabel LUI
Dr. LUK Yiu Shiobhon
Dr. Neeraj Ramesh MAHBOOBANI
Dr. SIM Shiu Wah
Dr. SIU Yung Woon
Dr. Francis TANG
Dr. TONG Cheuk Man
Dr. TUNG Yuk
Dr. WONG Sin Man
Dr. YUEN Kwok Keung
Dr. YUEN Ming Keung

Copyright © 2017 by the Hong Kong College of Radiologists.

All rights reserved. The material contained herein is protected by copyright. No part of this publication may be reproduced, stored in any information storage and retrieval system, or transmitted, in any form or by any means, electronic, mechanical, photocopying, recording, or otherwise, without prior written permission from the Hong Kong College of Radiologists.

