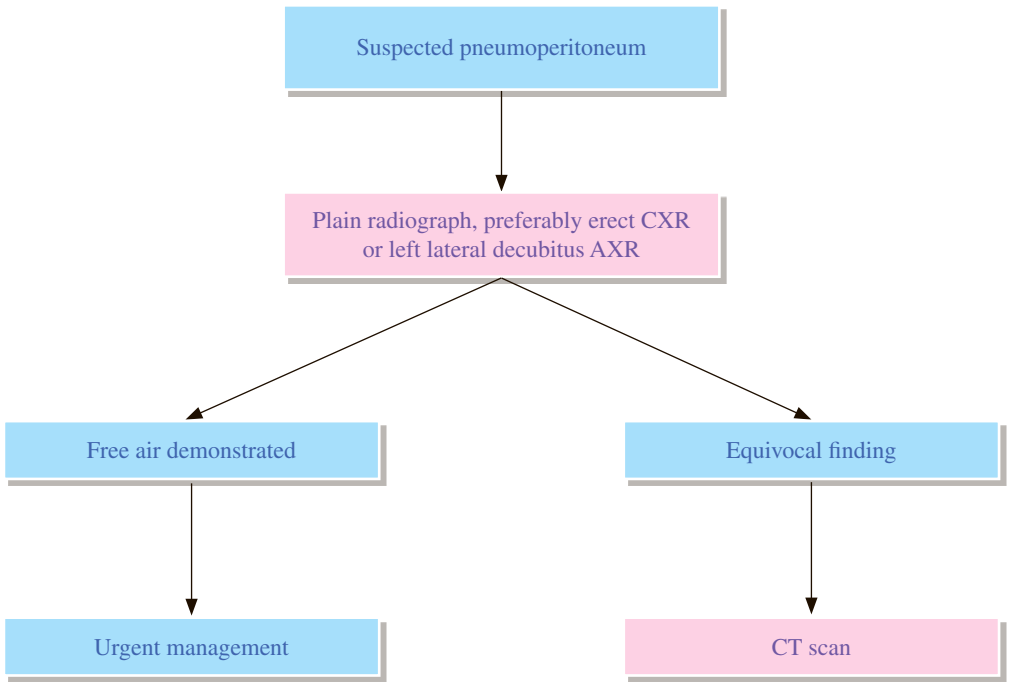


GI 3 Suspected pneumoperitoneum



REMARKS

1 Plain radiograph

- 1.1 Erect chest X-ray (CXR) is used to detect subphrenic gas.
- 1.2 Left lateral decubitus abdominal X-ray (AXR) also helps to demonstrate free air, especially in ill patients who cannot sit or stand.

2 CT

- 2.1 CT is useful for clarification of equivocal finding on plain radiograph.

REFERENCES

1. Stoker J, van Randen A, Lameris W, Boermeester MA. Imaging Patients with Acute Abdominal Pain. *Radiology*. 2009; 253: 31-46.
2. Chiu YH, Chen JD, Tiu CM, Chou YH, Yen DH, Huang CI, et al. Reappraisal of radiographic signs of pneumoperitoneum at emergency department. *Am J Emerg Med*. 2009; 27: 320-327.